

CASE REPORT

Axillary contralateral recurrence in breast cancer: case report and literature review

Recidiva axilar contralateral no câncer de mama: relato de caso e revisão da literatura

Cássio Furtini Haddad¹

Keywords

Breast neoplasms
Neoplasm recurrence, local
Lymphatic metastasis
Lymph node excision
Lymphatic diseases

Descritores

Neoplasias da mama
Recidiva local de neoplasia
Metástase linfática
Excisão de linfonodo
Doenças linfáticas

ABSTRACT

Axillary contralateral lymph nodes recurrence is uncommon after curative breast cancer treatment. When the contralateral axilla is involved in a woman with a breast cancer history, the diagnostic and correct approach are a dilemma. Although it is traditionally considered a distant event, many studies have shown that aberrant lymph drainage is common after previous breast surgery. This might indicate that axillary contralateral lymph nodes recurrence is a regional event. Therefore, its treatment should be with curative rather than palliative intent. The aim of this article was to report the case of a young woman with invasive carcinoma in the left breast and a posterior axillary contralateral recurrence, and to review the literature about this infrequent and controversial issue.

RESUMO

A recorrência em linfonodos axilares contralaterais é incomum após um tratamento curativo para o câncer de mama. Quando a axila contralateral está envolvida em uma mulher com história de câncer de mama, o diagnóstico e a abordagem adequada representam um dilema. Apesar de ser tradicionalmente considerada um evento à distância, muitos estudos têm mostrado que a drenagem linfática aberrante é comum após cirurgia mamária prévia. Isso pode indicar que a recorrência em linfonodos axilares contralaterais seja um evento regional. Portanto, o seu tratamento deveria ser com intenção curativa ao invés de paliativa. O objetivo deste artigo foi relatar o caso de uma paciente jovem com carcinoma invasivo em mama esquerda com posterior recidiva em axila contralateral, e revisar a literatura a respeito deste assunto infrequente e controverso.

Trabalho realizado no Serviço de Mastologia da Santa Casa de Misericórdia de Lavras – Lavras (MG), Brasil.

¹Santa Casa de Misericórdia de Lavras – Lavras (MG), Brasil.

Endereço para correspondência: Cássio Furtini Haddad – Rua Doutor João Silva Pena, 71 – Centro – CEP: 37200-000 – Lavras (MG), Brasil –

E-mail: cassiohaddad@hotmail.com

Conflito de interesses: nada a declarar.

Recebido em: 13/12/2015 – Aceito em: 06/01/2016

Introduction

Contralateral axillary lymph nodes recurrence (CAR) is uncommon after curative breast cancer (BC) treatment. It is commonly seen in the end stage of BC, when metastasis has already developed elsewhere. However, this is an infrequent event following an early BC treatment. The reported incidence is 1.9 to 5.0%^{1,2}. This presentation is more likely seen with locally advanced tumors involving the dermis, or in situations where traditional ipsilateral axillary drainage is affected by prior surgery.

The axilla contralateral involvement in a woman with current diagnosis or a history of having been treated for cancer in the opposite breast represents a diagnostic dilemma. Presentation of BC cell only in the contralateral regional lymph node following prior treatment of a unilateral BC is traditionally considered a result of systemic dissemination³. However, lymphoscintigraphy studies in patients who previously underwent surgery of the breast or axilla frequently show lymph drainage to contralateral nodal basins, such as contralateral axilla, internal mammary chain, or periclavicular sites⁴⁻⁷.

In cases of axillary contralateral involvement, three possible clinical scenarios should be considered. Firstly, it could be the manifestation of a systemic disease by hematogenous spread from the original breast tumor. Secondly, it could be regional metastasis from an occult new ipsilateral breast tumor. Thirdly, it could also represent regional metastases from the contralateral breast cancer through alternative lymphatic drainage. In every case, the management of such patient is perplexing since it is not clear whether they should be treated in a palliative or curative intent.

The prognostic impact and therapeutic consequences of CAR are not clear. The hypothesis of aberrant drainage patterns might indicate that a CAR after previous treatment for BC should be considered as a regional event, rather than systemic disease. If CAR prognosis is comparable to that of an ipsilateral lymph node recurrence, it would support treatment as a regional event, aiming for local control with curative rather than palliative intent⁸.

A CAR can occur isolatedly (i.e. without malignancy in either breast or other distant events), or synchronous to an ipsilateral breast tumor recurrence (IBTR) or distant event. In metastatic BC, prognosis is determined mainly by the distant event. In patients with a CAR without distant metastasis, prognosis and the influence of concurrent IBTR are unclear.

The present article aimed at reporting the case of a young patient with diagnostic of invasive breast carcinoma, who presented recurrence of contralateral axillary lymph nodes, and at conducting a brief literature review about this controversial issue.

Case report

A 37-year-old pre-menopausal patient, with two previous pregnancies, who reported breastfeeding for two years, without

comorbidities, with history of invasive ductal carcinoma in the left breast when she was 26 years old (T2N0M0), treated with quadrantectomy and lymph node axillary dissection followed by chemotherapy (six cycles of FAC), radiotherapy and tamoxifen during five years. Mastology and Oncology conducted monitoring since then. In July of 2015, the patient was submitted, in the routine appointment, to palpable right axillary lymph nodes, with no changes in the clinical examination of the breasts. Mammography showed focal distortion in the central region of left breast, architectural distortion on previous surgery local in the left upper lateral quadrant (ULQ), and right axillary lymphadenomegaly (BI-RADS 4). Mammary ultrasonography showed hypoechoic and irregular nodule, located at upper lateral quadrant, in the periareolar region, measuring 0.9x0.7x0.8 cm, and a heterogeneous image in the prior surgery topography in the ULQ of the left breast. Furthermore, two enlarged lymph nodes with echogenic central hilum loss in the right axilla (BI-RADS 4) were found (Figure 1). A core biopsy of the two left breast lesions was performed, with diagnostic of invasive breast carcinoma, grade 1 of modified Scarff-Bloom-Richardson (SBR), and positive immunohistochemistry for estrogen and progesterone receptors and positivity for Her-2. Then, a fine needle aspiration of the two lymph nodes in the right axilla was carried out, with positive cytology. With regard to a local recurrence in the left breast and in the contralateral axillary lymph nodes, a nuclear magnetic resonance imaging of the breasts was performed, which did not reveal changes in the right breast and confirmed the mammogram and ultrasound findings for the left breast and right axilla. The search for distant metastasis was negative in the chest computed tomography, abdomen computed tomography, and bone scintigraphy. The case was then discussed with the Oncology physicians, and it was chosen to begin a systemic chemotherapeutic treatment (six cycles of Docetaxel, Carboplatin and Trastuzumab), and later a left mastectomy with immediate reconstruction and right axillary lymph nodes dissection would be scheduled.

Discussion

BC staging is based on tumor involvement within the primary site, regional nodal disease, and presence or absence of distant metastasis. Regional nodal sites are defined as ipsilateral axillary, infra-clavicular, supraclavicular and internal mammary nodes⁹. Evidence of metastasis outside this area has traditionally been considered distant disease (stage IV).

The CAR is associated with an uncertain prognosis, but may have different prognostic implications than metastatic disease. Literature is scarce and mostly consists of small studies and case reports, in which the level of details and completeness of the reported data varied. Kiluk et al. postulated that CAR represents an extension of local-regional disease rather than distant

metastatic disease¹⁰. They suggest that CAR treatment should be served by a multidisciplinary approach. Chemotherapy (and hormonal therapy, when applicable) is an essential step due to the presumed presence of distant disease and the potential to treat microscopic disease circulating within dermal lymphatics outside the surgical and radiation fields. In the absence of other distant metastatic disease, surgery followed by radiation is a reasonable and feasible approach¹⁰.

In the largest series, Vugts et al observed that, in the 48 patients with CAR, the prognosis of CAR (overall survival of 82.6% after

a mean of 50.3 months) was not comparable to the prognosis of metastatic BC. The disease-free survival was 65.2% and the majority of patients received surgical and systemic treatment, suggesting a curative instead of palliative intent⁸.

The origin of CAR may be different to the origin of metastatic disease. Distant metastases occur due to systemic circulating spread of tumor cells, while CAR might originate due to aberrant lymph drainage from the ipsilateral breast to contralateral nodal basis, similar to ipsilateral lymph node recurrences. Drainage to the contralateral axilla has been described in 14.7% of patients in the largest available repeat sentinel lymph node biopsy (SNB) study. Aberrant drainage occurred more frequently after previous axillary lymph node dissection (ALND) than after previous SNB¹¹. Perre et al. also reported different patterns of breast lymphatic drainage after BC treatment through surgery and radiotherapy¹².

In the study of Vugts et al.⁸, time of recurrence between isolated CAR and CAR with synchronous IBTR was different. Isolated CAR occurred significantly earlier, within an average of 138 months and CAR with synchronous IBTR within an average of 108 months⁸. Additionally, prognosis of CAR (82.6% overall survival after a mean of 50.3 months) was much better than in patients with metastatic BC. Ipsilateral locoregional recurrent BC has a five-year disease free survival of 54 to 84%^{13,14}. The five-year overall survival mean of metastatic BC varies from 23% in patients with bone metastasis to only 13% in patients with visceral metastasis¹⁵.

It is important to perceive that CAR occurs mainly by lymphatic spread in most patients, and not by hematogenous spread. Management of patients with CAR should be individualized. If CAR accompanies systemic metastasis, systemic treatment should be essential. In the absence of distant disease, ALND can be a good option, which results in excellent axillary control¹⁶. Routine contralateral mastectomy is not usually indicated, except in some cases of hereditary BC. Radiation therapy is not routinely recommended either, but can provide an additional local control in selected cases². In the review of Vugts et al., a total of 89.5% of patients underwent surgery for their CAR, and 77.8% received chemotherapy and/or endocrine therapy⁸. This frequent use of surgery combined with systemic treatment implies that treatment is being done with curative rather than palliative intent, and seems to regard CAR as a regional rather than a distant event. This same study showed that in patients with isolated CAR, the interval from primary tumor to CAR was of 45.9 months, while in patients with CAR and synchronous IBTR, it was 126.6 months. They concluded that considering these results, CAR should not be registered as a distant event.

Conclusions

The contralateral axillary lymph node metastasis, especially after breast-conserving surgery plus radiotherapy, should be

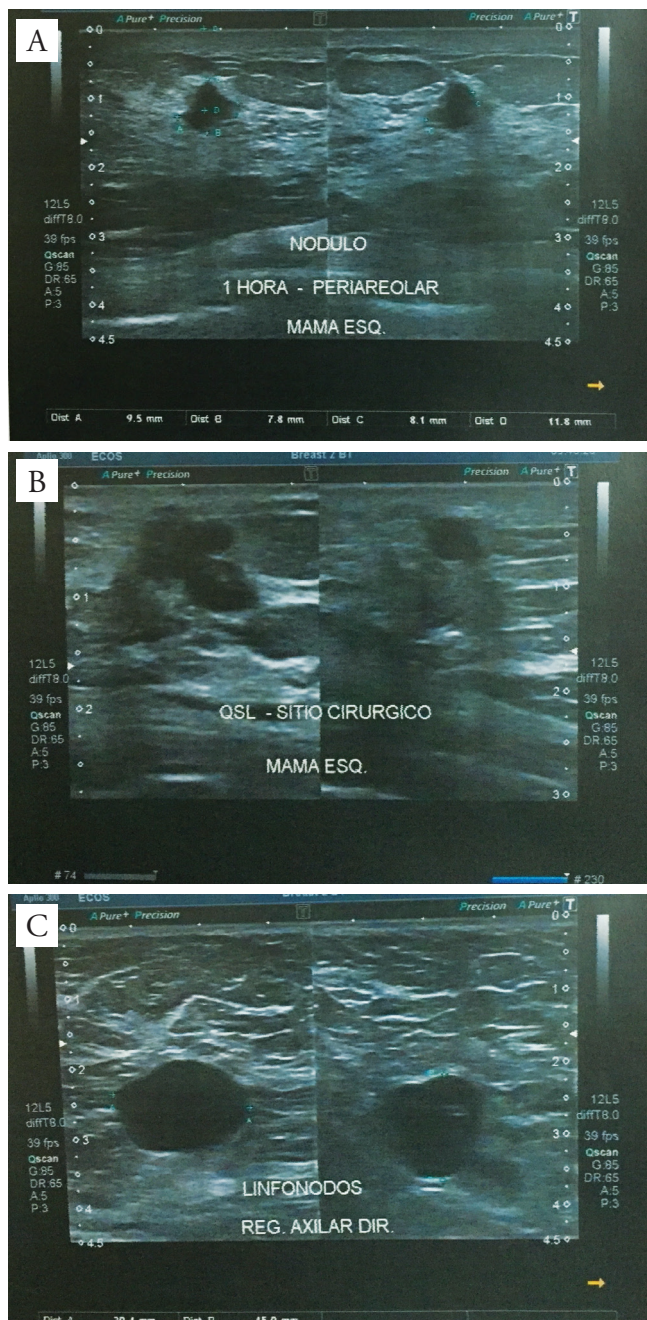


Figure 1. (A) Hypoechoic and irregular nodule in the left breast. (B) Heterogeneous and irregular image in the left breast – prior surgery topography. (C) Right axillary lymphadenopathy (increased size and echogenic central hilum loss).

considered not only a hematogeneous spread but also lymphatic spread. The observed disease-free and overall survivals indicate that CAR should be regarded a regional rather than distant disease and should be treated accordingly. Although compelling evidence is lacking, treatment of CAR should be of curative intent as patients might achieve a longer disease-free interval with a multimodality approach. If there is no evidence of other metastatic lesions, lymph node dissection needs to be carried out and proper systemic therapy should be used.

References

- Morcós B, Jaradat I, El-Ghanem M. Characteristics of and therapeutic options for contralateral axillary lymph node metastasis in breast cancer. *Eur J Surg Oncol*. 2011;37(5):418-21.
- Huston TL, Pressman PI, Moore A, Vahdat L, Hoda SA, Kato M, et al. The presentation of contralateral axillary lymph node metastases from breast carcinoma: a clinical management dilemma. *Breast J*. 2007;13(2):158-64.
- Edge SB, Compton CC. The American joint committee on cancer: the 7th edition of the AJCC cancer staging manual and the future of TNM. *Ann Surg Oncol*. 2010;17(6):1471-4.
- Boughey JC, Ross MI, Babiera GV, Bedrosian I, Feig BW, Kuerer HM, et al. Sentinel lymph node surgery in locally recurrent breast cancer. *Clin Breast Cancer*. 2006;7(3):248-53.
- Estourgie SH, Nieweg OE, Olmos RA, Rutgers EJ, Kroon BB. Lymphatic drainage patterns from the breast. *Ann Surg*. 2004;239:232-7.
- Maaskant-Braat AJ, de Bruijin SZ, Woensdregt K, Pijpers H, Voogd AC, Nieuwenhuijzen GA. Lymphatic mapping after previous breast surgery. *Breast*. 2012;21(4):444-8.
- Roumen RM, Kuijt GP, Liem IH. Lymphatic mapping and sentinel node harvesting in patients with recurrent breast cancer. *Eur J Surg Oncol*. 2006;32(10):1076-81.
- Vugts G, Moosdorff M, Strobbe LJ, Voogd AC, Smidt ML, Nieuwenhuijzen GA, et al. Contralateral lymph node recurrence in breast cancer: Regional event rather than distant metastatic disease. A systematic review of the literature. *Eur J Surg Oncol*. 2015;41(9):1128-36. <http://dx.doi.org/10.1016/j.ejso.2015.05.015>.
- Edge SB, Byrd DR, Compton CC, Fritz AG, Greene FL, Trotti A. *AJCC cancer staging manual*. 7th edition. New York, NY: Springer; 2010.
- Kiluk JV, Prowler V, Lee MC, Khapkpour N, Laronga C, Cox CE. Contralateral axillary nodal involvement from invasive breast cancer. *Breast*. 2014;23(3):291-4.
- Maaskant-Brant AJ, Roumen RM, Voogd AC, Pijpers R, Luiten EJ, Rutgers EJ, et al. Sentinel node and recurrent breast cancer (SNARB): results of a nationwide registration study. *Ann Surg Oncol*. 2013;20(2):620-6.
- Perre CI, Hoefnagel CA, Kroon BB, Zoetmulder FA, Rutgers EJ. Altered lymphatic drainage after lymphadenectomy or radiotherapy of the axilla in patients with breast cancer. *Br J Surg*. 1996;83(9):1258.
- Clemons M, Danson S, Hamilton T, Goss P. Locoregionally recurrent breast cancer: incidence, risk factors and survival. *Cancer Treat Rev*. 2001;27(2):67-82.
- Shenouda MN, Sadek BT, Goldberg SI, Croft BJ, Keruakous AR, Taghian AG, et al. Clinical outcome of isolated locoregional recurrence in patients with breast cancer according to their primary local treatment. *Clin Breast Cancer*. 2014;14(3):198-204.
- Giordano SH, Buzdar AU, Smith TL, Kau SW, Yang Y, Hortobagyi GN. Is breast cancer survival improving? *Cancer*. 2014;100:44-52.
- Gauthier T, Monteil J, Bourneton N, Jammet I, Tubiana N, Aubard Y. Contralateral axillary involvement in breast cancer recurrence: locoregional disease or metastasis? *Eur J Gynaecol Oncol*. 2010;31(6):694-6.