

CASE REPORT

Multiple bilateral fibroadenoma of the breast and axillary accessory breast: case report

Múltiplos fibroadenomas de mama bilateral e de mama acessória axilar: relato de caso

Délio Marques Conde¹, Larissa Cunha Morais¹, Cristiane Fagundes Pacheco¹, Rogério Bizinoto Ferreira¹, Érika Pereira de Sousa-e-Silva¹, Paulo Sérgio Peres Fonseca², Sebastião Alves Pinto³

ABSTRACT

This article has presented a rare case of multiple fibroadenomas of the breasts and axillary accessory breast. In the light of current knowledge, the most proper management is discussed. A 37-year-old woman was referred to our Breast Service due to complaint of a right axillary accessory breast nodule. On physical examination, there were no palpable breast nodules. Bilateral axillary accessory breast was observed with a right breast nodule and no alterations in the left breast. Mammography and ultrasonography demonstrated multiple bilateral breast nodules with benign characteristics and a possible malignancy in the right axillary nodule. The patient underwent a fine needle aspiration biopsy guided by ultrasonography of the largest nodule in each breast and of the nodule in the right axillary accessory breast. Cytologically, all nodules had benign characteristics. A diagnostic hypothesis of fibroadenoma was formulated. The patient underwent surgical removal of the right axillary nodule. The histopathological examination demonstrated fibroadenoma. Conservative management was chosen for the axillary accessory breasts and multiple breast fibroadenomas. At 11-month follow-up, there was neither recurrence of the right axillary nodule nor changes in the fibroadenomas. Conservative management of axillary accessory breast is possible. However, axillary accessory breast tissue may be affected by neoplasia. In cases of possible malignancy, the investigation should be carried out through the same clinical work-up used for normally-positioned breasts. In the presence of multiple bilateral fibroadenomas in the breasts, conservative management can be safely adopted.

RESUMO

Apresentamos um caso raro de múltiplos fibroadenomas envolvendo as mamas e a mama acessória axilar. À luz do conhecimento atual, a conduta mais adequada é discutida. Uma mulher de 37 anos foi encaminhada ao Serviço de Mastologia em função da queixa de nódulo em mama acessória axilar direita. No exame físico, não havia nódulos palpáveis nas mamas. Observou-se mama acessória axilar bilateral com nódulo à direita e sem alterações à esquerda. Mamografia e ultrassonografia demonstraram múltiplos nódulos de mama bilateral com características benignas e um nódulo suspeito de malignidade na axila direita. A paciente submeteu-se à punção aspirativa com agulha fina guiada por ultrassonografia do maior nódulo de cada mama e do nódulo na mama acessória axilar direita. Citologicamente, todos os nódulos apresentaram características benignas. Formulou-se a hipótese diagnóstica

Keywords

Fibroadenoma
Cytology
Ultrasonography
Mammography

Descritores

Fibroadenoma
Citologia
Ultrassonografia mamária
Mamografia

Trabalho realizado no Serviço de Mastologia, Hospital Materno Infantil – Goiânia (GO), Brasil.

¹Serviço de Mastologia, Hospital Materno Infantil – Goiânia (GO), Brasil.

²Serviço de Patologia, Hospital Materno Infantil – Goiânia (GO), Brasil.

³Serviço de Patologia, Instituto Goiano de Oncologia e Hematologia (INGOH) – Goiânia (GO), Brasil.

Endereço para correspondência: Délio Marques Conde – Hospital Materno Infantil – Rua R-7, esquina com Avenida Perimetral, s/n – Setor Oeste – CEP: 74530-020 – Goiânia (GO), Brasil – E-mail: delioconde@gmail.com

Conflito de interesses: nada a declarar.

Recebido em: 18/10/2015. Aceito em: 06/01/2016

de fibroadenoma. Paciente submeteu-se à remoção cirúrgica do nódulo na axila direita. O exame histopatológico demonstrou fibroadenoma. Decidiu-se por uma conduta conservadora para as mamas acessórias axilares e múltiplos fibroadenomas mamários. Após 11 meses de seguimento, não houve recidiva do nódulo na axila direita nem alterações dos fibroadenomas. A conduta conservadora na mama acessória axilar é possível, porém o tecido mamário acessório pode ser afetado por neoplasia. Nos casos suspeitos de malignidade, a investigação deve ser conduzida com os mesmos recursos propedêuticos utilizados nas mamas normalmente posicionadas. Na presença de múltiplos fibroadenomas nas mamas, a conduta conservadora pode ser adotada com segurança.

Introduction

Between the fifth and sixth week of embryonic development, thickened strips of epidermal ectoderm form the mammary ridges or embryonic milk lines¹. Normally-positioned breasts are derived from primordial ectoderm that generally persists in the pectoral region. However, persistence of ectodermal mammary streaks elsewhere along the milk line outside the pectoral region, resulting in the development of ectopic breast tissue (EBT)¹.

Anomalies of breast development affect between 1 and 5% of women and men². Supernumerary nipples (polythelia) and supernumerary breasts (polymastia) are examples of some anomalies, and polythelia is more common^{2,3}. Despite the low frequency, EBT can be found outside the milk lines. Polythelia and polymastia usually occur sporadically, but familial cases have been described³⁻⁵. Lactation, fibrocystic changes, abscesses, mastitis and benign and malignant neoplasias have been related in EBT⁶⁻⁸.

There have been reports of associations between EBT, most commonly polythelia, and cardiac arrhythmia, pyloric stenosis, epilepsy, hypertension⁹, dental anomalies⁵, and urinary tract malformations^{4,9}. However, other authors have failed to identify any relationship between polythelia and urinary tract malformations³. Despite these reports, EBT is only a cosmetic problem for the majority of patients.

Data available in the literature indicate that EBT deserves special attention, due to cosmetic issues and its association with malformations. EBT may also be affected by diverse conditions. Therefore, considering that neoplasias rarely arise from EBT, this article presents a case of multiple fibroadenomas of the breasts and axillary accessory breast. In the light of current knowledge, the most proper management is discussed.

Case report

A 37-year-old woman was referred to our Breast Service after complaint of a right axillary accessory breast nodule. The patient

had a history of accessory breasts in both axillae for 15 years, noticed after her second pregnancy. Her other complaint was a painless nodule in the right axilla for three years, which had increased in size. The patient reported menstrual-related swelling, pain and discomfort in her normally-positioned breasts and in the axillary accessory breasts.

Gynecologic and obstetric history included: age at thelarche (12 years), age at menarche (13 years), age at first childbirth (16 years), two pregnancies and two full-term deliveries. Oral contraceptives were used for six years until the patient underwent tubal ligation. She denied any use of psychotropic medication, immunosuppressants or any other type of drugs. There was neither personal nor family history of breast cancer and ovarian cancer. Her family history of polymastia and polythelia was negative.

On clinical examination, normally-positioned breasts without palpable nodules or papillary discharge were observed. Axillary accessory breasts, without nipples and areola, were noted. A mobile, well-defined and palpable mass was identified, measuring 2.4 cm in the right axillary accessory breast. No palpable nodules were identified in the left axillary accessory breast. Alterations such as nipples or accessory breasts were not found in other parts of the body.

Mammography demonstrated multiple round or oval, isodense masses with partially obscured margins involving both normally-positioned breasts. Bilateral axillary accessory breast was present (Figure 1). An isodense, circumscribed mass with microcalcifications was viewed in the right axilla (Figure 2). No mass was identified in the left axilla. Ultrasonography revealed multiple, round or oval, solid, homogeneous, hypoechoic, circumscribed masses, without posterior acoustic features in the breasts. In the right breast, 11 nodules were found and 9 were observed in the left breast, ranging in size from 0.45 to 1.94 cm. A solid, oval, homogeneous, hypoechoic circumscribed mass was identified, parallel to the skin, with discrete posterior acoustic shadowing in the right axillary accessory breast. In this mass, hyperechoic punctiform foci were identified compatible with intratumoral microcalcifications (Figure 3). No masses were identified in the left axillary accessory breast.

Electrocardiography, chest x-ray, complete blood count and total abdominal ultrasound were normal. Fine needle aspiration biopsy guided by ultrasonography of the largest nodule in each breast and of the nodule in the right axillary accessory breast was performed. Cytology revealed benign findings with solid tridimensional cell blocks with a double population and loose bipolar cells. Cell atypia was not identified. The nodules had similar cytologic characteristics. A diagnosis of fibroadenomas was made, although the mass in the axillary accessory breast had exhibited some imaging features of possible malignancy.

The patient underwent surgical excision of the right axillary accessory breast mass. Grossly, the cut surface of

the tumor was white and fibroelastic. The largest axis of the tumor measured 2 cm. Microscopy showed that the tumor had a biphasic growth pattern with epithelial and stromal proliferation, and intraductal microcalcifications. Cell atypia or malignancy was not identified in the epithelial and stromal components. On immunohistochemical study, there was p63-positive staining in myoepithelial cells, and tumor cells were estrogen-receptor-positive and progesterone-receptor positive. The Ki-67 index was 1%. Histopathology demonstrated fibroadenoma with microcalcifications (Figure 4). After the diagnosis, conservative treatment of axillary breasts and breast nodules was chosen following discussion with the patient. Mammography and breast ultrasound were performed six months after the initial evaluation. In comparison to previous tests, no change was identified. At 11-month follow-up exam, the patient had no evidences of recurrence.

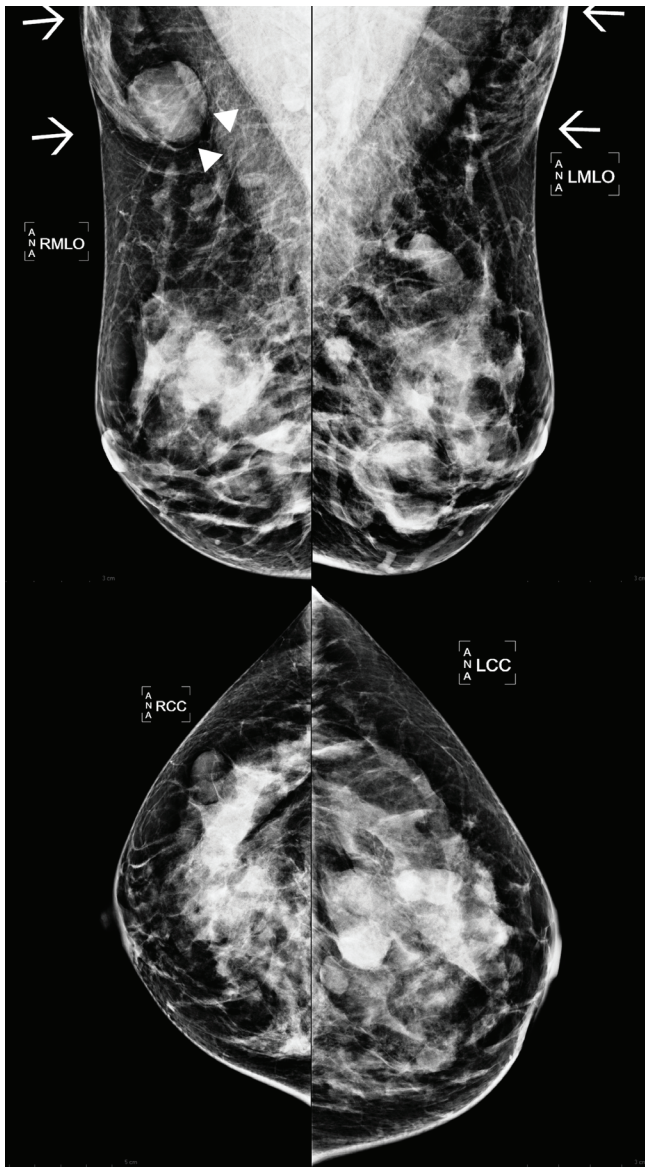


Figure 1. Mammogram showing multiple round and oval, isodense nodules with partially obscured margins, involving both normally-positioned breasts. Presence of bilateral axillary accessory breast (arrows). Circumscribed, isodense mass with microcalcifications in the right axillary accessory breast (arrowheads).

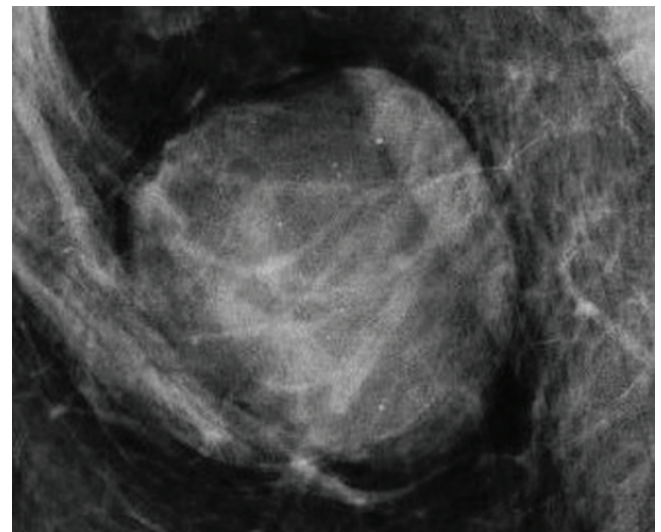


Figure 2. Spot magnification demonstrating circumscribed nodule with microcalcifications in the right axillary accessory breast.

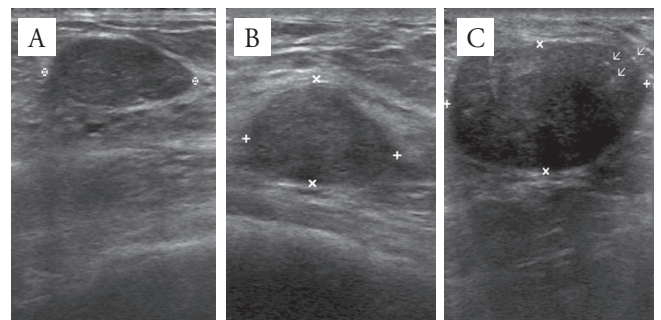


Figure 3. Breast ultrasound: right breast (A); left breast: ultrasonography showing solid, oval, hypoechoic, homogeneous, circumscribed masses, parallel to the skin, in both breasts (B); solid, oval, circumscribed, hypoechoic mass with discrete posterior acoustic shadowing in the right axillary accessory breast (C). Presence of hyperechoic punctiform foci compatible with intratumoral microcalcifications (arrows).

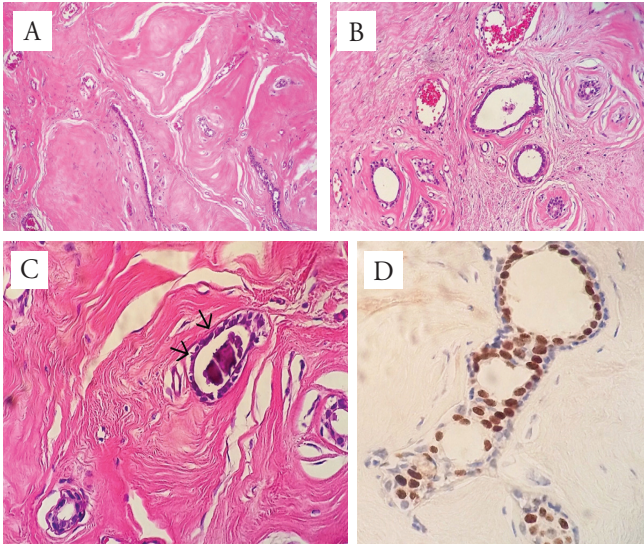


Figure 4. Photomicrographs of fibroadenoma in the right axillary accessory breast: biphasic proliferation with stromal and epithelial components without atypias (A); higher magnification demonstrating benign stromal component and more evident breast ducts (B); intraluminal microcalcification (arrows) (C); immunoreactivity for progesterone receptor (D).

Discussion

EBT is not an uncommon phenomenon and occurs most frequently in women. In the current case, menstrual-related symptoms associated with clinical findings indicated the presence of supernumerary breast in the axillae. The patient had no family history of EBT, and anomalies were not identified. Therefore, this was a sporadic case, without any associated malformation.

There are reports of familial EBT, despite its lower frequency. Genetic transmission of polythelia is more common in autosomal dominant disorders with incomplete penetrance and X-linked dominant disorders⁵. Galli-Tsinopoulou, Krohn and Schmidt³ reported familial polythelia over three generations. Polythelia and polymastia were identified in an 11-year-old girl. Supernumerary nipples were found in her brother, father, aunt (father's sister), aunt's daughter and grandfather. The authors did not identify urinary tract malformations³. However, in another report of familial polythelia spanning three generations, a 59-year-old man with a supernumerary nipple had hypoplastic kidney, bladder diverticulum, and hypotonic bladder. His mother had polythelia and a hypoplastic kidney. One of her children also had a history of hypoplastic kidney⁴. There is conflicting data in the literature regarding this topic. Thus, we believe that the association between EBT and urinary tract malformations or other malformations needs to be further elucidated.

EBT also merits attention due to another aspect, since it may undergo benign and malignant neoplasms similar to normally-positioned breasts. There are few reports of fibroadenoma arising

from the axilla⁷⁻¹⁰. Reports of multiple fibroadenomas involving both breasts and axillary accessory breast are even more unusual¹¹. Fibroadenoma is the most common breast tumor in adolescents and young women. The etiology of multiple fibroadenomas of the breast is not fully understood and 17% of patients may have this condition¹². There are some reports of multiple fibroadenomas associated with the use of immunosuppressants¹¹⁻¹³. Therefore, cyclosporine-induced fibroadenomas should be considered in the differential diagnosis of topical and ectopic breast tumors in users of this kind of medication. Our patient did not use any type of immunosuppressant drug.

Axillary accessory breast nodule may be nonpalpable, identified only by imaging methods¹⁰. They may also be clinically palpable or undetectable by clinical examination or imaging tests⁷. It will be possible to diagnose the mass only after surgical removal of EBT by histopathology. In the present case, excision of the axillary fibroadenoma was indicated, since imaging tests revealed findings that were suggestive of malignancy, i.e., posterior acoustic shadowing and microcalcifications.

To the best of our knowledge, similar features of fibroadenoma in the axillary accessory breast have not been reported in the literature. Ultrasonography has a high sensitivity for the fibroadenoma diagnosis¹². It usually depicts fibroadenoma as a homogenous, hypoechoic, circumscribed mass, without posterior acoustic shadowing, sometimes with a thin hyperechoic pseudocapsule¹⁴, as observed in the breast nodules of our patient. However, previous studies reported the presence of posterior acoustic shadowing in 6% of fibroadenomas, and intratumoral calcifications in 10% of these lesions¹⁵. There may be coarse calcifications or microcalcifications¹⁵. Magnetic resonance imaging may have assisted in the preoperative differential diagnosis of axillary breast nodule¹⁶.

Differential diagnosis of an axillary mass includes hidradenitis suppurative, lymphoma, lymphadenopathy, lipoma, metastatic carcinoma, and axillary breast cancer¹⁷. The most feared diagnosis is breast cancer. Although axillary breast cancer is concerning, it accounted for only 0.3% of all breast cancers¹⁷. Despite the low malignancy rate, this diagnosis should always be ruled out when an axillary mass is present.

An interesting question arises: what is the management regarding breast nodules? In the current case, there were three reasons for conservative treatment. First of all, the similar ultrasound characteristics of the breast masses, i.e., solid, homogeneous, hypoechoic, and circumscribed masses, without posterior acoustic shadowing, suggesting a benign condition. Carty et al.¹² followed 25 fibroadenomas by ultrasonography and clinical examination. At a follow-up of at least 5 years, these authors failed to identify any carcinoma at the site of the presumed fibroadenoma. Previous studies have demonstrated the safety of imaging follow-up in solid breast nodules exhibiting benign characteristics viewed through ultrasonography¹⁸. This approach has a high negative predictive value of 99.8% for breast masses¹⁸. In these cases, biopsy can be

avoided and ultrasonography and follow-up may be an alternative method¹⁸. The second reason for choosing conservative treatment was the benign cytomorphological characteristics of the breast nodules. Cytology has a high sensitivity for the diagnosis of fibroadenoma, which has been reported in 84%¹² and 97%¹⁹ of cases. In the current case, a combination of ultrasonography and cytologic findings suggested a diagnosis of fibroadenoma for the nodules which did not undergo biopsy. In clinical practice, watchful waiting is safer in presumed fibroadenomas¹². The third and not least important reason was to avoid undesirable scarring with breast deformity, resulting from the surgical removal of a large number of masses. This procedure would be of no benefit to the patient.

Another controversial question is whether there is a need for surgical excision of axillary EBT. Some authors suggest surgical removal of the axillary accessory breast. It is worth mentioning that surgery is not devoid of morbidity. In a series of 28 patients undergoing surgical removal of axillary accessory breast tissue, there were complications in 39.3% of cases, including seroma, poor wound healing, incomplete excision of accessory tissue, intercostobrachial nerve injury and infection²⁰. Considering these aspects and maintaining close follow-up care, conservative treatment was chosen after discussion with the patient.

Conclusion

Conservative management of axillary accessory breast is possible, although ectopic breasts may be affected by neoplasms. In cases of suspected malignancy, investigation is carried out through the same clinical work-up used in normally-positioned breasts, observing due indications. This approach prevents a delay in diagnosis. When multiple bilateral presumed fibroadenomas of the breast occur, a watchful waiting approach is safer.

References

- Bland KI, Copeland EM. The breast: comprehensive management of benign and malignant diseases. 4th ed. Philadelphia: Saunders; 2009.
- Dixon JM, Mansel RE. ABC of breast diseases. Congenital problems and aberrations of normal breast development and involution. *BMJ*. 1994;309(6957):797-800.
- Galli-Tsinopoulou A, Krohn C, Schmidt H. Familial polythelia over three generations with polymastia in the youngest girl. *Eur J Pediatr*. 2001;160(6):375-7.
- Brown J, Schwartz RA. Supernumerary nipples and renal malformations: a family study. *J Cutan Med Surg*. 2004;8(3):170-2.
- Fonseca GM, Cantin M. Familial polythelia associated with dental anomalies: a case report. *Colomb Med (Cali)*. 2014;45(1):45-7.
- Osswald SS, Osswald MB, Elston DM. Ectopic breasts: familial functional axillary breasts and breast cancer arising in an axillary breast. *Cutis*. 2011;87(6):300-4.
- Aughsteeen AA, Almasad JK, Al-Muhtaseb MH. Fibroadenoma of the supernumerary breast of the axilla. *Saudi Med J*. 2000;21(6):587-9.
- Shin SJ, Sheikh FS, Allenby PA, Rosen PP. Invasive secretory (juvenile) carcinoma arising in ectopic breast tissue of the axilla. *Arch Pathol Lab Med*. 2001;125(10):1372-4.
- Pellegrini JR, Wagner RF Jr. Polythelia and associated conditions. *Am Fam Physician*. 1983;28(3):129-32.
- Mukhopadhyay M, Saha AK, Sarkar A. Fibroadenoma of the ectopic breast of the axilla. *Indian J Surg*. 2010;72(2):143-5.
- Bulakci M, Gocmez A, Demir AA, Salmaslioglu A, Tukenmez M, Yavuz E, et al. Fibroadenomatosis involving bilateral breasts and axillary accessory breast tissues in a renal transplant recipient given cyclosporin A. *J Clin Ultrasound*. 2014;42(8):495-7.
- Carty NJ, Carter C, Rubin C, Ravichandran D, Royle GT, Taylor I. Management of fibroadenoma of the breast. *Ann R Coll Surg Engl*. 1995;77(2):127-30.
- Yarak S, Floriano M, Decico JE, Konishi CT, Michalany NS, Enokihara MY, et al. First report of a fibro-adenoma in axillary mammary tissue of a renal transplant patient taking cyclosporin. *Int J Dermatol*. 2007;46(4):407-9.
- Stavros AT, Thickman D, Rapp CL, Dennis MA, Parker SH, Sisney GA. Solid breast nodules: use of sonography to distinguish between benign and malignant lesions. *Radiology*. 1995;196(1):123-34.
- Fornage BD, Lorigan JG, Andry E. Fibroadenoma of the breast: sonographic appearance. *Radiology*. 1989;172(3):671-5.
- Yuen S, Uematsu T, Uchida Y, Kasami M, Yukisawa S, Aramaki T, et al. Magnetic resonance imaging findings in an axillary accessory breast fibroadenoma. *Breast J*. 2005;11(6):493-4.
- Cheong JH, Lee BC, Lee KS. Carcinoma of the axillary breast. *Yonsei Med J*. 1999;40(3):290-3.
- Graf O, Helbich TH, Hopf G, Graf C, Sickles EA. Probably benign breast masses at US: is follow-up an acceptable alternative to biopsy? *Radiology*. 2007;244(1):87-93.
- Kollur SM, El Hag IA. FNA of breast fibroadenoma: observer variability and review of cytomorphology with cytohistological correlation. *Cytopathology*. 2006;17(5):239-44.
- Down S, Barr L, Baildam AD, Bundred N. Management of accessory breast tissue in the axilla. *Br J Surg*. 2003;90(10):1213-4.