

A CLINICAL-PATHOLOGICAL CORRELATION IN THE DIAGNOSIS OF BREAST SARCOMA

Correlação clinicopatológica no diagnóstico de sarcoma de mama

Laura dos Santos Cesa^{1*}, Bárbara Cristina Filippini¹, Liara Camila Tusset²,
Nicolas Silva Lazaretti², Rubens Rodriguez^{1,3}, Rafael Ribeiro Martini^{1,4}

ABSTRACT

Breast sarcomas are rare tumors that are difficult to diagnose. They are characterized by a mobile and painless mass with accelerated growth. This neoplasm represents less than 1% of all breasts malignancies and less than 5% of all soft tissues sarcomas. The present publication reports the case of a 78 year old patient, who was referred to the Hospital da Cidade de Passo Fundo's Mastology Ambulatory due to a suspicious mass occupying almost the entire right breast (BI-RADS[®]5). The diagnosis of breast sarcoma was made through the correlation between a clinical evaluation and an anatomopathological exam, and was supplemented by an immunohistochemistry and oncologic evaluation. The patient developed lung and liver metastasis three months after surgery. This paper aimed to report an unusual case of a breast tumor and the difficulty in performing its diagnosis, even after surgery. In the end, a multidisciplinary evaluation was needed.

KEYWORDS: Sarcoma; breast; immunohistochemistry; breast neoplasms; neoplasms.

RESUMO

Sarcomas de mama são tumores raros e de difícil diagnóstico, que se apresentam como uma massa indolor, móvel e de crescimento acelerado. Essa neoplasia representa menos de 1% de todas as malignidades da mama e menos de 5% de todos os sarcomas de tecidos moles. Relata-se nesta publicação o caso de uma paciente de 78 anos, encaminhada ao Ambulatório de Mastologia do Hospital da Cidade de Passo Fundo em razão de uma massa suspeita ocupando quase a totalidade da mama direita (BI-RADS[®]5), que teve diagnóstico de sarcoma de mama, o qual foi obtido por meio da correlação entre avaliação clínica, exame anatomopatológico complementado por estudo imuno-histoquímico e avaliação oncológica. A paciente evoluiu com metástase pulmonar e hepática três meses após a intervenção cirúrgica. O objetivo deste trabalho foi relatar um caso inusitado de tumor de mama e a dificuldade em realizar o diagnóstico, mesmo após intervenção cirúrgica, tendo sido necessária uma avaliação multidisciplinar.

PALAVRAS-CHAVE: Sarcoma; mama; imuno-histoquímica; neoplasias da mama; neoplasias.

Study carried out at the Hospital da Cidade de Passo Fundo – Passo Fundo (RS), Brazil.

¹School of Medicine, Universidade de Passo Fundo – Passo Fundo (RS), Brazil.

²Clinical Oncology Service, Hospital da Cidade de Passo Fundo – Passo Fundo (RS), Brazil.

³Instituto de Patologia de Passo Fundo – Passo Fundo (RS), Brazil.

⁴Mastology and Breast Reconstruction Service, Hospital da Cidade de Passo Fundo – Passo Fundo (RS), Brazil.

*Corresponding author: laura.cesa@hotmail.com

Conflict of interests: nothing to declare.

Received on: 11/25/2016. Accepted on: 05/30/2017

INTRODUCTION

Breast sarcomas are rare and low-frequency tumors. The first case of breast sarcoma was described in the literature in 1828, by Chelius¹. This tumor seems to affect both pre- and post-menopausal women¹. Its low incidence and the lack of a specific pattern of how it presents itself make it so that, at the time of diagnosis, it is often unsuspected. As such, only 50% of cases are diagnosed properly¹. We present here the case of a patient with an extensive neoplastic lesion in the right breast, whose diagnosis was defined by the correlation of clinical, macroscopic and histological information of the lesion, which is considered to be a primary breast sarcoma.

CASE REPORT

PPSM, female, 78 years old, was referred to the Ambulatory of the Hospital da Cidade de Passo Fundo (HCPF), Rio Grande do Sul, for a change in the image examination (breast ultrasound) performed on October 2, 2015. She is a former smoker (smoked for 6 years, 8 straw cigarettes/day, and stopped 59 years ago). She was in treatment for systemic arterial hypertension for 10 years and congestive heart failure. The patient has a previous history of breast cancer in the left breast, and had a radical mastectomy performed 22 years ago. There is no information about adjuvant treatment. One year ago, she underwent a biopsy of the right breast, in her city of origin, and had a benign anatomopathological examination.

Upon physical examination, a tumor was felt occupying the entire right breast, with a clinically negative axilla (Figure 1).

Regarding the examinations brought in by the patient, the US revealed the right breast node, which measured 5.7 cm, BI-RADS[®] 5 report; the core-biopsy showed evidence of the proliferation of oval cells with an extensive area of necrosis; and the

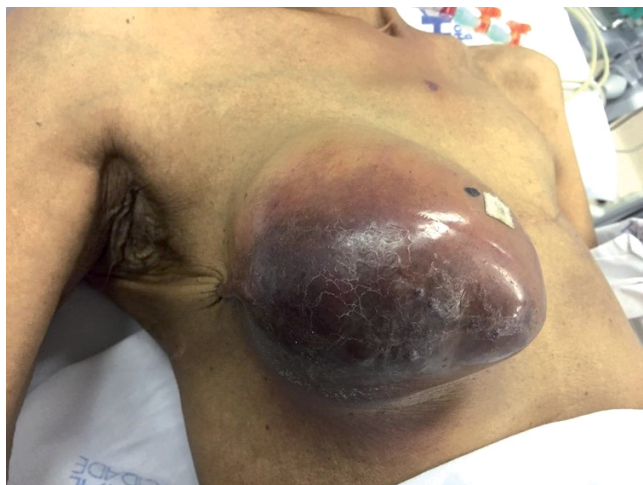

Figure 1. Right breast, preoperative aspect.

following immunohistochemistry inferred atypical lymphoid infiltrate with extensive areas of necrosis. From this information, surgical intervention with a transoperative examination was planned. At the time of admission, the lesion occupied the entire right breast and showed no evidence of lymphadenomegaly. In view of this, and because the previous biopsies showed no clear pathology, the tumor excision was characterized in the mastectomy itself. The definitive anatomopathology revealed oval and giant multinucleated cells neoplasia with vascular proliferation and extensive tumor necrosis, measuring 10.5 × 9.5 cm. The immunohistochemical study revealed positive neoplastic cells with a vimentin antibody (Figure 2). There was no positivity with the pancytokeratin, Melan A, CD31, S100 and desmin antibodies. The immunohistochemical study identified a pleomorphic malignant neoplasm that had an undefined histogenesis. Through process of elimination, it was considered a primary breast sarcoma.

Systemic staging did not show metastasis from a distance. The patient followed up with clinical oncology and developed pulmonary and hepatic metastasis three months after surgery, and thus remained on doxorubicin chemotherapy.

DISCUSSION

Primary breast sarcoma is a rare tumor that accounts for 1% of all breast cancers and has an approximate incidence of 4.6 new cases per million women²⁻⁴. In this group of neoplasias, we also found malignant phylloid tumors, carcinosarcomas, liposarcomas, osteosarcomas, angiosarcomas, malignant histiocytobromas and leiomyosarcomas². The main diagnosis of breast sarcoma that is different from the others, is that of metaplastic carcinoma, which should always be discarded^{2,5}. An immunohistochemical study may help differentiate these entities. Negativity to pancytokeratin excludes the possibility of metaplastic carcinoma, and negativity to Melan A, CD31, S-100 and desmin removes the possibility of melanoma, angiosarcoma, liposarcoma and leiomyosarcoma, respectively. Vimentin is positive in sarcomas.

The main clinical display of breast sarcoma is of a painless, mobile, fast-growing and diffuse mass, with an average size of 5 cm. It occurs in an increased incidence in people in their 50s and 60s. Bilateral and axillary involvement are rarely described². Diagnosis is often difficult, and is usually done by histopathology after surgical removal of the lesion², since mammography and US are non-specific^{3,6}. The tumor tends to have a reserved prognosis. Because size of the lesion is the most important variable, it is related, in addition to the long-term prognosis, to the local recurrence.

Given the rarity of breast sarcomas, there are no prospective randomized trials that guide treatment⁷. A multidisciplinary approach in a referral center, involving surgery,

radiotherapy and oncological evaluation, is indicated. In general, the choice of treatment is influenced by the stage of the tumor, its histological grade and its size⁷. Axillary lymph node metastasis hardly occurs. To treat it, the preferred method is resection with wide margins and without axillary emptying^{1-3,5,6}. For tumors larger than 5 cm, a simple mastectomy is recommended, since local resection, in these cases, is associated with a considerable relapse rate. Axillary lymph node resection is only recommended when clinically compromised¹. The most common sites of metastases described in the literature are the lungs and the liver.

Chemotherapy is not effective in this type of neoplasia, although in combination with another treatment method, there may be some clinical improvement. Adjunctive radiotherapy is associated with a decreased likelihood of local recurrence. Retrospective studies have shown that the use of radiotherapy may influence disease-free survival¹, especially in cases of high-grade sarcoma².

Early diagnosis is considered difficult, since the tumor grows rapidly and its histopathological classification is difficult to determine, causing the treatment to be extended and harming the prognosis².

In the immunohistochemical examination, there are several markers that can be applied - one is the vimentin antibody, a cell marker of mesenchymal origin, such as sarcomas.

CONCLUSION

In the present case reported, we have a rare tumor - breast sarcoma - whose diagnosis was made possible by correlating clinical signs and symptoms, macroscopy, histology, preoperative and post-operative immunohistochemical studies, and an evolution with short-term systemic metastasis. This wide range of information open to investigation makes the early diagnosis very difficult, increasing the medical team's concern to treat an aggressive, fast-growing tumor. As such, the prognosis is affected by the prolongation of the treatment.

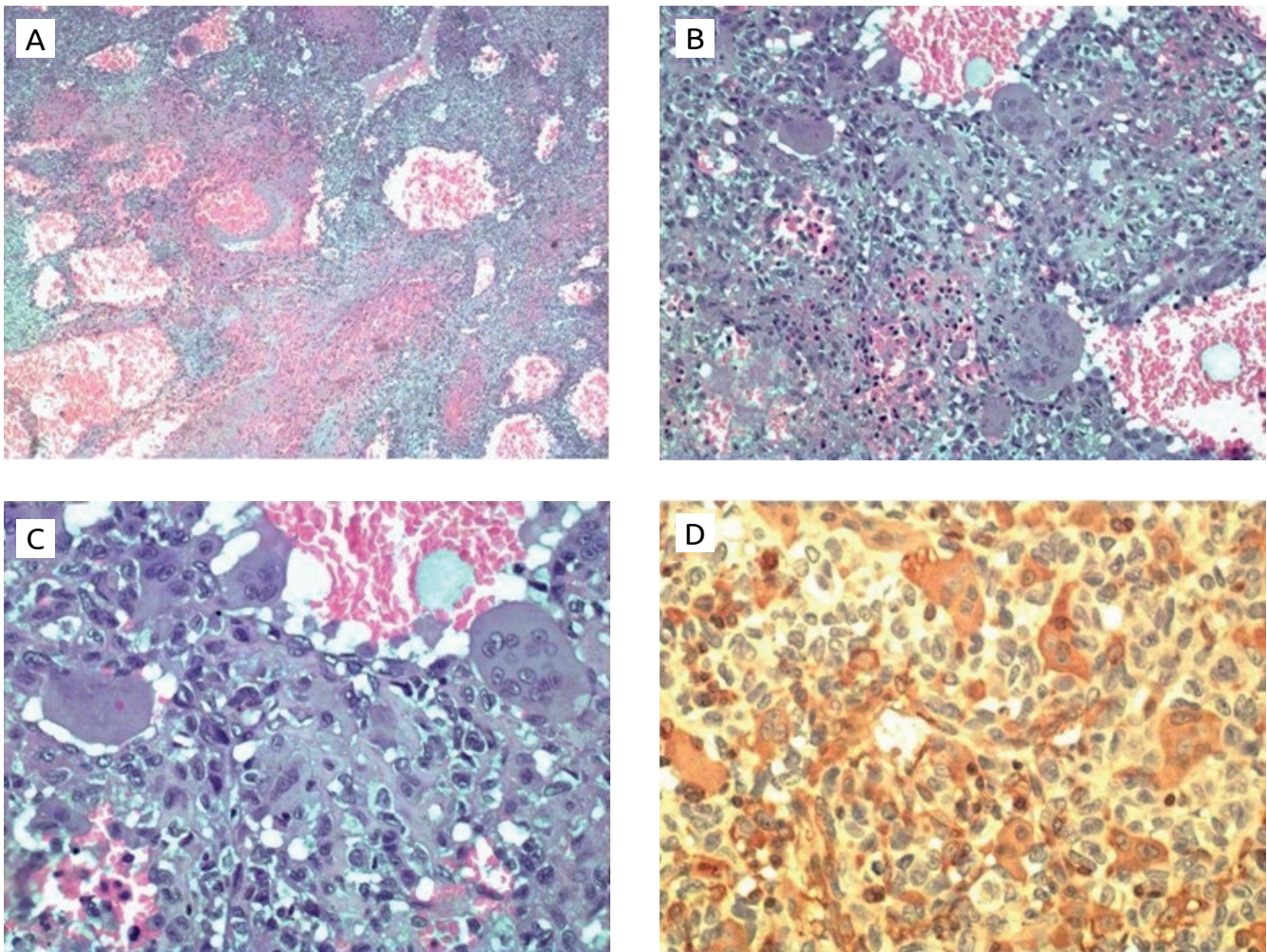


Figure 2. (A) Area of necrosis and tumor hemorrhage. HE-25x; (B) multinucleated giant tumor cells. HE-100x; (C) pleomorphic tumor cells and giant multinucleated cells HE-200x; (D) positive neoplastic cells with vimentin antibody, 200x.

REFERENCES

1. Koffmann B, Warnken OA, Cornejo S, Cornejo J. Sarcomas de la Mama. Sociedad Chilena de Mastología – Consenso em Cáncer de Mama. 1999;79-82.
2. Sousa EDP, Santos Filho AB, Dias CP. Sarcoma de mama: relato de caso. Rev Bras Mastologia. 2011;21(2):78-80.
3. Custódio S, Saleiro S, Dias M, Oliveira CF. Sarcoma de mama – Avaliação de uma série de 11 casos. Acta Obstet Ginecol Port. 2007;1(1):15-8.
4. Chugh R, Sabel MS, Feng M. Breast sarcoma: Epidemiology, risk factors, clinical presentation, diagnosis and staging. Up To Date. 2015.
5. Adem C, Reynolds C, Ingle JN, Nascimento AG. Primary breast sarcoma: clinicopathologic series from the mayo clinic and review of the literature. Br J Cancer. 2004;91:237-41.
6. Pencavel TD, Hayes A. Breast sarcoma – a review of diagnosis and management. Int J Surgery. 2009;7:20-3.
7. Chugh R, Sabel MS, Feng M. Breast sarcoma: Treatment. Up To Date. 2015.