

# BREAST RECONSTRUCTION USING EXPANDER AND FAT GRAFTING AFTER MASTECTOMY ASSOCIATED TO RADIOTHERAPY

Reconstrução mamária com o uso de expansor e lipoenxertia após mastectomia associada a radioterapia

Bruno Bohrer Flores<sup>1\*</sup>, Maria del Rosario Sarmiento Piñeres<sup>1</sup>, Roberto José da Silva Vieira<sup>2</sup>, Carlos Ricardo Chagas<sup>1</sup>, Gabriela Volkart Pinho<sup>3</sup>

## ABSTRACT

Breast surgery has evolved very rapidly in recent years. New oncoplastic techniques have emerged, which allowed the maintenance of a good approach in surgical treatment of breast cancer, reducing the physical and mental suffering of the patients for presenting better aesthetic results. This case report refers to a 45-year-old female patient who underwent mastectomy and radiotherapy eight years ago due to breast cancer, and had her breast reconstructed with the use of a submuscular expander associated to fat grafting. This study aimed to show a therapeutic option in breast reconstruction.

**KEYWORDS:** Mammoplasty; mastectomy; radiotherapy; fat grafting.

## RESUMO

A cirurgia da mama nos últimos anos evoluiu de forma muito rápida. Novas técnicas de oncoplastia surgiram, o que permitiu manter uma ótima abordagem no tratamento cirúrgico do câncer de mama, diminuindo o sofrimento físico e mental das pacientes por apresentar melhores resultados estéticos. Este relato de caso refere-se a uma paciente do sexo feminino de 45 anos, que foi submetida à mastectomia e radioterapia do plastrão há oito anos, em decorrência de câncer de mama, e teve sua mama reconstruída com o uso de expansor submuscular associado à lipoenxertia. O objetivo deste trabalho foi demonstrar uma opção terapêutica na reconstrução mamária.

**DESCRITORES:** Mamoplastia; mastectomia; radioterapia; lipoenxertia.

Study carried out at Pontifícia Universidade Católica – Rio de Janeiro (RJ), Brazil.

<sup>1</sup>Pontifícia Universidade Católica – Rio de Janeiro (RJ), Brazil.

<sup>2</sup>Fundação Oswaldo Cruz - Rio de Janeiro (RJ), Brazil.

<sup>3</sup>General Hospital of Fundação Universidade de Caxias do Sul - Caxias do Sul (RS), Brazil.

**\*Corresponding author:** brunobohrerflores@hotmail.com

**Conflict of interest:** nothing to declare.

**Received on:** 02/08/2017. **Accepted on:** 05/30/2017

## INTRODUCTION

Breast surgery has evolved very rapidly in recent years. New oncoplastic techniques have emerged, which allowed the maintenance of a good approach in surgical treatment of breast cancer, reducing the physical and mental suffering of the patients for presenting better aesthetic results.

Breast fat grafting consists of grafting fat, transferring mature adipocytes and stem cells derived from the adipocyte to the region of the breast where it is supposed to cover a defect. It became more frequent in the mid-1990s, with American surgeon Sidney Coleman being the main responsible for systematizing all the preparation required by the technique, from obtaining the materials to grafting the fat in the desired area<sup>1</sup>.

Considered a very safe technique, fat grafting aims to improve or correct significant contour deformities after a primary mammary reconstruction<sup>2</sup> or adjuvant treatments, such as radiotherapy<sup>3</sup>.

This report presents the case of a 45-year-old female patient who underwent mastectomy and radiotherapy eight years ago due to breast cancer.

## CASE REPORT

The 45-year-old patient sought medical consultation wishing to perform reconstruction of the right breast.

She has had a history of breast cancer eight years ago. The treatment consisted of mastectomy of the breast affected by the disease (right breast), complemented by chemotherapy and radiotherapy in the plastron.

The patient wished to perform breast reconstruction in a less aggressive manner, having discarded reconstruction techniques with myocutaneous flap of the large dorsal or the rectus abdominis myocutaneous flap (TRAM flap). These two techniques facilitate the procedure by providing skin from other regions and can replace the portion that has undergone radiation. They also provide muscle, which improves the coverage of the implant, contributing to the softness, the naturalness, the better degree of ptosis and the symmetry with the opposite breast, besides allowing the perception of a soft, warm breast with natural placement and appearance<sup>4</sup>.

After discussing the possible surgical techniques with the patient, the option chosen was the placement of a submuscular expander, as well as performing breast fat grafting.

The procedure begins with the collection of fat by liposuction at low pressure with a 60 mL syringe, coupled to the blunt cannula on both flanks (Figure 1). The syringes remain in a vertical position, waiting for the decantation of the material, which is divided into: oily material, live adipocytes, erythrocytes and serum (Figure 2). After complete decanting, only the area in which live adipocytes are found is kept in the syringes, with the rest of the material being discarded.

After carrying out the submuscular lodging for the placement of the implant, and with the Blake drain already fixed, the liposuction material is injected into the subcutaneous tissue.

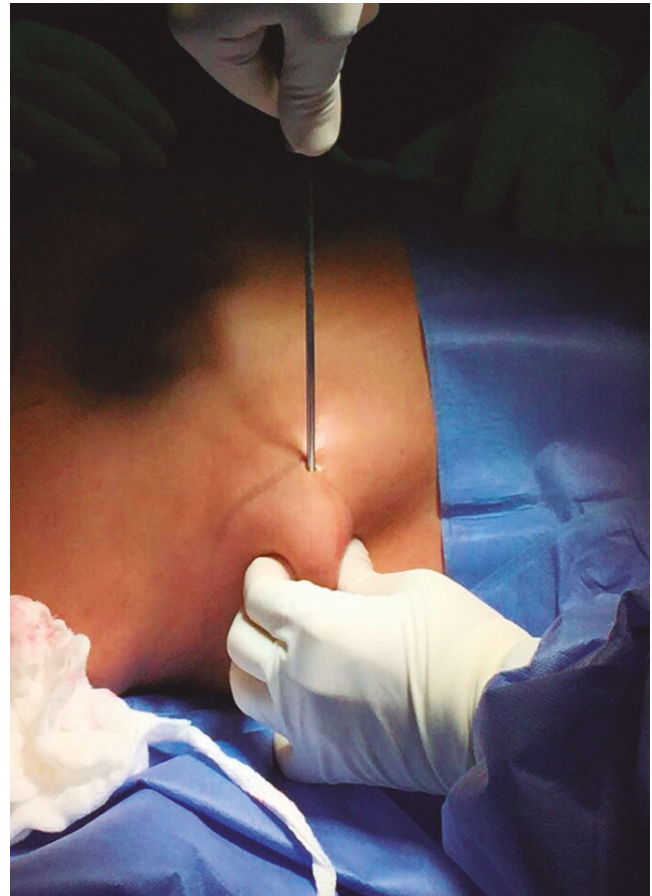


Figure 1. Fat collection by liposuction of flanks.

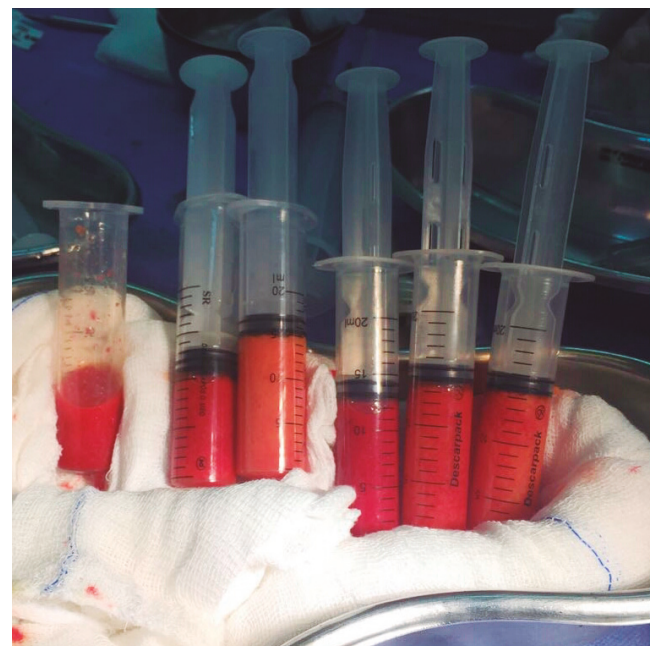


Figure 2. Syringes with collected material, awaiting decantation.

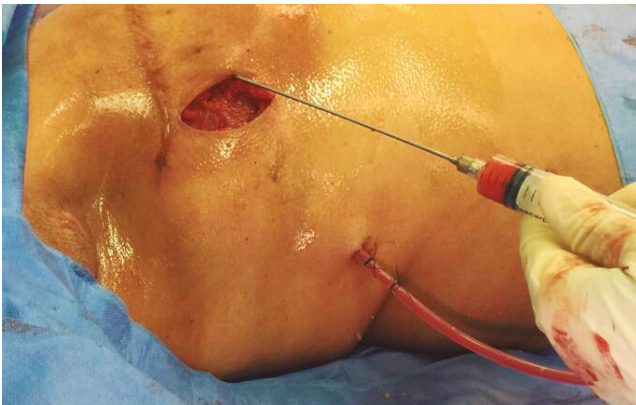
This procedure is done in several directions for an even distribution of fat (Figure 3).

Afterwards, the expander is inserted in the submuscular lodging, and the tissue synthesis is performed by planes: muscular, subcutaneous and skin, presenting the final result shown in Figure 4.

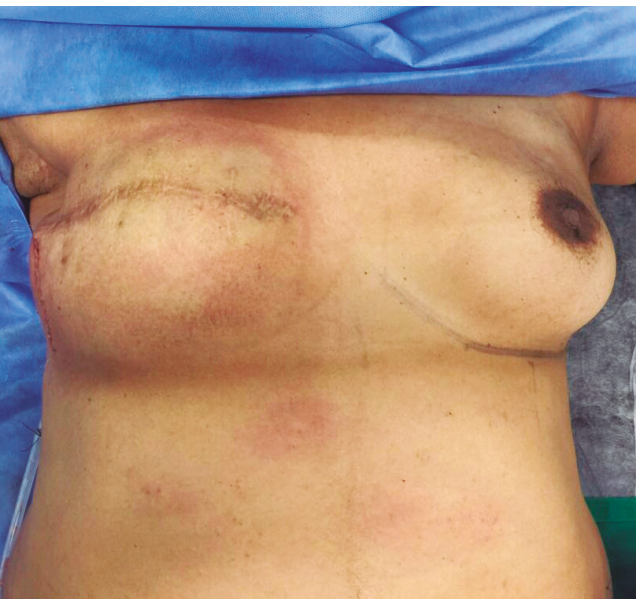## DISCUSSION

Since the 1980s, the late and immediate breast reconstruction technique began to disseminate and, which demonstrated that there is no additional risk to oncological evolution<sup>5</sup>.

The musculocutaneous conditions of the chest wall after mastectomy, the degree of involvement of the skin after radiotherapy, the contralateral breast dimension and its ptosis are factors that must be taken into account when evaluating the



**Figure 3.** Injection of liposuction material into the subcutaneous tissue.



**Figure 4.** Immediate postoperative result.

possibility to use the expander, as poor evaluation may lead to an unsatisfactory aesthetic result<sup>6</sup>.

The use of tissue expansion causes a gradual stretching of the tissues, allowing subsequent coverage of the new silicone implant with relative abundance of tissue, which would simulate a ptosis in the reconstructed breast, generating a more natural result. Although the expanders are mostly used in late reconstructions, they have been increasingly used in immediate reconstructions. As an advantage, this use removes the surgeon's doubt as to whether the amount of skin remaining from a mastectomy will allow direct placement of a breast implant. In addition, if there is doubt in the performance of postoperative radiotherapy, the expander would serve to maintain the cutaneous framework, preserved in the mastectomy until the conclusion of the treatment<sup>7</sup>.

The main indications for breast fat grafting are: correction of post-reconstruction filling defects with implants or flaps; improvement of skin and subcutaneous quality after mastectomy and radiotherapy; correction of filling defects after conservative breast surgery; treatment of post-reconstruction capsular contracture with implants; breast augmentation without the use of allogeneic implants; and improvement of scar quality in the breast<sup>1</sup>.

Studies have shown that breast fat grafting does not increase locoregional or systemic recurrence, or a second breast cancer. These findings support the oncological safety of lipofilling and fat grafting in breast reconstruction<sup>8</sup>.

When there is the need for image investigation or monitoring, mammography and mammographic ultrasound are performed. It is known that fat grafting causes radiological alterations, but these do not differ from other findings caused by other surgical procedures. Also, there has not been an increase in the number of biopsies performed as a result of such findings<sup>1,9</sup>.

Regarding the viability of grafts after fat grafting, most studies estimate that 30 to 40% of the volume is lost after the first procedure, thus requiring subsequent procedures or overcorrection in grafting<sup>9-11</sup>.

The rate of complications is low, with fatty necrosis being the most frequent, followed by local infection of the grafted material<sup>9</sup>.

## CONCLUSION

Breast fat grafting presents a low rate of complications, oncological safety and good aesthetic results, being an important tool in the aesthetic breast treatment.

Its major disadvantage would be the impossibility of accurately measuring the amount of tissue that will be reabsorbed, with many cases requiring several sessions to achieve the desired result.

1. Brenelli F, Rodriguez M, Urban Cícero, Frasson A. Lipoenxertia mamária. *Doenças da mama*. 2013;299-305.
2. Bezerra FJF, Moura RMG, Maia Neto JD. Lipoenxertia em reconstrução mamária. *Rev Bras Cir Plást*. 2013;28(2).
3. Rigotti G, Marchi A, Galiè M, Baroni G, Benati D, Krampera M, et al. Clinical treatment of radiotherapy tissue damage by lipoaspirate transplant: a healing process mediated by adipose-derived adult stem cells. *Plast Reconstr Surg*. 2007;119(5):1409-22.
4. Accorsi A, Doncatto L. Reconstruções mamárias imediatas e tardias. In: Liacyr Ribeiro. *Cirurgia Plástica da Mama*. 2.<sup>a</sup> ed. Rio de Janeiro: Medbook; 2012.p. 87-107.
5. Petit JY, Le MG, Mouriesse H, Rietjens M, Gill P, Contesso G, et al. Can breast reconstruction with gel-filled silicone implants increase the risk of death and second primary cancer in patients treated by mastectomy for breast cancer? *Plast Reconstr Surg*. 1994;94:115-9.
6. Rietjens M, Urban CA. *Cirurgia da Mama: Estética e Reconstructora*. Rio de Janeiro: Revinter; 2007. p.418-34.
7. Ribeiro L. *Cirurgia Plástica da Mama*. 2.<sup>a</sup> edição. Rio de Janeiro: Medbook; 2012. p. 87-107.
8. Kronowitz SJ, Mandujano CC, Liu J, Kuerer HM, Smith B, Garvey P, et al. Lipofilling of the Breast Does Not Increase the Risk of Recurrence of Breast Cancer: A Matched Controlled Study. *Plast Reconstr Surg*. 2016 Feb;137(2):385-93. doi: 10.1097/01.prs.0000475741.32563.50.
9. Blumenschein AR, Freitas-Junior R, Tuffanin AT, Blumenschein DI. Lipoenxertia nas mamas: procedimento consagrado ou experimental? *Rev Bras Cir Plást*. 2012;27(4):616-22.
10. Missana MC, Laurent I, Barreau L, Balleyguier C. Autologous fat transfer in reconstructive breast surgery: indications, technique and results. *Eur J Surg Oncol*. 2007;33(6):685-90.
11. Kanchwala SK, Glatt BS, Conant EF, Bucky LP. Autologous fat grafting to the reconstructed breast: the management of acquired contour deformities. *Plast Reconstr Surg*. 2009;124(2):409-18.