

USE OF DERMOGLANDULAR FLAP (BUROW'S TRIANGLE) AFTER NEOADJUVANCE IN UPPER QUADRANT TUMORS OF THE BREAST

Uso de retalho dermoglandular (triângulo de Burow) pós neoadjuvância em tumores do quadrante superior da mama

Paula Stephanie Duarte Oliveira^{1*}, André Vallejo da Silva¹, Douglas de Miranda Pires², Tayra Dall'oglio Hoffman¹, Luciana Jandre Boechat Alves¹

ABSTRACT

Mastectomy has been, in the past, the first treatment of choice for locally advanced breast tumors, especially when the neoadjuvant response is partial, and the tumor's location doesn't allow an aesthetic outcome when using usual quadrantectomy. Oncoplastic techniques are good solutions for these tumors allowing to resect big areas, removing the whole tumor and preserving breast symmetry. This case describes a dermoglandular flap technique to be used in advanced upper quadrant tumors in post neoadjuvance patients.

KEYWORDS: Breast reconstruction; Mammoplasty; Neoadjuvant therapy; Breast cancer; Surgical flap.

RESUMO

A mastectomia foi, no passado, o tratamento de escolha para tumores localmente avançados da mama, especialmente quando a resposta neoadjuvante é parcial e a localização tumoral não permite um bom resultado estético usando como técnica a quadrantectomia. Técnicas oncoplásticas são ótimas opções para esses tumores, uma vez que se ressecam grandes áreas, removendo todo o tumor e preservando a simetria mamária. Este caso descreve uma técnica de retalho dermoglandular a ser usado em tumores do quadrante superior em uma paciente pós-neoadjuvância.

PALAVRAS-CHAVE: reconstrução da mama; mamoplastia; terapia neoadjuvante; câncer de mama; retalhos cirúrgicos.

Study carried out at Hospital Universitário Antônio Pedro – Niterói (RJ), Brazil.

¹Hospital Universitário Antônio Pedro – Niterói (RJ), Brazil.

²Santa Casa de Belo Horizonte – Belo Horizonte (MG), Brazil.

*Corresponding author: paula.stp@hotmail.com

Received on: 01/08/2018. Accepted on: 02/05/2018

INTRODUCTION

Neoadjuvant systemic treatment has been the choice for locally advanced tumors as an attempt to improve surgical options and decrease the necessity of mastectomies without reducing the oncological benefit¹.

The reconstruction of partial defects of the breast in the upper quadrants took Grisotti and Calabrese to describe the area as a "no man's land". The use of dermoglandular flaps is a good oncoplastic choice to maintain breast symmetry without the need to operate the opposite breast. The Burow's triangle flap is indicated for tumors of upper medial quadrants and union of upper quadrants².

This case report shows the combination of oncoplastic techniques in a locally advanced tumor after neoadjuvant therapy and whose response was not satisfactory to obtain oncological and esthetics benefits.

CASE REPORT

R.B.M., 35 years old, black, without comorbidities, came to the mastology service of Antonio Pedro University Hospital in August 2016 with a five-centimeter tumor in the union of upper quadrants of the right breast, with an evolution of one year and core biopsy showing a ductal invasive carcinoma (T2N0M0). The patient was referred to a neoadjuvant systemic treatment, where she had six sessions of FAC (Fluorouracil, Adriamycin and Cyclophosphamide) with partial pathological response.

In February 2017, there was still some palpable mass, very close to the skin, of about 2-3 centimeters. She was, then, submitted to a breast conservation surgery with resection of the tumor and the skin above, complemented by a dermoglandular rotation flap, the Burow's triangle (Figures 1, 2 and 3). The tissue removed showed a 2,5x2,5x2,5-cm tumor with free margins and eight negative lymph nodes.

DISCUSSION

The use of primary systemic treatment or neoadjuvant systemic treatment (NST) has been accepted as the treatment of choice for patients with locally advanced disease. It is usually used in breast cancer patients with three purposes: to improve surgical options (several randomized trials have shown tumor's down-stage and decreased number of mastectomies), to obtain information on response (early response after two or three cycles of chemotherapy has been shown to be a predictor of pathological complete remission and might, therefore, serve as a predictor of long-term outcome) and to obtain long-term disease-free survival (absence of all viable tumor tissue is considered to predict the complete eradication of distant micro metastatic residual diseases)².

Several studies in early tumors, has showed no significant difference in survival when conservative surgery is chosen over a radical approach. Van Dongen et al. showed no difference in 10-year follow ups of tumors of up to five centimeters in overall survivor and distant metastasis free-survival³. Locally advanced tumors are still a controversial subject. Larger tumors require larger resections which can affect breast symmetry and often leads to a mastectomy, especially when the tumor is located in the upper quadrants, where defects are more difficult to repair.

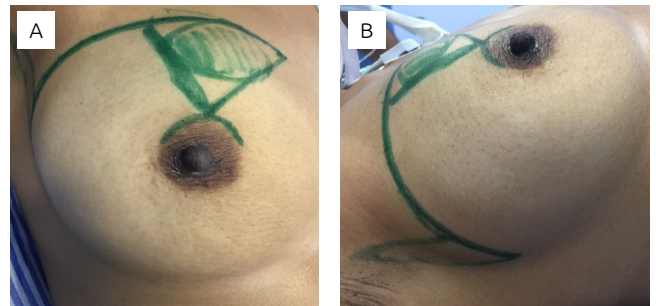


Figure 1. Breast tumor and Burow's triangle draw.

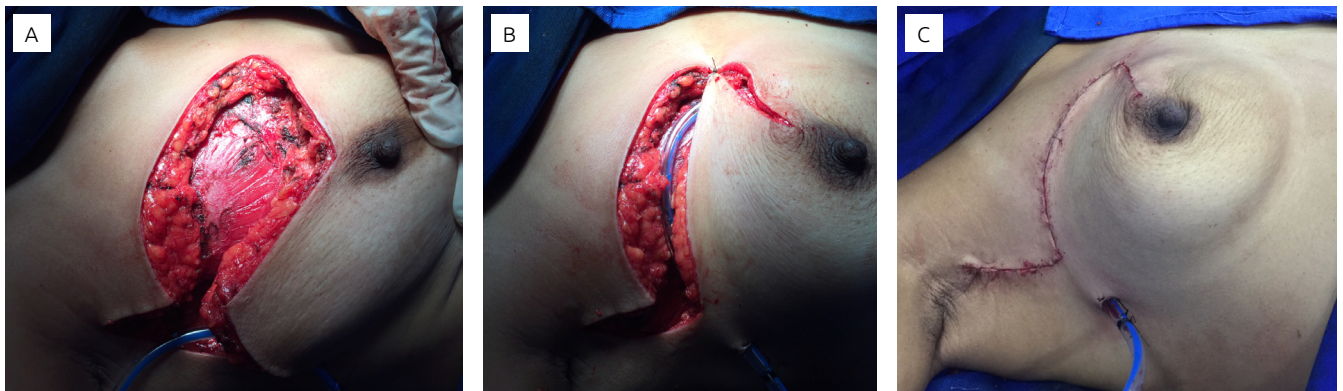


Figure 2. Sequence: defect after tumor and skin resection; replacement of the tissue and closure; defect closed after tissue displacement.

Oncoplastic techniques have been growing bigger in mastology the past few years and shown as an alternative to mastectomies in larger tumors. It applies reconstructive techniques for wider excisions to remodel the breast and maintain its symmetry⁴. It allows wider resections with wider negative margins and better aesthetic satisfaction⁵.

Rietjens showed that there was no difference in the disease's outcomes when using oncoplastic techniques after 74 months of follow-up⁶. Also, other papers demonstrated no difference in overall survivor, loco-regional recurrence and quality of life using oncoplastic techniques and reinforced the fact that it is possible to take away more tissue than usual without losing breast symmetry⁷.

Broecker and Regano used patients submitted to neoadjuvant therapies and oncoplastic techniques and compared prognostic factors. In both cases, there was more indication of conservative surgery with no increase in positive margins, re-excisions and ipsilateral recurrence. Regano et al.⁸ displayed better aesthetics satisfaction and Broecker et al. showed no difference between disease specific survival and completion mastectomy rate in five years⁹. These studies demonstrate oncoplastic surgery safety after neoadjuvant therapy.

Breast cancer treatment requires a multidisciplinary approach and evaluation of patients' expectancies. An immediate reconstruction allows for anatomy maintenance, preserving the inframammary fold and more of the breast's native tissue¹⁰.

Immediate reconstructions using tissues rearrangements have less complications and better aesthetic results than those using larger flaps such as the dorsal one¹¹.

The Burow's operation was first described in the early nineteenth century to facilitate the movement of flaps. The Burow's wedge/triangle flap is a surgical maneuver used to close triangular defects¹². It has been widely used to close facial defects. The tumor is resected from a primary triangle and the tissues from the areas beyond the sides of the wound are mobilized to close the primary defect.

When used to repair upper breast tumor resection defects, the tissue displacement area provides good axillary approach with no need for a secondary incision.

Although the use of Burow's technique is great to correct upper tumor defects after resections of the tumor and the skin above, it can displace the nipple and areola. Thus, using this technique assumes comparison with the contralateral breast and, if necessary, repositioning the areola about 1 centimeter in the opposite direction of the resection.

This technique has many variants and can be of great use in patients with upper quadrant tumors, who want to maintain the breast's aspect and symmetry and have no desire of operating the contralateral breast. The only negative point of this operation is the scar, which is large and can disturb some patients.

Oncoplastic techniques can greatly enhance the number of options in breast cancer surgery, avoiding the old quadrantectomy-mastectomy rule and offering patients new perspectives. The greatest reason for a patient to choose mastectomy without reconstruction is their fear of cancer recurrence. The best antidote to this fear is to offer good conservative options that are both safe and cosmetically sound¹³.

CONCLUSION

Breast cancer therapy requires a multidisciplinary approach, especially when it comes to locally advanced tumors. Neoadjuvant systemic therapy has been shown as the treatment of choice for these patients, once that it helps to predict a tumor's prognosis and allows better surgical options once the tumor is downstaged.

Surgical options, once we use oncoplastic techniques, are safer and more aesthetic, since they allow greater tissue removal and better margins while maintaining breast symmetry¹⁴.

In this scenario, we can reduce mastectomy rates in locally advanced tumors, offering patients better results without jeopardizing oncological safety. In order to do so, training in oncoplastic surgery is necessary, so that better surgical techniques can be applied and aesthetic results can be maintained without reducing quality of life and local control, optimizing operative time, and reducing adverse effects and costs¹⁵.

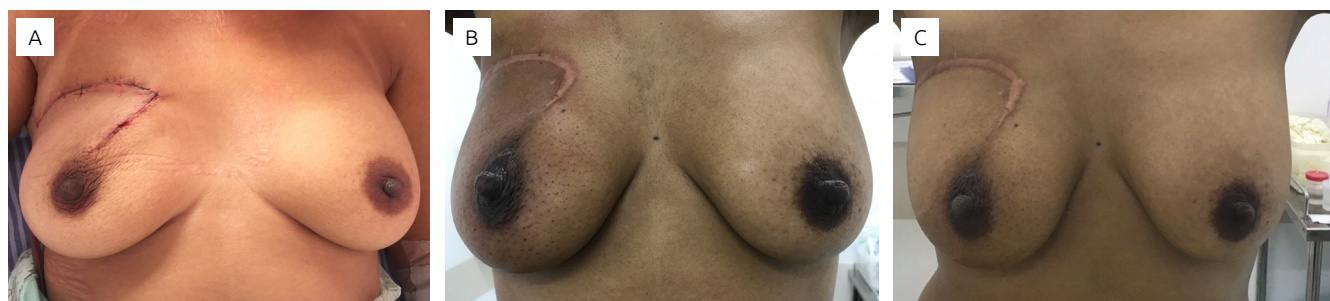

Figure 3. Sequency: first day after the procedure; one month after the procedure; six months after the procedure.

REFERENCES

1. Kaufmann M, Hortobagyi GN, Goldhirsch A, Scholl S, Makris A, Valagussa P, et al. Recommendations from an international expert panel on the use of neoadjuvant (primary) systemic treatment of operable breast cancer: an update. *J Clin Oncol*. 2006;24:1940-9.
2. Lucena CEM, Paulinelli RR, Pedrini JL. *Oncoplastia e reconstrução mamária*. Rio de Janeiro: Medbook; 2017.
3. van Dongen JA, Bartelink H, Fentiman IS, Lerut T, Mignolet F, Olthuis G, et al. Factors influencing local relapse and survival and results of salvage treatment after breast-conserving therapy in operable breast cancer: EORTC trial 10801, breast conservation compared with mastectomy in TNM stage I and II breast cancer. *Eur J Cancer*. 1992;28(4-5):801-5. [https://doi.org/10.1016/0959-8049\(92\)90118-L](https://doi.org/10.1016/0959-8049(92)90118-L)
4. Clough KB, Kaufman GJ, Nos C, Buccimazza I, Sarfati IM. Improving breast cancer surgery: a classification and quadrant per quadrant atlas for oncoplastic surgery. *Ann Surg Oncol*. 2010;17:1375-91. <https://doi.org/10.1245/s10434-009-0792-y>
5. Losken A, Dugal CS, Styblo TM, Carlson GW. A meta-analysis comparing breast conservation therapy alone to the oncoplastic technique. *Ann Plast Surg*. 2014;72(2):145-9. <https://doi.org/10.1097/SAP.0b013e3182605598>
6. Rietjens M, Urban CA, Rey PC, Mazzarol G, Maisonneuve P, Garusi C, et al. Long-term oncologic results of breast conservation treatment with oncoplastic surgery. *Breast*. 2007;16(4):387-95. <https://doi.org/10.1016/j.breast.2007.01.008>
7. Bogusevicius A, Cepulienė D, Sepetauskiene E. The integrated evaluation of the results of oncoplastic surgery for locally advanced breast cancer. *Breast J*. 2014;20:53-60. DOI: 10.1111/tbj.12222
8. Regano S, Hernanz F, Ortega E, Redondo-Figuero C, Gómez-Fleitas M. Oncoplastic techniques extend breast-conserving surgery to patients with neoadjuvant chemotherapy response unfit for conventional techniques. *World J Surg*. 2009;33:2082-6. <https://doi.org/10.1007/s00268-009-0152-x>
9. Broecker JS, Hart AM, Styblo TM, Losken A. Neoadjuvant therapy combined with oncoplastic reduction for high-stage breast cancer patients. *Ann Plast Surg*. 2017 Jun;78(6S Suppl 5):S258-62. <https://doi.org/10.1097/SAP.0000000000001062>
10. Cordeiro PG. Breast reconstruction after surgery for breast cancer. *N Engl J Med*. 2008;359:1590-601. <https://doi.org/10.1056/NEJMct0802899>
11. Kronowitz SJ, Feledy JA, Hunt KK, Kuerer HM, Youssef A, Koutz CA, et al. Determining the optimal approach to breast reconstruction after partial mastectomy. *Plast Reconstr Surg*. 2006;117:1-11; discussion 12-4.
12. Gormley DE. A brief analysis of the Burow's wedge/triangle principle. *J Dermatol Surg Oncol*. 1985;11(2):121-3.
13. Nold RJ, Beamer RL, Helmer SD, McBoyle MF. Factors influencing a woman's choice to undergo breast-conserving surgery versus modified radical mastectomy. *Am J Surg*. 2000;180:413-8.
14. Figueiredo CL, Pires DM, Mendonça ACG, Valadares CN, Andrade RL, Urban CA. Locoregional Flaps in Oncoplastic Surgery and Breast Reconstruction. *Mastology*. 2017;27(2):135-43. DOI: 10.5327/Z2594539420170000184
15. Pires DM, Gazoto Junior O, Valadares CN, Andrade RL. Training in oncoplastic and reconstructive breast surgery: analysis of training in America and in the European Union with the Brazilian reality. *Mastology*. 2017;27(2):164-71. DOI: 10.5327/Z2594539420170000185