

NIPPLE AREOLAR RECONSTRUCTION: TECHNIQUES TO ACHIEVE A GOOD RESULT

Reconstrução do complexo aréolo papilar:
técnicas para atingir um resultado satisfatório

Priscilla Sodré^{1*}, Juan Sebastian Sanches Tobar¹, Roberto Vieira¹, Carlos Ricardo Chagas¹

ABSTRACT

The nipple-areolar complex (NAC) reconstruction is the final touch in the reconstructive breast surgery, and it is very important for the patient's psychological health and satisfaction. There are many described techniques, but the main issue is to maintain the NAC projection over the time. The local graft reconstruction together with tattooing are the most popular techniques. However, it is important to personalize the method taking into account the patient's characteristics and the breast mound reconstruction to achieve good results. This article describes the reconstruction planning method, nipple and areolar reconstruction techniques using nipple sharing, local and autologous grafts and tattooing.

KEYWORDS: Nipple; mammoplasty; allografts; tattooing.

RESUMO

A reconstrução do complexo aréolo-papilar (CAP) é o toque final da cirurgia de reconstrução mamária sendo parte importante na satisfação e saúde psicológica da paciente. Existem várias técnicas descritas, porém o maior desafio é a manutenção da projeção do mamilo ao longo do tempo. As técnicas mais utilizadas são as que utilizam enxertos locais com posterior tatuagem. Entretanto, é importante a individualização do tratamento, a técnica escolhida deve levar em consideração as características da paciente e da mama reconstruída para que o resultado final seja satisfatório. O presente artigo descreve método de planejamento, técnicas de reconstrução da aréola e do mamilo utilizando enxertos de retalho local, autólogo ou do mamilo contralateral e tatuagem.

PALAVRAS-CHAVE: Mamilo; mamoplastia; aloenxertos; tatuagem.

Studied carried out at Pontifícia Universidade Católica – Rio de Janeiro (RJ), Brazil.

¹Department of Mastology, Postgraduate Medical School, Pontifícia Universidade Católica do Rio de Janeiro – Rio de Janeiro (RJ), Brazil.

***Corresponding author:** pri.freitas@uol.com.br

Conflict of interests: nothing to declare.

Received on: 07/25/2017. **Accepted on:** 02/13/2018.

INTRODUCTION

The nipple-areolar complex (NAC) gives personality to the breast and, therefore, transforms a reconstructed mound into a breast. It has symbolic and aesthetic meanings. Patients with loss of NAC from cancer excision, posttraumatic events, developmental pathology and breast surgery complications experience major psychological distress. NAC reconstruction is an important and integral part of breast reconstruction and can provide significant psychosocial benefits to women.

There are many techniques described for NAC reconstruction. The goal is to create a symmetric nipple-areola complex that matches the contralateral nipple in size, color, position and projection, giving it a pleasing and natural appearance¹.

Since the Adams' initial description, in the 1940s, of labial graft and nipple-areola graft, the evolution of NAC creation began². The aim was to provide a tissue with projection. Lots of different grafts were used, like toe pulp, auricular cartilage, but the donor site morbidity was a problem³. In 1972, Millard, using a graft from the contralateral nipple, introduced the nipple-sharing concept⁴. The big evolution in the NAC reconstruction occurred in the 1980s, with quadropod flap, dermal fat flap, and T-flap descriptions^{5,6}. Using the same principle, including skin grafts or not, lots of different techniques were described, including skate flap, star flap, CV flap, Bell flap, and the S-flap.

In 1986, Becker started to use the tattooing technique for NAC reconstruction, and was followed by Spear, who spread the technique. Nowadays, the high quality and several tones of pigment give it a very similar color to the original areola. Although the color match can be good, the texture and projection are lacking. Fat grafts, dermal fillers and acellular dermal matrix can be used to create better areola definition.

There is no better technique to reconstruct NAC. Each method has its own advantage and limitations, and a combination of different methods is a good choice. The most challenging problem is to maintain a satisfactory result for a long period of time. Nipple projection is most durable when the dermis of the flap is thick, and there is adequate subcutaneous tissue to reinforce the volume of the reconstructed nipple. Currently, we can also use fat grafting or dermal graft to augment an inadequate flap donor site before the definitive nipple reconstruction. Cylinders made from a naturally derived biomaterial combined with local flaps surgical techniques are an alternative for nipple reconstruction⁷. The decision between different methods depends on the anatomical local conditions (scars, subcutaneous tissue volume, dermis thickness, radiotherapy) and on surgeon and patient preferences.

NIPPLE-AREOLAR RECONSTRUCTION PLANNING

Some considerations are important during the nipple-areolar reconstruction planning:

- timing: most people consider that approximately 3-5 months after reconstructive surgery is the ideal waiting time, allowing the breast position to settle as swelling resolves and gravity exerts its effect^{1,8}. However, immediate NAC reconstruction can be performed in a patient undergoing prophylactic mastectomies with free nipple grafting when mastopexy is required. The NAC must be placed approximately 1cm medial to the midbreast line. Otherwise, they can drift laterally in the post-operative period⁹;
- positioning: specific landmarks can help to determine the NAC position: the level of nipple areola, the triangle with the sternal notch and the umbilicus, and the nipple-areolar position relative to each breast and the infra mammary fold. Measurements are useful to confirm the visual NAC position, but the most important item is that is simply "looks right". To help with the surgeon and patient's decision, an adhesive circle of a diameter similar to the opposite NAC can be placed in the reconstructed breast to check for the best position⁹. When the reconstruction is bilateral, the surgeon must use standard values to create nipple position, size, and areola size. A review of 600 breasts showed that the mean diameter of the areola is approximately 4 cm, with average nipple diameter being 1.3 cm and the average nipple projection of 0.9 cm¹⁰. The average nipple-areola and areola-breast proportion is of approximately 1.3 cm¹¹;
- breast reconstruction technique: The loss of projection of the nipple is the big issue in its reconstruction. When the dermis is thin and there is less subcutaneous fat present, there is a great risk of nipple projection loss. Latissimus dorsi flap is the most adequate flap width, followed by less thick skin of the abdomen, and finally by the thinnest skin of the expanded mastectomy skin flap. With these issues in mind to prevent loss projection, overcorrection of 25–50% of the desired result is advised in NAC reconstruction with local flaps. Scarred areas must be avoided due to poor blood supply.

RECONSTRUCTION TECHNIQUES

Reconstruction of the nipple

Nowadays, surgical reconstruction is the most used method and involves the use of grafts or local flaps.

The grafts

The contralateral nipple sharing technique

The technique was initiated by Adams, in 1944, and described by Millard in 1972. It is an excellent choice for patients with excess contralateral nipple projection, after irradiation or tissue expansion reconstruction, in which flap procedures are contraindicated. The main advantages are the perfect matching regarding color,

texture and shape between the two nipples and the long-term nipple projection^{12,13}.

Women with average nipple length are usually more reluctant to accept this technique due to fear of contralateral surgery and the reduction of contralateral nipple sensation, although Zenn and Garofalo found that an overall patient satisfaction with the technique was 88 percent¹³.

The choice of donor site location depends on the nipple projection/diameter ratio. When nipple projection exceeds its diameter, sharing can be performed by “decapitation”; nipple donor tissue is removed transversely at the level of three fifths of the opposite nipple, and a small conic biopsy specimen is taken from the remaining ducts. The donor site is closed using a 6–0 absorbable purse string suture.

When the diameter of the nipple exceeds its height, the “vertical bipartition” is indicated; the lower half of donor nipple is marked to be folded down for donor site closure. The receptor nipple site is thinly de-epithelized using a number 15 blade. A number 11 blade is placed through the base of the nipple until its half, and then pulled upward, dividing the nipple. A small conic biopsy specimen is taken from the remaining ducts. The lower free graft is immediately placed over the de-epithelized receptor area. The center is attached to the recipient bed by a 6–0 monocryl single suture, and the periphery is closed with 5–0 multiples sutures. Non-adherent dressing and multiple Steri-Strips are used to close the area. The donor site is closed by simple approximation⁸ (Figure 1).

Other Grafts

Earlobe, labia minora and toe pulp are options when contralateral nipple is unavailable. They are considered “salvage full thickness grafts”. Some authors have good experiences with them¹⁴, but most think they are associated with significant donor area morbidity⁹.

Local Flaps

Local flaps are currently the most commonly used techniques. The flaps can be divided, according to its design, in subdermal pedicle local flaps, such as skate flap, C-V flap, star flap,

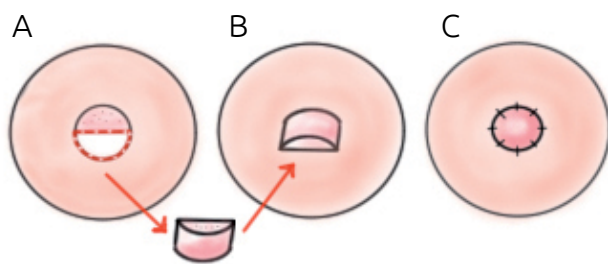


Figure 1. Contralateral nipple sharing technique by “vertical bipartition”.

twin flap and centered-based local flaps, like quadrapod flap, H flap, tripod flap, mushroom flap, and the Maltesse cross flap. The main problem of these techniques is the postoperative volume loss. For this reason, many authors have advised creating a nipple that is up to twice the size of the ultimately desired volume^{15,16}.

The loss of projection and volume mainly occurs because of the retraction forces of surrounding and underlying tissues, besides tissue contraction of the flap. Centered-based flaps suffer the greatest retraction forces, which act on the entire basis of the flap. Shrinking occurs to a variable degree, in all kinds of flaps. Blood supply is also a very important determinant of flap contraction, the rich subdermal plexus provides better blood supply to a subdermal pedicle flaps comparing with central pedicle flaps.

Over the years, with better understanding of local flap healing, the technique’s evolution was addressed to improving blood supply, minimizing retraction forces by simplifying flap design and by rejecting centered-based flap techniques. Enhanced vascularization was achieved by widening the subdermal pedicle base and developing double-pedicle flaps.

Skate Flap

The skate flap nipple reconstruction was described by Little in 1984. It provides good nipple projection, diameter and definition. It uses most of the skin removed to place the areola graft¹⁷. The wings of the skate flap blood supply come from a well-vascularized subcutaneous pedicle. Women with compromised microcirculation, like heavy smokers or with irradiated breast skin are not very good candidates for this method.

This procedure reconstructs the areola and nipple. So, a circle that is equal in diameter to the contralateral areola is drawn at the NAC future site (Figure 2A). The upper third of this circle is delineated as a separate de-epithelialization, the skin is discharged. The lower two thirds will be elevated as lateral and medial wings based in the center, as an attached vascularized pedicle within the center of the circle (Figure 2B). It is

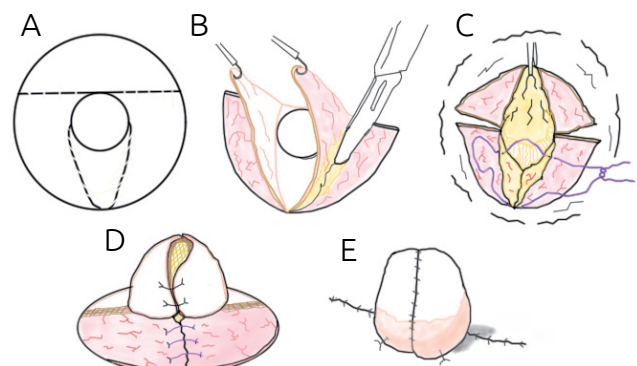


Figure 2. Skate flap nipple reconstruction technique.

important to provide good blood supply for the flap. The proper placement of the future nipple is determined and a 50% longer nipple projection is estimated, assuming that it will shrink to perfect symmetry. The wings of the skate flap are de-epithelialized to the proposed width of the skate flap, and then a cut through the dermis into the subcutaneous is made. This tissue is lifted up, and the wings of the flap are brought around (Figures 2B and 2C). The nipple is sutured vertically; the subcutaneous donor area is re-approximated (Figures 2D and 2E). The areolar graft can be taken from the excess tissue on the lateral portion of the mastectomy. A silicone sheet is applied to stabilize the graft, and a 10 mL syringe nipple protector is taped over the sheet for additional protection. Normally, tattooing is required and should be performed a few months later, when the nipple becomes pale.

C-V Flap

The C-V Flap evolved from the skate flap; it is a very popular technique, which allows a medium to moderated-size nipple reconstruction with no need for an areolar graft.

After deciding the right place for the nipple, the C-V flap is designed based on the site and diameter planned for the reconstructed nipple. The diameter of the C flap will be the final nipple diameter, the height of the nipple will be correspondent to the width of the V flap, and the length of the two V flaps will correspond to the perimeter of the new nipple (Figure 3A).

Incisions are made around the two Vs and C flap. It's very important not to divide the base of the flap and leave the subdermal plexus intact to guarantee the flap's blood supply.

The two V flaps are separated from the underlying subcutaneous tissue. The flaps are thinner toward their periphery than centrally, to prevent necrosis of the tips. The C flap are also thinned, the central subcutaneous area are preserved to maintain a good blood supply for the reconstructed nipple (Figure 3B).

The initial closure involves 4-0 monocryl suture to the donor base of the C flap to the base of the V flap on both sides. The C-V flaps are positioned. The first suture secures the lowest point of the two V flaps to the center portion of the C flap's original site. The suture locks in the V flaps, and, after that, the new nipple's vertical portion is reconstructed. The tips of the V flaps are removed, their ends are sutured and the height of the nipple is reconstructed. The C flap is sutured to the upper portion of the V flaps by a single suture that grasps the tip of one V

flap in a horizontal mattress suture, (Donati), in the C flap, and goes through the other V flap. Then, the C flap is placed down onto the vertical walls of the V flap to form a cap. The donor skin is closed using a 5-0 plain catgut suture to prevent the need for suture removal (Figure 3C).

The wound dress is made with steri-trips to support the skin closure and with a nipple protector made from the back-end of a 10ml syringe barrel. This cylinder is important to prevent nipple compression by the patient's bra or clothes. Tattooing can be performed after 4-6 weeks⁹.

Modified C-V flap with a dermal shelf for nipple support

This technique was developed by Jones⁹ to prevent the retraction of the nipple, particularly in TRAM flaps, where soft fat forms the base of the nipple.

The creation of the de-epithelialized inferior dermal shelf by raising the C flap component that slides underneath the nipple at the time of donor site closure provides support to the reconstructed nipple and prevents its retrusion.

Areolar reconstruction

Skin grafts, tattooing, purse string or a combination of these techniques can be used to reconstruct the areola. The objective and the challenge are to recreate the texture and the pigmentation of the native areola. Skin graft is usually performed at the time of nipple reconstruction. Traditionally, tattooing is performed 2-6 months after the surgical reconstruction, but some authors have shown very good results with simultaneous procedures¹⁸⁻²⁰.

Skin grafts

Many sites can be used as donor areas: skin adjacent to mastectomy scar ("dog ear"), retro auricular skin, contralateral areola and upper inner thigh. The latter became more unpopular because of donor site pain, loss of pigment over time, especially in post-menopausal women, and the possibility of hair growth on the reconstructed areola. However, upper inner thigh graft is still a good choice depending on skin color and hair growth pattern. Retro auricular graft is used solely on specific cases, when the areola is light pink. The most popular donor area for areolar reconstruction is lateral mastectomy scar, dog-ear or the lateral donor scar of the TRAM flap. However, intradermal tattoo will be necessary to provide the appropriate color⁹.

Donor site must be marked as an ellipse to facilitate closure. The diameter of the circle must be larger than the recipient area diameter, normally between 30-45 mm. The donor site is then closed in layers with 3/0 vicryl and 4/0 monocryl. The graft is thinned and, when necessary, all hair roots are removed using magnification loupes. The graft is transferred to the previous de-epithelialized new areolar site and is

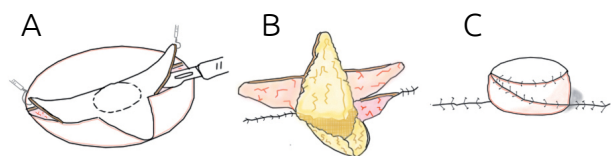


Figure 3. C-V flap nipple reconstruction technique.

secured with interrupted sutures of 4/0 nylon and a running subcuticular suture of 5/0 monocril placed on the outer circumference of the areola. A hole is fashioned in the middle of the skin graft to allow the previously created nipple projection to be pulled through, creating a three-dimensional nipple complex^{9,21}.

Purse string suture technique

In this new technique, described by Caterson et al.²², a purse-string suture with non-absorbable suture thread is used to create areolar projection, while reducing tension on the base of the newly created nipple. Despite the small series of ten patients and the short one-year follow-up, it is a promising method to provide long-term areolar projection.

The procedure is performed under local anesthesia, about 3 months after breast reconstruction and simultaneously with nipple reconstruction. After having decided the areolar diameter, 12–15 small curvilinear (around 2 mm each) skin incisions are evenly (about 8 mm) spaced approximately 5 mm outside the desired areola diameter with an 11 blade scalpel. A double-armed 2-0 Ethibond/GoreTex or Prolene suture is then placed in either direction, through the previously created skin incisions, starting at the 12-o'clock position (Figure 4A). This is maintained relatively deep to prevent suture spitting or showing through the skin. The purse-string suture is completed at the meeting of both ends at the 6-o'clock position. The areola diameter is then cinched down to the desired measurement, thereby elevating the areola and reducing tension on the base of the nipple creation by countering the radial pull of the surrounding tissue. The curvilinear incisions are closed with 6-0 chromic sutures (Figure 4B). The NAC tattooing is performed 2 months after the purse string procedure²².

Tattooing

Tattooing can be associated with other techniques to improve the outcome, providing the right color and shape to the reconstructed NAC. Some patients prefer this method alone, since they want the quickest, painfulness NAC reconstruction technique. Although color match and shape can be good, it lacks in

texture and projection. Nevertheless, nowadays, with 3D techniques, using principles of light and shadow to create depth on a two-dimensional surface, some tattoo artists can reproduce incredibly realistic nipple areolar complexes²³.

Pigment fading was the most common long-term complaint, voiced by up to 60%. After a few required touch-ups, the majority were satisfied with their outcome. Tattoo colors may be selected a bit darker to compensate the predictable changes that will occur²⁴⁻²⁶. The right technique is also very important. Pigment placed superficially will result in its extrusion and sloughing, and, if placed too deep, it will lead to macrophage ink phagocytosis, both resulting in early pigment fading²⁵. Tattooing equipment can be regulated to ensure the right needle depth in the dermis.

POST OPERATIVE CARE

It is very important to avoid direct pressure on the surgical site. A petroleum jelly and antibiotic ointment dressing with a circular hole cut in the center can be used to dress the wound. Some authors recommend a nipple protector made from the base of a 10 ml syringe cut with a battery-powered cautery device to provide additional nipple protection¹⁴. A standard maternity plastic nipple shield or a plastic medicine cup can be used for the same purpose. The dress should be changed often and maintained for at least two weeks after reconstruction. Hot tubs or baths must be avoided for 6–8 weeks. For patients with a graft/reconstructed areola, it is recommended to cover the areola and the nipple with petroleum jelly and antibiotic ointment dressing, and tape it securely. Wearing an appropriately fitting non-compressing bra is also advised²⁷. Postoperative care tattooing includes dressing with non-adhesive paraffin gauze or antibiotic ointment to keep the area moistened. With desiccation, there may be a loss of pigmentation.

CONCLUSION

There are many methods described to reconstruct the NAC and many more will be described. There are very few evidence-based studies comparing the different established methods to reconstruct the NAC, so it is difficult to conclude what the best method is. Over time, techniques have evolved and nowadays trained surgeons are able to provide long-lasting, satisfactory reconstruction with minimal morbidity. Together with expertise in the surgical technique, it is extremely important to know the patient's expectations, analyze the technical possibilities and share these possibilities and complications with the patient to decide, together, which is the best technique to be used. When the physician-patient relationship is strong, it is easier to achieve a satisfactory outcome.

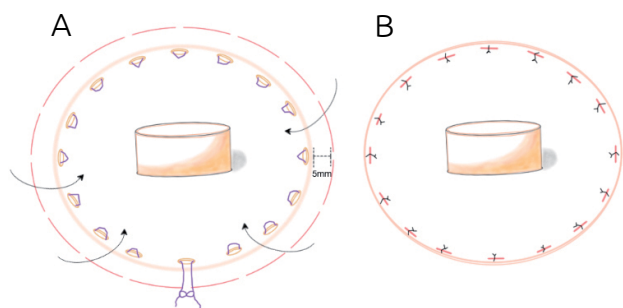


Figure 4. Purse string suture technique to create areolar projection.

REFERENCES

1. Nimboriboonporn A, Chuthapisith S. Nipple-Areola Complex Reconstruction. *Gland Surg.* 2014;3(1):35-42. <https://doi.org/10.3978/j.issn.2227-684X.2014.02.06>
2. Adams WM. Free transplantation of the nipples and areola. *Surgery.* 1944;15:186.
3. Klatsky SA, Manson PN. Toe pulp free grafts in nipple reconstruction. *Plast Reconstr Surg.* 1981;68:245-8.
4. Millard DR. Jr. Nipple and areola reconstruction by split-skin graft from the normal side. *Plast Reconstr Surg.* 1972;50:350-3.
5. Hartrampf CR Jr, Culbertson JH. A dermal-fat flap for nipple reconstruction. *Plast Reconstr Surg.* 1984;73:982-6.
6. Losken A, Mackay GJ, Bostwick J. Nipple reconstruction using the C-V flap technique: along term evaluation. *Plast Reconstr Surg.* 2001;108:361-9.
7. Tierney BP, Hodde JP, Changkuon DI. Biologic Collagen Cylinder with Skate Flap Technique for Nipple Reconstruction. *Plast Surg Int.* 2014;2014:ID 194087. <http://dx.doi.org/10.1155/2014/194087>
8. Nahabedian MY. Nipple reconstruction. *Clin Plast Surg.* 2007;34:131-7. <https://doi.org/10.1016/j.cps.2006.11.009>
9. Jones GE. *Bostwick's Plastic & Reconstructive Breast Surgery.* 3^a ed. St. Louis, Missouri: Quality Medical Publishing; 2010.
10. Sanuki J, Fukuma E, Uchida Y. Morphologic study of nipple-areola complex in 600 breasts. *Aesthetic Plast Surg.* 2009;33:295-7. <https://doi.org/10.1007/s00266-008-9194-y>
11. Hauben DJ, Adler N, Silfen R, Regev D. Breast-areola-nipple proportion. *Ann Plast Surg.* 2003;50:510-3. <https://doi.org/10.1097/01.SAP.0000044145.34573.F0>
12. Zenn MR, Garofalo JA. Unilateral nipple reconstruction with nipple sharing: time for a second look. *Plast Reconstr Surg.* 2009 Jun;123(6):1648-53. <https://doi.org/10.1097/PRS.0b013e3181a3f2f9>
13. Adams WM. Free transplantation of the nipples and areola. *Surgery.* 1944;15:186-95.
14. Farhadi J, Maksvytyte GK, Schaefer DJ, Pierer G, Scheufler O. Reconstruction of the nipple-areola complex: an update. *J Plast Reconstr Aesthet Surg.* 2006;59:40-53.
15. Little JW. Nipple-areolar reconstruction. In: Spear SL, editor. *Surgery of the Breast: Principles and Art.* Philadelphia: Lippincott-Raven Publisher; 1998.
16. Little III J. Nipple-areola reconstruction. *Clin Plast Surg.* 1984;11:351-64.
17. Vandeweyer E. Simultaneous nipple and areola reconstruction: a review of 50 cases. *Acta Chir Belg.* 2003;103:593-5.
18. Børsen-Koch M, Bille C, Thomsen JB. Promising results after single-stage reconstruction of the nipple and areola complex. *Dan Med J.* 2013;60(10):A4674.
19. Few JW, Marcus JR, Casas LA, Aitken ME, Redding J. Long-term predictable nipple projection following reconstruction. *Plast Reconstr Surg.* 1999 Oct;104(5):1321-4.
20. Van Laeken N, Genoway K. Nipple reconstruction using a two-step purse-string suture technique. *Can J Plast Surg.* 2011;19(2):56-9.
21. Caterson SA, Singh M, Talbot SG, Eriksson E. Reconstruction of Areolar Projection Using a Purse-String Suture Technique. *Plast Reconstr Surg.* 2015 [cited on Apr 26, 2016]. Available at: http://journals.lww.com/prsgo/Fulltext/2015/07000/Reconstruction_of_Areolar_Projection_Using_a.19.aspx
22. Garg G, Thami GP. Micropigmentation: tattooing for medical purposes. *Dermatol Surg.* 2005;31:928-31; discussion 931.
23. Halvorson EG, Cormican M, West ME, Myers V. Three-dimensional nipple-areola tattooing: a new technique with superior results *Plast Reconstr Surg.* 2014 May;133(5):1073-5. <https://doi.org/10.1097/PRS.0000000000000144>
24. Wong RK, Banducci DR, Feldman S, Kahler SH, Manders EK. Pre-reconstruction tattooing eliminates the need for skin grafting in nipple areolar reconstruction. *Plast Reconstr Surg.* 1993;92(3):547-9.
25. Spear SL, Arias J. Long-Term Experience with Nipple-Areola Tattooing. *Ann Plast Surg.* 1995 Sep;35(3).
26. Hyman J, Newman M, Gayle LB. Composite syringe dressing after nipple-areola reconstruction. *Plast Reconstr Surg.* 2005;116:340-1.