

PRIMARY LYMPH NODE HEMANGIOMA IN A PATIENT WITH INVASIVE DUCTAL CARCINOMA

Hemangioma linfonodal primário em paciente com carcinoma ductal invasivo

Andrey Biff Sarris¹, Thiago Matnei¹, Fernando Jose Leopoldino Fernandes Candido¹, Luiz Gustavo Rachid Fernandes¹, Sadi Martins Calil², Mário Rodrigues Montemor Netto¹

ABSTRACT

Primary lymph node hemangioma is a rare entity with only a few cases having been reported in the literature. This article describes a case of a 68-year-old female patient with breast cancer who underwent modified radical mastectomy with a subsequent histopathological evaluation that revealed invasive ductal carcinoma histological grade III according to Nottingham's Combined Classification. Among the 14 resected lymph nodes, the presence of vascular proliferation (intranodal) was observed in one of them, consistent with primary nodal hemangioma. Thus, knowledge about this clinical entity is important in order to establish the correct differential diagnosis with malignant primary neoplasms and metastasis, in which therapeutics and prognosis are very different.

KEYWORDS: Hemangioma; lymph node excision; breast neoplasms; breast ductal carcinoma.

RESUMO

Hemangioma linfonodal primário é uma entidade rara, sendo que poucos casos foram descritos na literatura. Neste artigo foi relatado o caso de uma paciente de 68 anos com neoplasia mamária à direita e que foi submetida à mastectomia radical modificada com posterior avaliação histopatológica, que evidenciou carcinoma ductal invasor de grau histológico III, conforme Classificação Combinada de Nottingham. Dentre os 14 linfonodos ressecados, foi observada em 1 deles a presença de proliferação vascular (intranodal) consistente com hemangioma nodal primário. Dessa forma, o reconhecimento dessa entidade clínica torna-se imprescindível para a realização de diagnóstico diferencial de neoplasias malignas primárias ou metastáticas, que apresentam terapêuticas e prognósticos totalmente distintos.

PALAVRAS-CHAVE: Hemangioma; excisão de linfonodo; neoplasias da mama; carcinoma ductal de mama.

Study carried out at Universidade Estadual de Ponta Grossa – Ponta Grossa (PR), Brazil.

¹Department of Medicine, Universidade Estadual de Ponta Grossa – Ponta Grossa (PR), Brazil.

²Instituto Sul Paranaense de Oncologia – Ponta Grossa (PR), Brazil.

*Corresponding author: andreybiff@hotmail.com

Conflict of interests: nothing to declare.

Received on: 08/21/2017. Accepted on: 12/13/2017

INTRODUCTION

Primary lymph node benign tumors are rare, and lymph node hemangiomas are even more uncommon, with no more than 60 cases described in the literature^{1,2}. Lymph node hemangiomas are benign vascular tumors or hamartomas characterized by the presence of vascular proliferation containing blood cells, varying in size, which alter the cytoarchitecture of the lymph node¹. An accurate diagnosis of lymph node hemangiomas is important to differentiate possible malignant tumors, which may manifest as lymph node metastases or primary malignant lymph node tumors, which require different therapeutics and prognosis². This subject becomes especially relevant when the tumor is located in lymph nodes derived from axillary dissection in the propaedeutic of mammary neoplasia, as described in this case.

CASE DESCRIPTION

A 68-year-old female patient, asymptomatic, with a mammary nodular neoplasm of the lower quadrant, positioned at “5 hours” with approximately 3 cm in diameter. Previous history indicated the presence of systemic arterial hypertension and five pregnancies, with four vaginal deliveries and one cesarean section, in addition to one abortion. Still in relation to the patient’s gynecological-obstetric history, menarche took place at age 13 and menopause at age 45. A nodulation of approximately 1 cm was observed in the right axillary region, in addition to the nodule described above, during physical examination. Mammary ultrasonography showed a macrolobulated nodular image in the right lower quadrant, positioned at “5” hours, measuring 13 x 12 x 11 mm, in the right breast — BI-RADS 4A. Follow-up was performed with core biopsy in the mammary nodule, which revealed an invasive ductal carcinoma, histological grade III, according to the Nottingham Combined Classification (poorly differentiated tumor). After immunohistochemical analysis, an estrogen- and progesterone- receptor-negative tumor was noticed, with Ki-67 rate at 90%. Analysis by fluorescence *in situ* hybridization (FISH) was inconclusive. Modified radical mastectomy with subsequent histopathological evaluation was the chosen method, with confirmation of invasive ductal carcinoma. The product of the right axillary dissection at primary level did not reveal presence of metastasis in the 31 resected lymph nodes. However, within these lymph nodes, the presence of vascular proliferation in the hilar and medullary intranodal region was observed in one of them, with blood cells inside (Figure 1). Given the histopathological evaluation, the intranodal finding corroborated the diagnosis of primary lymph node hemangioma (Figures 2 and 3). The patient continued their treatment of mammary carcinoma with chemo and radiotherapy, being considered cured of the nodal hemangioma due to resection.

DISCUSSION

Primary lymph node hemangioma affects a wide age range (4.5 to 75 years of age), predominantly females². The processes for the evaluation of sentinel lymph node and mammary axillary dissection, as well as lymph nodes generated from inferior genital resections, may contribute to the predominance of females, since their diagnosis is often incidental, as can be observed in this report. In some cases, there is a description of lymph node mass palpation, especially when the most superficial chains are affected. The reports mention tumors up to 35 mm²⁻⁵.

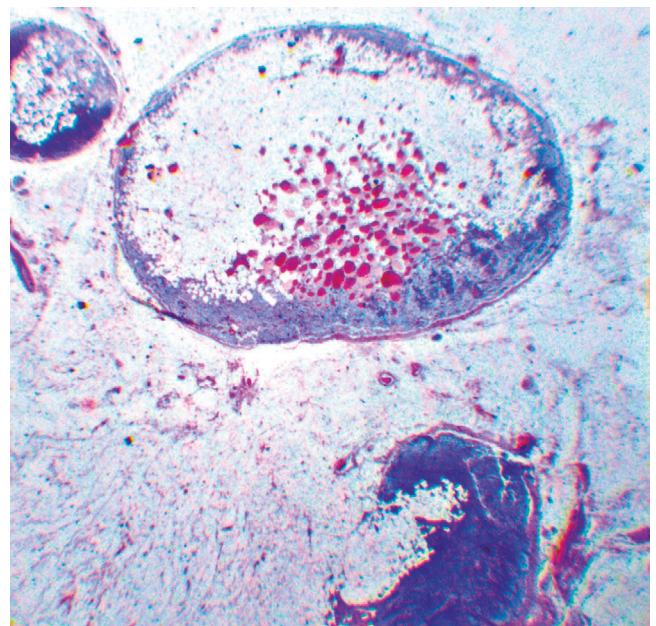


Figure 1. Lymph node (HE-4x magnification): Lymph node hemangioma — lymph node dissection with vascular proliferation in the medullary region.

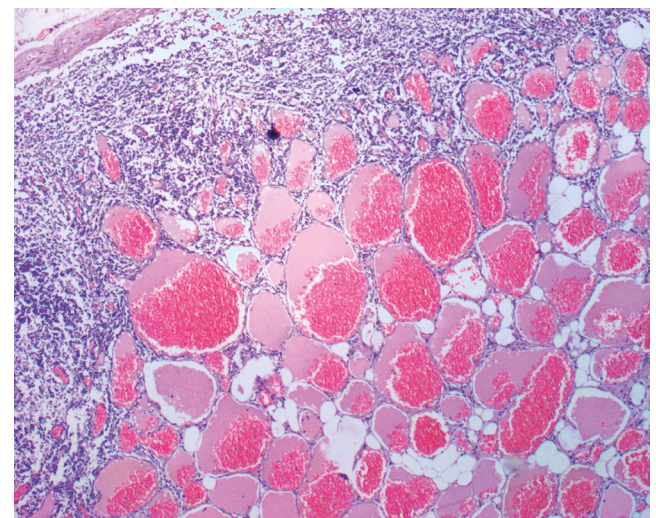


Figure 2. Lymph node (HE-40x magnification): Lymph node hemangioma — multiple proliferation of vessels with erythrocytes on the inside.

The pathophysiological mechanism of hemangiomas' formation in nodal sites is still uncertain³.

In general, the microscopic analysis does not contribute to diagnosis^{2,3,6}. Microscopically, hemangiomas may be divided into four histological types: capillary/cavernous, capillary lobular, cellular and epithelioid^{2,3,6}. Capillary/cavernous types are distinguished due to their greater involvement in the hilar or medullary region with preservation of the parenchyma. The differentiation degree may vary and the grouping of very close capillary or cavernous vessels, bounded by flat endothelial cells, with or without blood cells, may occur, as observed in this case. The capillary lobular subtype may occupy the entire parenchyma, acquiring the appearance of pyogenic granuloma. The cellular subtype, on the other hand, is consisted of extremely united cells, often with no channeling. Channeling may be marked by Schiff's periodic acid and reticulin stains. Finally, the epithelioid is characterized by large endothelial cells^{2,3,6}. In terms of immunohistochemistry, the endothelium of the four hemangioma subtypes is positive for the following markers: smooth muscle actin, CD31, CD34 and factor VIII-related antigen^{1,6}. The differentiation of hemangioma subtypes is basically at the discretion of microscopy, and the impact of this sub-differentiation on the prognosis of patients is uncertain¹.

Imaging scans are of little help in the diagnosis of nodal hemangioma, although they are extremely common in the prognosis of lymph node investigation⁷. The most classic presentation of hemangioma on axillary ultrasonography is a solid, well-delimited, hypoechoic mass with a multilobular margin. However, hemangioma may also present other echogenic aspects (hype or iso) and intranodal microcalcifications^{7,8}. In terms of vascularization, it is expected that few vessels with a single vascular pole are found. The presence of multiple poles and of intense vascularization draws attention to the differential diagnosis of malignancy⁷.

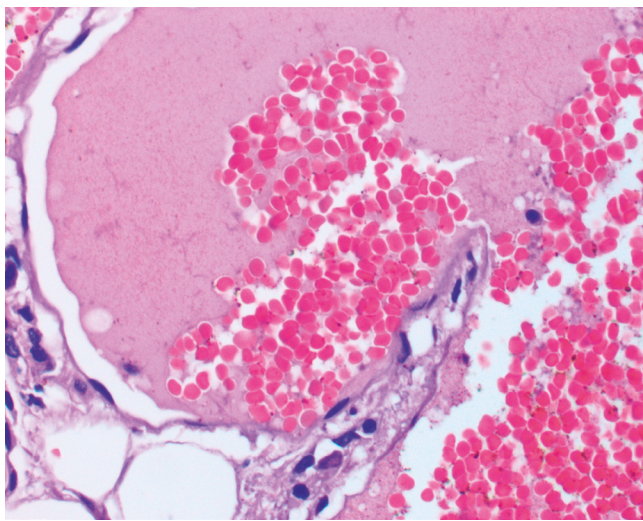


Figure 3. Lymph node (HE-400x magnification): Lymph node hemangioma — proliferation with endothelium without atypia and multiple erythrocytes.

Among the benign differential diagnoses of lymph node hemangioma, there are: bacillary angiomatosis, lymphangioma, angiomatous hamartoma and epithelioid hemangioendothelioma. Among the malignant ones, there are: compound hemangioendothelioma, polymorphic hemangioendothelioma, Kaposi's sarcoma and Dabska's tumor^{1,2,6}. Lymph node bacillary angiomatosis is more common in patients with human immunodeficiency virus/acquired immunodeficiency syndrome (HIV/AIDS) and is characterized by the presence, as the name suggests, of bacilli in the tumor region⁶. Nodal lymphangioma differs from the others, since it tends to affect several organs concomitantly to the lymph node and by the positivity of the D2-40 marker^{1,2,6}. Angiomastic hamartoma, on the other hand, was described only in the inguino-femoral region², although its existence has been reported in other locations, such as in the neck and in the popliteal area⁹. The histopathological characteristic is the formation of blood vessels, adipose, muscular and fibrotic tissues by the hilum, as well as lymph node parenchyma without the formation of fascicles. Epithelioid hemangioendothelioma is formed by strands of fusiform cells with nuclear pleomorphism and eosinophilic cytoplasm with vacuoles, with or without blood cells, inserted in a mixo-hyaline stroma^{1,2,6}.

Regarding malignancies, the hemangioendothelioma composite is a low-grade tumor with low metastatic capacity and a high possibility of local recurrence^{1,2,6}. The polymorphic hemangioendothelioma is a neoplasm with great potential for metastasis and recurrences. It is characterized by polygonal cells with oval nuclei and angiomatous areas, with more than 14 mitoses per increased large field. Like hemangioma, it also presents CD31, CD24 and positive factor VIII, but does not show epithelial markers, which allows to distinguish it. Angiosarcoma is characterized by irregular epithelium and with atypia, in general, as a secondary occurrence^{1,2,6}. Kaposi's sarcoma should always be considered in the differential diagnosis¹, being recognized by the proliferation of fusiform cells with slight atypia, forming vascular spaces, often with prominent mitoses and extravasation of hemosiderin cells. Lymph node Kaposi's sarcoma should be especially addressed in pediatric patients^{1,2,6}. Finally, Dabska's tumor, a low-grade angiosarcoma with metastasis potential, is marked by vascular anastomosis spaces with intravascular papillary projections and an atypical endothelial lumen^{1,2,6}.

Considering the large number of pathologies that can affect the lymph node and the difficulty of diagnosis exclusively through microscopy, the use of immunohistochemical analysis is necessary for the differentiation of lymph node hemangioma, especially in the context of neoplasia patients^{1,6}. In the diagnosis uncertainty of polymorphic hemangioendothelioma, such as in a malignant lymph node neoplasm, for example, immunohistochemistry is the means to make this distinction, through the negativity of epithelial markers^{2,6}.

Given the range of differential diagnoses, including aggressive neoplasms, surgical excision should occur in all patients with suspected hemangioma due to growth of lymph node mass^{1,3}. The treatment of primary lymph node hemangioma consists of surgical resection, which is considered curative^{2,3,6}. The prognosis is excellent and the recurrence of these tumors is not described in the literature¹.

CONCLUSION

Therefore, it can be concluded that the knowledge on primary lymph node hemangioma is important in order to establish a differential diagnosis among the various lymph node pathologies, especially in view of the possible malignancies and the different therapy and follow-up approaches for each one.

REFERENCES

1. Chan JK, Frizzera G, Fletcher CD, Rosai J. Primary vascular tumors of lymph nodes other than Kaposi's sarcoma. Analysis of 39 cases and delineation of two new entities. *Am J Surg Pathol.* 1992 Apr;16(4):335-50.
2. Elgoweini M, Chetty R. Primary nodal hemangioma. *Arch Pathol Lab Med.* 2012 Jan;136(1):110-2. DOI: 10.5858/arpa.2010-0687-RS
3. Har-El G, Heffner DK, Ruffy M. Haemangioma in a cervical lymph node. *J Laryngol Otol.* 1990 Jun;104(6):513-5.
4. Kasznica J, Sideli RV, Collins MH. Lymph node hemangioma. *Arch Pathol Lab Med.* 1989 Jul;113(7):8047.
5. Dellachà A, Fulcheri E, Campisi C. A lymph nodal capillary-cavernous hemangioma. *Lymphology.* 1999 Sep;32(3):1235.
6. Terada T. Capillary cavernous hemangioma of the lymph node. *Int J Clin Exp Pathol.* 2013;6(6):1200-1.
7. Park SH, Jeong YM, Cho SH, Jung HK, Kim SJ, Ryu HS. Imaging findings of variable axillary mass and axillary lymphadenopathy. *Ultrasound Med Biol.* 2014;40(9):1934-48. DOI: 10.1016/j.ultrasmedbio.2014.02.019
8. Dener C, Sengul N, Tez S, Caydere M. Haemangiomas of the breast. *EurJSurg.* 2000;166:977-9. DOI:10.1080/110241500447182
9. Catania VD, Manzoni C, Novello M, Lauriola L, Coli A. Unusual presentation of angiomatous hamartoma in an eight-month-old infant: case report and literature review. *BMC Pediatr.* 2012;12:172. DOI: 10.1186/1471-2431-12-172