

CHEST WALL RESECTION FOR LOCOREGIONAL RECURRENCE OF BREAST CANCER: A FEASIBLE AND EFFECTIVE

Ressecção da parede torácica para recidiva locorregional de câncer de mama: um método efetivo e reprodutível

Jose Roberto Piato¹ , Bruna Salani Mota^{1*} , Fernando Conrado Abrão² , Maíra Teixeira Dória¹ ,
Marcos Desidério Ricci¹ , Alexandre Mendonça Munhoz³ , Jose Roberto Filassi¹ 

ABSTRACT

Objective: The aim of this study was to evaluate survival after chest wall resection for breast cancer locoregional recurrence. Secondary endpoints were symptomatic control and safety of the procedure. **Method:** This was a retrospective review including all patients who underwent chest wall resection for breast cancer local recurrence at the Division of Thoracic Surgery of the School of Medicine of São Paulo University, from January 1998 to November 2011. Full thickness chest wall resection involving bones and/or soft tissues was performed to achieve macroscopical free margins. **Results:** Eighteen patients were included in this study with a mean follow-up of 83.5 months. The interval between mastectomy and chest wall recurrence (CWR) was 4.2 years (0.5 to 9 years). The resection was complete in 12 patients (66%) and incomplete in 6 (33%), in whose resection would involve amputation of an upper limb. Mean tumor size was 8.25 cm and resection of the costal arch was necessary in 10 patients. There was no operation death and after two years, 66% of patients were alive. Six patients died due to distant recurrence of breast cancer on patients who died to inflammatory acute abdomen. The mean survival among patients who died was 25.2 months (12 to 42 months). At the last follow-up visit, eleven patients were alive. **Conclusion:** CWR for locally recurrent breast cancer is feasible and safe in selected patients, who did not develop metastatic disease, allowing good quality of life for a considerable period. Larger and prospective series are needed to endorse our findings.

KEYWORDS: breast neoplasm; neoplasm recurrence, local; thoracic wall; thoracic surgery; survival.

RESUMO

Objetivo: O objetivo deste estudo foi avaliar a sobrevida após ressecção da parede torácica para recidiva locorregional de câncer de mama. Desfechos secundários foram controle dos sintomas e a segurança do procedimento. **Métodos:** Estudo retrospectivo de todos os pacientes submetidos à ressecção da parede torácica para recidiva local do câncer de mama na Divisão de Cirurgia Torácica da Faculdade de Medicina da Universidade de São Paulo, de janeiro de 1998 a novembro de 2011. A ressecção da parede torácica foi realizada com espessura total podendo envolver ossos e/ou tecidos moles, a fim de atingir margens livres macroscópicas. **Resultados:** Dezoito pacientes foram incluídos neste estudo, com seguimento médio de 83,5 meses. O intervalo entre a mastectomia e a recidiva da parede torácica (RPT) foi de 4,2 anos (0,5 a 9 anos). A ressecção foi completa em 12 pacientes (66%) e incompleta em 6 (33%), cuja ressecção envolveria a amputação do membro superior. O tamanho médio do tumor foi de 8,25cm e a ressecção do arco costal foi necessária em 10 pacientes. Não houve óbito devido à operação e, após dois anos, 66% dos pacientes estavam vivos. Seis pacientes morreram devido à recorrência sistêmica do câncer de mama e uma paciente morreu devido a um abdome agudo inflamatório. A sobrevida média entre os pacientes que morreram foi de 25,2 meses (12 a 42 meses). Na última consulta de acompanhamento, onze pacientes estavam vivos. **Conclusões:** A RPT para a recidiva locorregional do câncer de mama é factível e segura em pacientes selecionados, que não desenvolveram doença metastática, permitindo boa qualidade de vida por um período considerável. São necessárias séries maiores e prospectivas para endossar nossos achados.

PALAVRAS-CHAVE: neoplasias da mama; recidiva local de neoplasia; parede torácica; cirurgia torácica; sobrevivência (saúde pública).

Study carried out at the Division of Thoracic Surgery, School of Medicine, Universidade de São Paulo.

¹Gynecology Division, Hospital das Clínicas, Faculdade de Medicina, Universidade de São Paulo – São Paulo (SP), Brazil.

²Thoracic Surgery Department, Heart Institute, Hospital das Clínicas, Faculdade de Medicina, Universidade de São Paulo – São Paulo (SP), Brazil.

³Plastic Surgery Division, Hospital das Clínicas, Faculdade de Medicina, Universidade de São Paulo – São Paulo (SP), Brazil.

*Corresponding author: brunasalani@hotmail.com

Conflict of interests: nothing to declare.

Received on: 10/05/2018. Accepted on: 11/06/2018

INTRODUCTION

Breast cancer treatment has had a significant improvement in the last decades, including new surgical techniques, such as conservative surgery and sentinel lymph node biopsy in early breast cancer. However, chest wall recurrence (CWR) is still a concern when dealing with advanced cancer. Evidence-based guidelines are not yet available for this heterogeneous group¹⁻³.

CWR of breast cancer occurs in 5 to 40% of patients⁴, with 5-year survival frequently estimated to be between 30 to 50%⁵. However, some authors have reported that a subgroup of these patients had better prognosis and aggressive therapy has been performed for increasing their quality of life and, eventually, their survival⁶. In fact, those patients may be a target of aggressive surgery accompanied by chemo and radiotherapy⁷.

The effectiveness of surgical resection for locally recurrent breast cancer invading the chest wall remains poorly defined, possibly because patients are rarely referred for resection. This is in part due to the general impression that locally recurrent disease is merely a harbinger of rapidly progressive distant disease. In addition, chest reconstruction of the CWR is controversial^{8,9}. In fact there are differences of opinion on who should undergo reconstruction and what type of reconstruction should be done. However, CWR requires tissue coverage of an extensive chest wall defect at mastectomy. In these cases, myocutaneous flaps are the most common approach^{10,11}. Furthermore few studies have examined the survival curve and local re-recurrence beyond the perioperative period. Also, less information is available concerning the surgical planning of large thoracic wound reconstruction with local and distant flaps. Our primary objective was to evaluate survival after chest wall resection. Secondary endpoints were symptomatic control and safety of the procedure offered by surgical treatment of local recurrence of breast cancer involving the chest wall.

METHOD

This study was a retrospective review including all patients who underwent chest wall resection for breast cancer local recurrence at the Division of Thoracic Surgery of the School of Medicine of São Paulo University, Brazil, from January 1998 to November 2011. This study was approved by our institutional ethics committee. Locoregional recurrent disease was defined as the reappearance of disease at the site of prior breast excision, axillary, sternal (internal thoracic nodes), or subclavian lymph nodes. Full thickness chest wall resection involving bones and/or soft tissues was performed to achieve macroscopical free margins.

For all patients, preoperative evaluation included assessment of both the local extension of the tumor and distant

metastasis. Chest computed tomography (CT) scan was used to diagnose tumor size and extension to muscle, ribs, sternum and vessels. Pleuropulmonary dissemination was evaluated as well. Distant disease was addressed through chest upper abdomen CT and bone scintigraphy. Low Karnofsky performance status (<70) and distant metastasis were deemed to be contraindications to resection. Only after careful planning and thorough discussion among thoracic surgeons, mastologists, oncologists and plastic surgeons were the patients considered eligible for resection.

The procedure was based on total resection of the tumor with 1-cm margins. A polypropylene mesh was used in cases of sternal resection or when three consecutive ribs were resected. All specimens were examined for histology and margin status (complete or incomplete resection). Reconstruction was planned and conducted by the plastic surgery team; however, breast reconstruction was not performed simultaneously. Postoperative radiotherapy was used if the patient was not exposed to its maximum dose and chemotherapy was employed in patients with high risk of distant metastasis based on assessment of oncologists.

The data analyzed were age, gender, procedure, surgical margins, reconstruction techniques, symptom control at the last contact with patient by personal opinion, operative morbidity and mortality, adjuvant treatment, recurrence and mortality. Operative deaths included patients who died within the first 30 days after surgery or during the same hospitalization period.

Follow-up information was obtained from all patients through visits to outpatient clinic office and medical file evaluation. The overall survival was demonstrated using a Kaplan-Meier survival curve. End points were: survival after the resection of the recurrence, local recurrence and safety of the surgical procedure.

RESULTS

The study population consisted of 18 women with mean follow-up of 83.5 months (5 to 162 months). Mean age at chest wall resection was 58 years (36 to 80). Only one patient had skin integrity preserved at the moment of the surgery. The interval between mastectomy and CWR was 4.2 years (0.5 to 9 years).

Most patients had recurrence at the site of prior breast excision (50%) and the resection was complete in 12 patients (66%) and incomplete in 6 (33%), whose resection would involve amputation of an upper limb. Mean tumor size was 8.25 cm in its longest axis and resection of the costal arch was necessary in 10 patients (patients 1, 3, 4, 9, 11, 12, 13, 15, 17 and 18). The tip of the scapula and partial superior sternectomy were resected in two patient, each (patients 1 and 10, and patients 11 and 12, respectively). Other 7 patients were submitted to soft tissue resection only involving intercostals and serratus anterior muscles.

The chest wall reconstruction was performed with polypropylene mesh in 6 patients (patients 1, 2, 4, 8, 11 and 15) due to rib resection. A myocutaneous pedicled flap was rotated into the resected area in seven patients (5 were submitted to transverse musculocutaneous rectus abdominis flap (TRAM), based on the rectus muscle, and 2 to *latissimus dorsi* (LD) flap, to reconstruct the defect). Primary synthesis was performed in 7 patients. The average time of hospitalization was 5 days (2 to 19). All patients had chest tube drainage. There was no operative death and only one operative complication occurred, which was a wound infection on the 15th postoperative day; the patient was hospitalized for debridement with good outcome (Figures 1A to 1F).

Regarding survival, after two years, 66% of patients were alive. Six patients died due to distant recurrence of breast cancer and one patient died to inflammatory acute abdomen; the latter was the only patient who had local recurrence 14 months after surgical procedure. The mean survival among patients who died was 25.2 months (12 to 42 months). At the last follow-up visit, eleven patients were alive (mean of 17.3 months after thoracic procedure). Regarding patients with incomplete resection, two died and three were alive with 18 months of survival and no signs of recurrence. After chest wall resection, isolated chemotherapy was employed in 13 patients. The choice of giving chemotherapy was made by the oncologist's assessment of patients at high risk of systemic recurrence. Radiotherapy was performed in three patients with incomplete resection. All patients referred improvement in their quality of life (Table 1).

DISCUSSION

Breast cancer CWR is considered a predictor of poor prognosis, with a frequently estimated 30 to 50% 5-year survival, and mortality is attributed to the frequent subsequent appearance of disseminated metastases⁵. However, a recent analysis of isolated CWRs has suggested that local recurrence was associated with a median survival of 5.6 years and a 10-year survival of 30%¹². There has been a strong increasing trend of patients with local recurrence and considerable life expectancy, as well as major advances in disease control in metastatic breast cancer, with more effective chemotherapy treatments. In the current context, longer lengths of survival allow local complications to occur, impairing quality of life during the survival of these patients. Therefore the precise natural history of this problem has yet to be fully defined¹³ and is probably associated with the location of locoregional recurrence, as illustrated in the study by Nielsen et al., which showed by multivariate analysis that the site of locoregional recurrence (site of previous resection of the breast, axilla, internal thoracic or subclavian lymph nodes), was

a statistically significant prognostic factor. Recurrence in the same site of previous resection of the breast had better prognosis compared to subclavian lymph node recurrence in terms of survival¹⁴.

Regarding the procedure's safety, several reports showed that CWR is a safe and justifiable procedure with low mortality (0 to 4.5%) and morbidity¹³. In our small series, there were no perioperative deaths and only one complication (10%).

Regarding local control, our study had only one patient with local recurrence (10%) after one year of thoracic procedure, although we had five patients at high risk for recurrence (axillary, subclavian and internal thoracic recurrence)¹⁴. Other studies that did not specify the site of local recurrence showed different rates of other locoregional recurrence as 16% in the first year (10), and 50% at 2 years¹³. Moreover, Nielsen et al. showed locoregional recurrence of 30% in two years in patients with local recurrence at the site of previous breast resection¹⁴.

It is currently common for the clinician to avoid chest wall resection, but it should be noted that the literature shows 5-year survival ranging from 30–74%^{5,15} in selected patients. Therefore, it is justified to remove ulcerating, friable tumors in selected cases, directed at palliating pain and reducing odor.

Reconstructive aspects is a topic of increasing interest thanks to the improvement in the use of myocutaneous flaps⁸⁻¹¹. Thus, these reconstructive techniques have given the surgeon the chance to undertake wide resection of CWR, which would have been considered "unresectable". In some cases, tumor resection was avoided because of the difficulty in achieving negative histological margins, and the associated surgical morbidity and mortality.

Surgical management of these large wounds is a matter of current debate and includes skin grafts, and local cutaneous, omental or distant myocutaneous flaps^{8,11}. A simple skin graft is often not a viable option, because it represents an unstable reconstruction following radiotherapy and a poor aesthetic outcome. Thus, this technique is generally reserved for patients without clinical conditions and with a very poor prognosis. The LD and TRAM flaps have traditionally been recommended for closure of these large defects. Although the TRAM flap presents some advantages, it is not applicable in all patients, especially in slim patients or those who are not candidates for more complex procedures. The extended LD presents a different design, which makes it possible to obtain large triangular islands, with primary closure in V-Y form^{10,11}. Thus, its main positive aspect is the ability to close a large defect without the expense of a donor wound. In addition, the operative time for the LD flap is shorter than that for the TRAM, making it an effective and safe technical alternative for a patient with a large thoracic wound. The blood supply is reliable, based on the large-caliber thoracodorsal vessels, and it provides pliable tissue to fill the thorax and axillary region. Furthermore, the skin is of

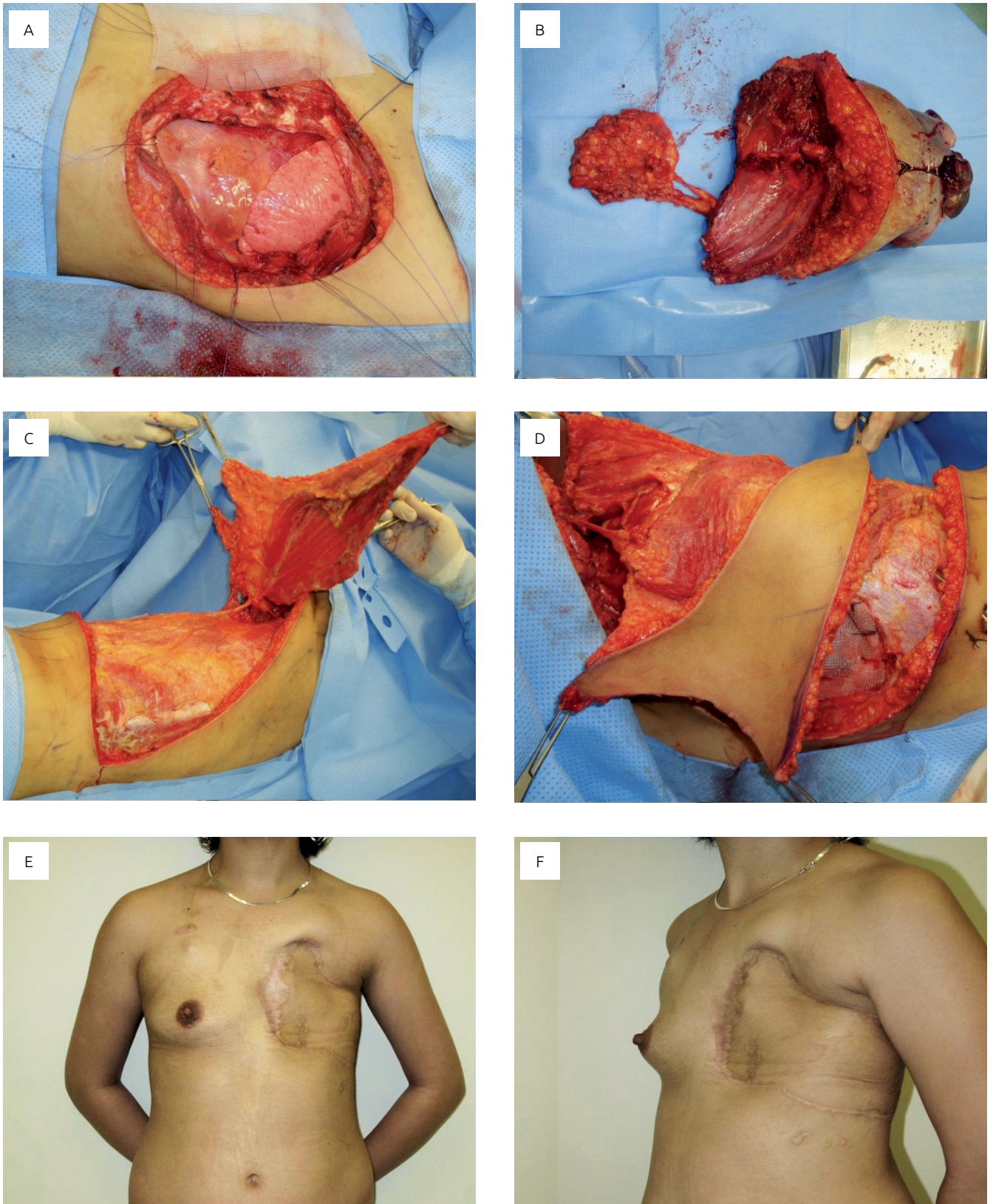


Figure 1. A 44-year-old patient with locally advanced chest wall recurrence to the left breast. The patient underwent a left radical chest wall resection with wide resection of three ribs. The resulting defect measured 25x23 cm and extended over the left thorax (Figures 1A and 1B). The oncological procedure was immediately followed by an extended V-Y *latissimus dorsi* myocutaneous flap reconstruction. The chest wall defect was reconstructed with polypropylene mesh (Figures 1C and 1D, center-below left and right). Six-months postoperative appearance with a very good outcome (Figures 1E and 1F, below left and right).

good quality and the flap of sufficient thickness to completely conceal the exposed ribs¹¹.

Evidence-based guidelines for multimodality treatment are not yet available for this heterogeneous group of breast cancer

Table 1. Clinical characteristics and oncological outcomes.

Number of patients	18
Follow up	83.5 months (5 to 162)
Age at chest wall resection	58 years (36 to 80)
Interval between mastectomy and chest wall recurrence	4.2 years (0.5 to 9)
Tumor size	8.25 cm
The average time of surgery hospitalization	5 days (2 to 19)
Type of chest resection	
Costal arch resection	10
Tip of the scapula and partial superior sternectomy	2
Intercostals and serratus anterior muscles resection	6
Chest wall reconstruction	
Polypropylene mesh	6
Myocutaneous flap	5
Primary synthesis	7
Oncological outcomes	
2-years overall survival	66%
Death for distant breast cancer metastasis	6
Death for other causes	1
Local recurrence	1

patients. A few reports have focused on radiotherapy for all kinds of locoregional recurrence and mainly in patients who underwent some type of surgery before radiotherapy was provided¹⁶. In 43 to 68% of patients, radiotherapy can provide local control, with a reported 5- and 10-year overall survival of 36 to 61% and 21 to 35%, respectively¹⁶. We believe these results are high, as a large number of patients with a small scar recurrence are included³. No differences in outcome were found between surgery and radiotherapy for small isolated lesions of local recurrence, but aggressive multimodality treatment was usually advised³. According to Dutch evidence-based guidelines, surgery is recommended in combination with hormone treatment for estrogen-receptor or progesterone-receptor positive tumors, for locoregional recurrence¹⁷. Our study has a small sample size and thus we cannot conclude anything about the multimodal treatment; however, we believe that radiotherapy should be used as a complement after resection of tumor margins.

Our series is small, despite containing only patients with the same tumor subtype (invasive ductal carcinoma) and involves a large retrospective period, in which multiple treatments of breast cancer were used over the years. These two factors require caution in interpreting our results related to prognostic criteria and survival, but it adds information to a little explored area of expertise for our specialty.

We conclude that chest wall resection for locally recurrent breast cancer is feasible and safe in selected patients, who did not develop metastatic disease, allowing good quality of life for a considerable period of time during the period of survival of these patients. In spite of its benefits, essential technical details must be considered beforehand. We believe that the success of the procedure depends on patient selection, coordinated planning with the plastic surgery team and careful intra-operative management.

REFERENCES

- Luini A, Gatti G, Zurrada S, Talakhadze N, Brenelli F, Gilardi D, et al. The evolution of the conservative approach to breast cancer. *Breast*. 2007;16(2):120-9. <https://doi.org/10.1016/j.breast.2006.11.001>
- Piato JR, Barros AC, Pincerato KM, Sampaio AP, Pinotti JA. Sentinel lymph node biopsy in breast cancer after neoadjuvant chemotherapy. A pilot study. *Eur J Surg Oncol*. 2003;29(2):118-20.
- van der Pol CC, van Geel AN, Menke-Pluymers MB, Schmitz PI, Lans TE. Prognostic factors in 77 curative chest wall resections for isolated breast cancer recurrence. *Ann Surg Oncol*. 2009;16(12):3414-21. <https://doi.org/10.1245/s10434-009-0662-7>
- Fisher B, Slack NH, Cavanaugh PJ, Gardner B, Ravdin RG. Postoperative radiotherapy in the treatment of breast cancer: results of the NSABP clinical trial. *Ann Surg*. 1970;172(4):711-732.
- Probstfeld MR, O'Connell TX. Treatment of locally recurrent breast carcinoma. *Arch Surg*. 1989;124(10):1127-30. <https://doi.org/10.1001/archsurg.1989.01410100025005>
- Lê MG, Arriagada R, Spielmann M, Guinebretiere JM, Rochard F. Prognostic factors for death after an isolated local recurrence in patients with early-stage breast carcinoma. *Cancer*. 2002;94(11):2813-20. <https://doi.org/10.1002/ncr.10572>
- Borner M, Bacchi M, Goldhirsch A, Greiner R, Harder F, Castiglione M, et al. First isolated locoregional recurrence following mastectomy for breast cancer: results of a phase III multicenter study comparing systemic treatment with observation after excision and radiation. *Swiss Group for Clinical Cancer Research. J Clin Oncol*. 1994;12(10):2071-7. <https://doi.org/10.1200/JCO.1994.12.10.2071>

8. Skoracki RJ, Chang DW. Reconstruction of the chest wall and thorax. *J Surg Oncol*. 2006;94(6):455-65. <https://doi.org/10.1002/jso.20482>
9. Slavin SA, Love SM, Goldwyn RM. Recurrent breast cancer following immediate reconstruction with myocutaneous flaps. *Plast Reconstr Surg*. 1994;93(6):1191-204; discussion 1205-7.
10. Arruda EG, Munhoz AM, Montag E, Filassi JR, Gemperli R. Immediate chest wall reconstruction during pregnancy: surgical management after extended surgical resection due to primary sarcoma of the breast. *J Plast Reconstr Aesthet Surg*. 2014;67(1):115-8. <https://doi.org/10.1016/j.bjps.2013.06.007>
11. Munhoz AM, Montag E, Arruda E, Okada A, Brasil JA, Gemperli R, et al. Immediate locally advanced breast cancer and chest wall reconstruction: surgical planning and reconstruction strategies with extended V-Y latissimus dorsi myocutaneous flap. *Plast Reconstr Surg*. 2011;127(6):2186-97. <https://doi.org/10.1097/PRS.0b013e318213a038>
12. Kamby C, Sengeløv L. Pattern of dissemination and survival following isolated locoregional recurrence of breast cancer. A prospective study with more than 10 years of follow up. *Breast Cancer Res Treat*. 1997;45(2):181-92.
13. Downey RJ, Rusch V, Hsu FI, Leon L, Venkatraman E, Linehan D, et al. Chest wall resection for locally recurrent breast cancer: is it worthwhile? *J Thorac Cardiovasc Surg*. 2000;119(3):420-8.
14. Nielsen HM, Overgaard J, Grau C, Christensen JJ, Overgaard M. Audit of the radiotherapy in the DBCG82b&ctrials--a validation study of the 1,538 patients randomised to postmastectomy radiotherapy. *Radiother Oncol*. 2005;76(3):285-92. <https://doi.org/10.1016/j.radonc.2005.08.002>
15. Schwaibold F, Fowble BL, Solin LJ, Schultz DJ, Goodman RL. The results of radiation therapy for isolated local regional recurrence after mastectomy. *Int J Radiat Oncol Biol Phys*. 1991;21(2):299-310.
16. Snyder AF, Farrow GM, Masson JK, Payne WS. Chest-wall resection for locally recurrent breast cancer. *Arch Surg*. 1968;97(2):246-53.
17. Rauschecker H, Clarke M, Gatzemeier W, Recht A. Systemic therapy for treating locoregional recurrence in women with breast cancer. *Cochrane Database Syst Rev*. 2001(4):CD002195. <https://doi.org/10.1002/14651858.CD002195>