







IMAGING FINDINGS OF ABSORBABLE VICRYL MESH IMPLANTED AFTER LUMPECTOMY

Achados de imagem de tela absorvível de Vicryl implantada após cirurgia conservadora

Almir Galvão Vieira Bitencourt^{1*} , Marília Mendes de Azevedo¹ , Vinicius Cardona Felipe¹ , Juliana Alves de Souza¹ , Mauricio Doi² , Hugo Fontan Kohler³ 

ABSTRACT

The Vicryl mesh implantation after lumpectomy, which was first proposed in 2003, is a simple technique, less expensive than other proposed implantable biomaterials. However, the postoperative follow-up may be difficult, since the implanted mesh impairs the evaluation of surrounding breast parenchyma at both mammography and ultrasound. Magnetic resonance imaging can be used as a problem-solving tool if there are equivocal findings at physical exam, mammography, or ultrasound. Nevertheless, there are only few reports in literature about the imaging aspects of implanted absorbable mesh in the breast. The images presented in this case show the typical presentation of a foreign body granuloma associated with the Vicryl mesh. Breast radiologists and surgeons should be aware of these imaging aspects to avoid misdiagnosis and unnecessary additional exams.

KEYWORDS: mammography; ultrasonography; magnetic resonance imaging; postoperative care; surgical mesh.

RESUMO

A implantação da tela de Vicryl após quadrantectomia, proposta pela primeira vez em 2003, é uma técnica simples, sendo menos dispendiosa do que outros biomateriais implantáveis. Entretanto, o acompanhamento pós-operatório pode ser difícil, uma vez que a tela implantada compromete a avaliação do parênquima mamário adjacente, tanto na mamografia quanto na ultrassonografia. A ressonância magnética pode ser utilizada se houver achados duvidosos no exame físico, na mamografia ou na ultrassonografia. No entanto, existem poucos relatos na literatura sobre os aspectos de imagem da tela absorvível implantada na mama. As imagens apresentadas neste caso mostram a apresentação típica de um granuloma de corpo estranho associado à tela de Vicryl. Radiologistas e cirurgiões devem estar cientes desses aspectos de imagem para evitar diagnósticos incorretos e exames adicionais desnecessários.

PALAVRAS-CHAVE: mamografia; ultrassonografia; imagem por ressonância magnética; cuidados pós-operatórios; telas cirúrgicas.

¹Imaging Department, A. C. Camargo Cancer Center – São Paulo (SP), Brazil.

²Mastology Department, A. C. Camargo Cancer Center – São Paulo (SP), Brazil.

³Head and Neck Department, A. C. Camargo Cancer Center – São Paulo (SP), Brazil.

*Corresponding author: almir.bitencourt@accamargo.org.br

Conflict of interests: nothing to declare.

Received on: 11/27/2018. Accepted on: 12/27/2018

A 64-year-old female patient, who performed left breast conservative surgery five years ago for a tubular carcinoma (T1miN0M0), complained of left breast lump near the surgical scar. At surgery, an absorbable polyglactin 910 (Vicryl) mesh was inserted to fill the surgical defect and improve cosmetic outcome. Mammography showed focal asymmetry in the upper quadrants of the left breast with a surgical clip inside it (Figure 1). Ultrasound presented a linear hyperechoic image with intense posterior acoustic shadowing (Figure 2). Breast magnetic resonance imaging (MRI) showed a well-encapsulated cystic mass with thin walls and content with low signal at T1-weighted images and heterogenous high signal

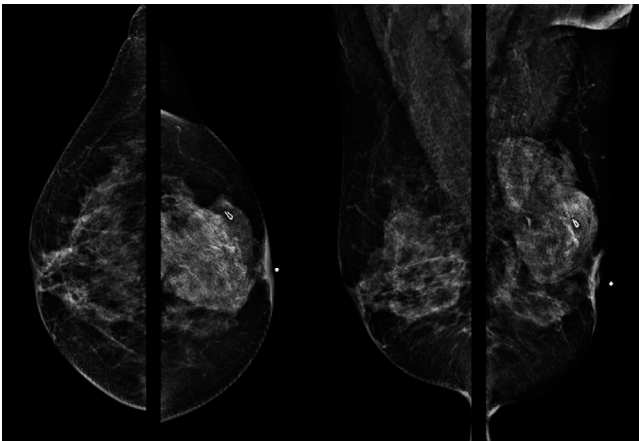


Figure 1. Mammography (craniocaudal and mediolateral oblique views) shows signs of previous left breast surgery, with a metallic surgical clip and a focal asymmetry at the left breast upper quadrants.

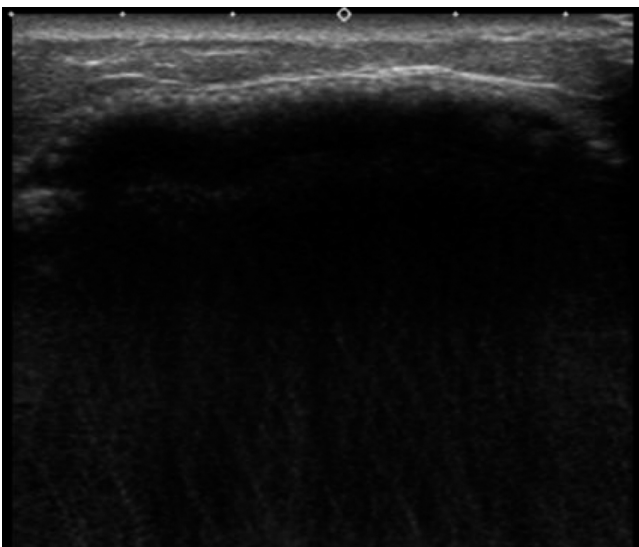


Figure 2. Ultrasound shows a linear hyperechoic image with intense posterior acoustic shadowing at the left breast upper quadrants, which impair the evaluation of the underlying breast parenchyma.

on T2-weighted images, demonstrating linear hypointense images inside it (Figure 3). The imaging aspects are compatible with a foreign body granuloma associated with the Vicryl mesh. However, if there was no detailed information about the previous surgery, it could be misdiagnosed as a breast collection or intracapsular rupture implant. Although breast conserving surgery has been a standard surgical treatment for breast cancer, it results in breast deformity. Many surgical techniques have been used to improve the cosmetic outcome, such as tissue flaps, artificial implants, and mesh materials¹.

Vicryl mesh is a synthetic and absorbable material that has been extensively used in many surgical specialties. Its implantation after lumpectomy, which was first proposed in 2003, is a simple technique, less expensive than other proposed implantable biomaterials^{2,3}. Nevertheless, it may increase postoperative complications and not improve cosmetic outcomes^{4,6}. In addition, the postoperative follow-up may be difficult since the implanted mesh impairs the evaluation of surrounding breast parenchyma at both mammography and ultrasound. MRI can be used as a problem-solving tool if there are equivocal findings at physical exam, mammography, or ultrasound. There are only few reports in literature about the imaging aspects of implanted absorbable mesh in the breast⁷⁻⁹. The images presented in this case show the typical presentation of foreign body granulomatous reaction, since the Vicryl mesh induces reactive fluid and granulation tissue formation. Breast radiologists and surgeons should be aware of these imaging aspects to avoid misdiagnosis and unnecessary additional exams.

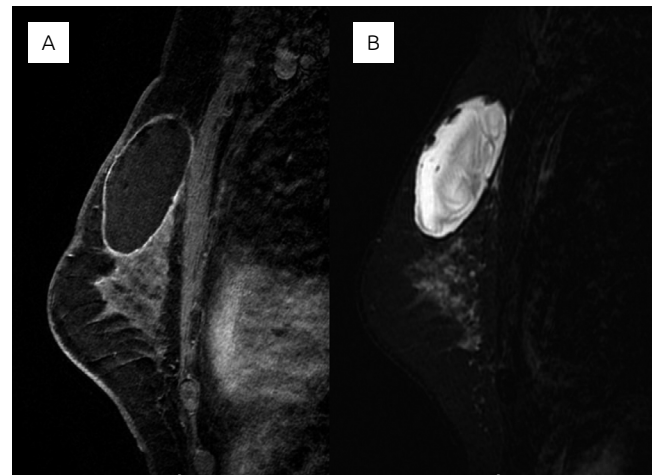

Figure 3. Breast magnetic resonance imaging (MRI) shows a well-encapsulated cystic mass with thin walls and content with low signal at T1-weighted images (A) and heterogenous high signal on T2-weighted images, presenting linear hypointense images inside it (B).

REFERENCES

1. Churgin S, Isakov R, Yetman R. Reconstruction options following breast conservation therapy. *Cleve Clin J Med*. 2008;75(Suppl. 1):S24-9.
2. Sanuki J, Fukuma E, Wadamori K, Higa K, Sakamoto N, Tsunoda Y. Volume replacement with polyglycolic acid mesh for correcting breast deformity after endoscopic conservative surgery. *Clin Breast Cancer*. 2005;6(2):175.
3. Tessler O, Reish RG, Maman DY, Smith BL, Austen WG Jr. Beyond biologics: absorbable mesh as a low-cost, low-complication sling for implant-based breast reconstruction. *Plast Reconstr Surg*. 2014;133(2):90e-9e. <https://doi.org/10.1097/01.prs.0000437253.55457.63>
4. Tsuji W, Yotsumoto F. Pros and cons of immediate Vicryl mesh insertion after lumpectomy. *Asian J Surg*. 2018;41(6):537-42. <https://doi.org/10.1016/j.asjsur.2017.08.001>
5. Lee A, Won Hwang H, Chang J, Lim W, Moon BI. Outcomes of breast conserving surgery with immediate vicryl-mesh insertion: is it safe and effective? *Breast J*. 2012;18(4):334-8. <https://doi.org/10.1111/j.1524-4741.2012.01247.x>
6. Koo MY, Lee SK, Hur SM, Bae SY, Choi MY, Cho DH, et al. Results from over one year of follow-up for absorbable mesh insertion in partial mastectomy. *Yonsei Med J*. 2011;52(5):803-8. <https://doi.org/10.3349/ymj.2011.52.5.803>
7. Góes JC, Landecker A, Lyra EC, Henríquez LJ, Góes RS, Godoy PM. The application of mesh support in periareolar breast surgery: clinical and mammographic evaluation. *Aesthetic Plast Surg*. 2004;28(5):268-74. <https://doi.org/10.1007/s00266-004-3099-1>
8. Choi Y, Hong HP, Kwag HJ. Ultrasonographic findings of an implanted absorbable mesh in patients with breast partial resection: a preliminary study. *J Korean Soc Ultrasound Med*. 2007;26(2):89-94.
9. Kwag HJ. Imaging findings of implanted absorbable mesh in patients with breast partial resection. *Yonsei Med J*. 2008;49(1):111-8. <https://doi.org/10.3349/ymj.2008.49.1.111>