



TRANSFORMATION OF FIBROADENOMA TO PHYLLODES TUMOR AND THE USE OF ONCOPLASTIC TECHNIQUE FOR BREAST CONSERVATIVE TREATMENT

A transformação do fibroadenoma em tumor filóides e o uso de técnicas oncoplásticas no tratamento cirúrgico conservador de mama

Julia Dias do Prado^{1*} , Roberto José da Silva Vieira² , Waldyr Gomes da Costa Neto³ ,
Linda Lorena Gonzalez de Castro⁴ , Bruno Bohrer Flores⁵ , Lea Pikelhaizen Velloso⁴ 

ABSTRACT

Phyllodes tumors (PT) are rare neoplasms accounting for <1% of breast lesions. A transformation of a fibroadenoma (FA) to a PT is even more rare and unpredictable. Many challenges face PT management, since diagnostic through surgical treatment. We describe a case of a 63-year old woman with PT that was previously diagnosed as a FA who underwent an oncoplastic conservative surgery. A review of the literature on the diagnostic and surgical management of PT was performed. The diagnostic of PT can be hard mostly in needle biopsy, and the close follow up of negative lesions is recommended. Oncoplastic techniques might be an important tool on the conservative treatment of these patients.

KEYWORDS: phyllodes tumor; diagnostic; fibroadenoma; oncoplastic technique; breast conservative surgery.

RESUMO

O tumor filoide (TF) é uma rara neoplasia que corresponde a menos de 1% das lesões mamárias. A transformação do fibroadenoma (FA) em TF é um evento raro e imprevisível. Existem muitos desafios no manejo dos TF, desde o seu diagnóstico ao tratamento. Nós descrevemos o caso de uma paciente de 63 anos com TF com diagnóstico prévio de FA que foi submetida ao tratamento cirúrgico conservador da mama por técnicas oncoplásticas. Uma revisão da literatura sobre o diagnóstico e tratamento do TF foi realizada. O diagnóstico dessa condição pode ser especialmente difícil quando feito a partir de amostra de biópsias por agulha, e em caso de resultados negativos recomenda-se acompanhamento rigoroso. As técnicas oncoplásticas podem ser uma importante ferramenta no tratamento cirúrgico conservador desses pacientes.

PALAVRAS-CHAVE: tumor filoide; diagnóstico; fibroadenoma; técnica oncoplástica; cirurgia conservadora da mama.

Study carried out at private practice of Dr. Roberto José da Silva Vieira.

¹Hospital Universitário Antônio Pedro, Hospital Universitário Gaffrée e Guinle – Rio de Janeiro (RJ), Brazil.

²Fundação Oswaldo Cruz, Pontifícia Universidade Católica do Rio de Janeiro – Rio de Janeiro (RJ), Brazil.

³Hospital Quinta D’Or – Rio de Janeiro (RJ), Brazil.

⁴Pontifícia Universidade Católica do Rio de Janeiro – Rio de Janeiro (RJ), Brazil.

⁵Universidade Luterana do Brasil – Canoas (RS), Brazil.

*Corresponding author: juliardias@gmail.com

Conflict of interests: nothing to declare.

Received on: 11/05/2018. Accepted on: 12/27/2018

INTRODUCTION

Both fibroadenomas (FA) and phyllodes tumors (PT) belong to a heterogeneous group of biphasic fibroepithelial breast lesions with stromal and epithelial components that demonstrate wide ranging biological behavior with differences in clinical management. FA are common tumors, and the increasing use of core biopsy rather than excision to diagnose these lesions has become common place to follow them with imaging. A transformation of a FA to a PT is rare and unpredictable. Sanders and Sara found an incidence of 2.4% of PT on a group of 2,062 growing FA¹. There are two possibilities that could account for a core biopsy proven FA being rediagnosed as a PT: the possibility of having misdiagnosed a PT, or, more rarely, the progression of a FA into a PT².

The standard procedure for treatment, no matter what the grade of the PT, is surgical wide local excision, preferably with clear margins of at least 1 cm³. Effective surgical treatment many times requires a mastectomy because of the volume of the tumor or its location. We report the case of a 63-year-old woman with a mammotome biopsy proven FA that underwent transformation into a benign PT after one year of size stability. The patient was submitted to a conservative breast surgery with the use of oncoplastic technique which allowed an effective treatment associated to a good aesthetic outcome.

CASE REPORT

A 63-year-old woman presented to us asymptomatic with her screening breast exams. On initial assessment, the patient had no hormonal background though a positive family history of breast carcinoma. Ultrasound and mammography revealed suspected nodule on the left breast. The patient had a normal clinical. Mammo-tome biopsy revealed FA, and clinical follow was done. After one year asymptomatic, she presented to us with a history of rapidly growing very large left breast swelling. Clinical examination revealed a 4 cm obvious mass of the left breast. The skin of the breast was enlarged, red and warmth. Another mammo-tome biopsy was done and suggested PT.

The patient underwent to a lumpectomy surgery with skin resection, to achieve adequate margins, and proceeded to immediate breast reconstruction and contralateral symmetry. The tumor was on the intersection outer quadrants, and the tissue removed was replaced by inferior dermcutaneous pedicle. Definitive histology showed benign PT with clear excision margins (Figures 1 and 2).

DISCUSSION

PT are rare, comprising only 0.3–1% of all primary breast tumors⁴. This lesion was first described by Joahannes Müller in 1838 as Cystosarcoma Phyllodes, and its malignance behavior was recognized by Lee and Pack in 1931 in their series of 111 cases with one mortality by pulmonary metastasis⁵.

The age of presentation is usually 40–50 years, but these tumors can present at any age. Rare reports in men are often associated with gynecomastia, suggesting a role for hormonal influence on its physiopathology⁴.

PT is hypercellular fibroepithelial lesion that have a wide morphological spectrum. The benign PT shows overlapping features with cellular FA, whereas the malignant tumors may have a morphological resemblance with primary breast sarcoma or spindle cell metaplastic carcinoma⁴.

PT is graded according to recommendations by the World Health Organization (WHO) as benign, borderline, or malignant based on the presence and degree of stromal cellularity, atypia, mitotic activity, border infiltration versus circumscription and stromal overgrowth⁴.

Most tumors (60–75%) are benign, with borderline and malignant tumors constituting 15–20% and 10–20%, respectively.

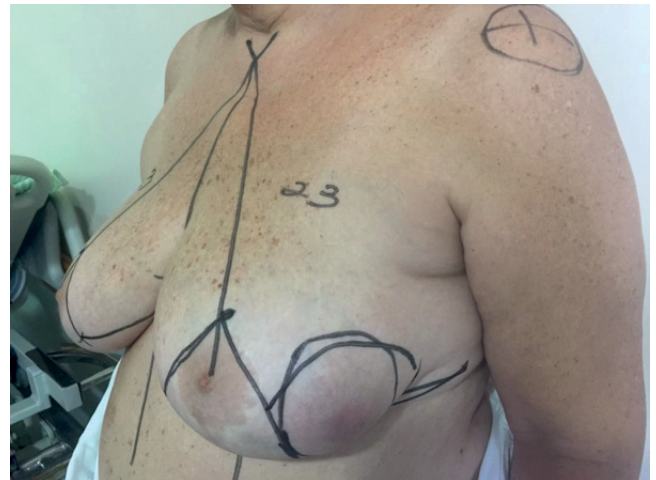

Figure 1. The tumor had 4 cm and was on the intersection outer quadrants of left breast with skin commitment.

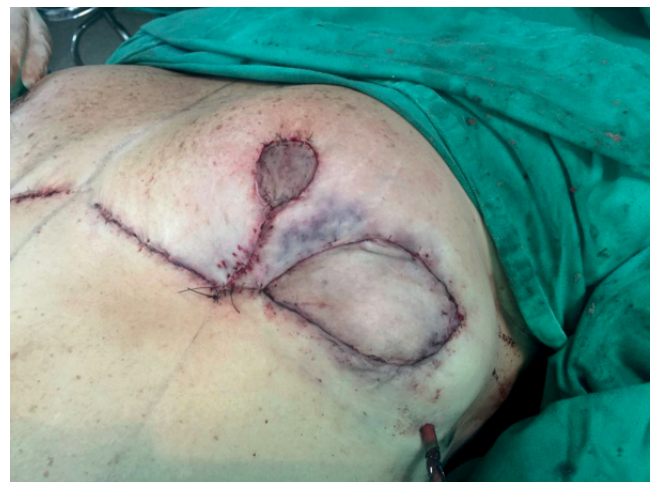

Figure 2. Immediate post-operative result using inferior dermcutaneous pedicle technique.

The histological features determinate the biological behavior of the tumor. Recurrence rates may have some variation in the literature, but overall are 10–17, 14–25 and 23–30% for benign, borderline and malign tumors, respectively. Metastatic potential is very low on borderline tumors (0–4%), whereas malignant tumors demonstrating metastatic potential up to 22% of cases^{3,4}. There are extremely rare reports of metastasis on benign tumor with the qualification that all tumors should be adequately sampled account for intratumoral heterogeneity³.

Despite all the effort establishing criteria for diagnosing PT, Thomas et al. showed the difficulty that exists in distinguishing some cellular FA from PT even for pathologists who specialize in breast pathology. On a 21 study cases, we only have 100% agreement in 2 cases as to whether the tumor represented a FA or PT. If the diagnoses of FA/cellular FA and benign PT were combined and separated from the borderline and malignant PT, there was agreement in 53% of cases⁶.

Diagnoses in core needle biopsy specimen may be even harder. Choi et al. analyzed histopathological features of core needle biopsy and surgical excision specimen comparatively in 129 patients with surgically proven PT. The concordant rate of diagnosis was about 60%, and all discordant diagnoses were underestimated in matched core needle biopsy. The hypotheses that they found to explain their results was that in core needle biopsy it is possible sample only a part of the total lesion and the intrinsic heterogeneity of the tumor. They conclude that fewer mitoses of PT are observed in core needle biopsy than in surgical excision generally⁷.

Many reports tried to define predictors factors for PT transformation from FA. Abe et al., analyzing 36 cases of malignant transformations of FA to PT, concluded that rapid tumor growth or sudden increase in size is the most important clinical characteristic for prediction of progression⁸. However, it is difficult to assess the reliability of this observation because no rate of growth was defined as a risk cut off and most of growing FA does not involve PT¹.

Besides the diagnoses issue, clinical management is another point that have been discussed. The mainstay of PT management has traditionally consisted of surgical excision with wide tumor-free margins, generally defined as at least 10 mm, for an adequate local control³.

Some recent data tried to evaluate the real importance of wide tumor-free margins. Mangi et al. from Massachusetts General

Hospital found that post-excision recurrences were exclusively to cases with positive margins or margins of less than 10 mm⁹. Otherwise, Onkendi et al., from Mayo Clinic, found that the extent of surgical excision had no impact on disease free survive in a study with borderline and malignant tumors. However, because of the small numbers of patients treated with breast conservation with narrow margins, they recommend caution on this analysis and advertise that these finds are not enough to change clinical practice¹⁰. As convincing evidence for appropriate margin surgical excised PT remains elusive, width surgical margins remain the option of most of specialist. A more conservative approach can be considerable in specific cases of benign tumor³.

Breast conservative surgery can be a challenge on PT treatment. On a study of 170 patients with PT, the mean of tumor size was 7 cm, and most of the patients presented with a tumor bigger than 5 cm¹¹. High dimensions associated with width margins leads to an important specimen resection. Cochrane et al. demonstrated that 20% of breast volume excised is enough to have an important risk of a poor cosmetic result¹². To avoid mastectomy, the use of oncoplastic techniques prove to be an important tool to achieve good cosmetic outcome on patients who need big breast volume resections¹³. On our patient, because of the skin commitment, the size and the location of the tumor, we believe that the simple width resection would probably result on a breast deformation. The use of oncoplastic technique allowed us to achieve a breast conservative treatment with a satisfactory cosmetic result.

Because of the infrequency of lymph nodal disease in PT, most investigators do not recommend routine axillary dissection. The role of adjuvant therapy remains imprecise and its uses is considered on a case-by-case basis^{3,11}.

CONCLUSION

In summary, management of PT presents the specialist with unique challenges. Diagnostically, we believe that mammary biopsy represents the best tool for ambulatory approach. However, a negative result does not exclude the chances of a PT, and close follow up with a big eye on rapid growth is recommended. The local treatment remains width surgical excision, and the use of oncoplastic techniques might be useful in extending the indications for conservative therapy.

REFERENCES

1. Sanders LM, Sara R. The growing fibroadenoma. *Acta Radiologica Open*. 2015;4(4):1-5. <http://doi.org/10.1177/2047981615572273>
2. Sanders LM, Daigle ME, Tortora M, Panasiti R. Transformation of benign fibroadenoma to malignant phyllodes tumor. 2015;4(4):1-3. <http://doi.org/10.1177/2058460115592061>
3. Tan BY, Acs G, Apple SK, Badve S, Bleiweiss IJ, Brogi E, et al. Phyllodes tumors of the breast: a consensus review. *Histopathology*. 2016;68(1):5-21. <http://doi.org/10.1111/his.12876>
4. Krings G, Bean GR, Chen YY. Fibroepithelial lesions; The WHO spectrum. *Semin Diagn Pathol*. 2017;34(5):438-52. <http://doi.org/10.1053/j.semmp.2017.05.006>

5. Boff RA. Compêndio de mastologia: abordagem multidisciplinar. Cap. 28. In: RA Boff, De Carli AC, Brenelli H, Brenelli FP, De Carli LS, Sauer FZ, et al. Editors. Compêndio de mastologia: abordagem multidisciplinar. 1st ed. Caxias do Sul: I C DE SOUZA OLIVEIRA LIVRARIA ME, 2015. p.331-6.
6. Lawton TJ, Acs G, Argani P, Farshid G, Gilcrease M, Goldstein N, et al. Interobserver variability by pathologists in the distinction between cellular fibroadenomas and phyllodes tumors. *Int J Surg Pathol.* 2014;22(8):695-8. <http://doi.org/10.1177/1066896914548763>
7. Choi J, Koo JS. Comparative study of histological features between core needle biopsy and surgical excision in phyllodes tumor. *Pathol Int.* 2012;62(2):120-6. <http://doi.org/10.1111/j.1440-1827.2011.02761.x>
8. Abe M, Miyata S, Nishimura S, Iijima K, Makita M, Akiyama F, et al. Malignant transformation of breast fibroadenoma to malignant phyllodes tumor: long-term outcome of 36 malignant phyllodes tumors. *Breast Cancer.* 2011;18(4):268-72. <http://doi.org/10.1007/s12282-009-0185-x>
9. Mangi AA, Smith BL, Gadd MA, Tanabe KK, Ott MJ, Souba WW, et al. Surgical management of phyllodes tumors. *Arch Surg.* 1999;134(5):487-93. <http://doi.org/10.1001/archsurg.134.5.487>
10. J Onkendi EO, Jimenez RE, Spears GM, Harmsen WS, Ballman KV, Hieken TJ. Surgical treatment of borderline and malignant phyllodes tumors: the effect of the extent of resection and tumor characteristics on patient outcome. *Ann Surg Oncol.* 2014 Oct;21(10):3304-9. <http://doi.org/10.1245/s10434-014-3909-x>
11. Reinfuss M, Mituś J, Duda K, Stelmach A, Rys J, Smolak K. The Treatment and Prognosis of Patients with Phyllodes Tumor of the Breast. *Cancer.* 1996;77(5):910-6.
12. Cochrane RA, Valasiadou P, Wilson AR, Al-Ghazal SK, Macmillan RD. Cosmesis and satisfaction after breast-conserving surgery correlates with the percentage of breast volume excised. *Br J Surg.* 2003;90(12):1505-9.
13. Clough KB, Lewis JS, Couturaud B, Fitoussi A, Nos C, Falcou MC. Oncoplastic techniques allow extensive resections for breast-conserving therapy of breast carcinomas. *Ann Surg.* 2003;237(1):26-34.