

# IDIOPATHIC GRANULOMATOUS MASTITIS: CASE SERIES

## Mastite granulomatosa idiopática: série de casos

Laís Neiva Rego Siqueira<sup>1</sup>, Danilo Rafael da Silva Fontinele<sup>2\*</sup>, Sabas Carlos Vieira<sup>3</sup>, Lina Gomes dos Santos<sup>4</sup>

### ABSTRACT

Idiopathic granulomatous mastitis is a rare disease that mimics other pathological conditions, including breast adenocarcinoma, breast tuberculosis, and abscess. Three patients diagnosed with idiopathic granulomatous mastitis were analyzed, receiving corticosteroid treatment, antibiotic therapy in cases of abscesses, and, in one case, resection of the affected breast segment. All patients exhibited regression of symptoms.

**KEYWORDS:** mastitis; granulomatous mastitis; breast; anti-bacterial agents; corticosteroids.

### RESUMO

A mastite granulomatosa idiopática é uma doença rara que mimetiza outras condições patológicas, incluindo adenocarcinoma de mama, tuberculose de mama e abscesso. Foram analisados três pacientes com diagnóstico de mastite granulomatosa idiopática, que receberam como tratamento corticosteroide, antibioticoterapia em casos de abscessos e, em um caso, ressecção do segmento mamário afetado. Todas as pacientes evoluíram com regressão dos sintomas.

**PALAVRAS-CHAVE:** mastite; mastite granulomatosa; mama; antibacterianos; corticosteroides.

<sup>1</sup>Centro Universitário Uninovafapi – Teresina (PI), Brazil.

<sup>2</sup>Universidade Estadual do Piauí – Teresina (PI), Brazil.

<sup>3</sup>Oncocenter – Teresina (PI), Brazil.

<sup>4</sup>Hospital São Marcos – Teresina (PI), Brazil.

\*Corresponding author: drsilvafontinele@gmail.com

Conflicting interests: nothing to declare.

Received on: 06/04/2019. Accepted on: 08/13/2019

## INTRODUCTION

Idiopathic granulomatous mastitis (IGM), also known as granulomatous lobular mastitis, is a rare disease of chronic inflammatory nature, well-defined, and of slow progression<sup>1</sup>. IGM can be mistakenly diagnosed as breast carcinoma, breast abscess, plasma cell mastitis, fat necrosis, or breast tuberculosis<sup>2</sup>.

Although the cause of the disease is unknown, the general consensus is that reproductive age, recent pregnancy, breastfeeding, and history of contraceptive pill use are the main conditions associated with the illness, which is prevalent in emerging countries<sup>3</sup>.

In this scenario, we evaluated three IGM cases diagnosed in a private clinic in Teresina, from March 12, 2013 to December 11, 2018. All participants signed the informed consent form.

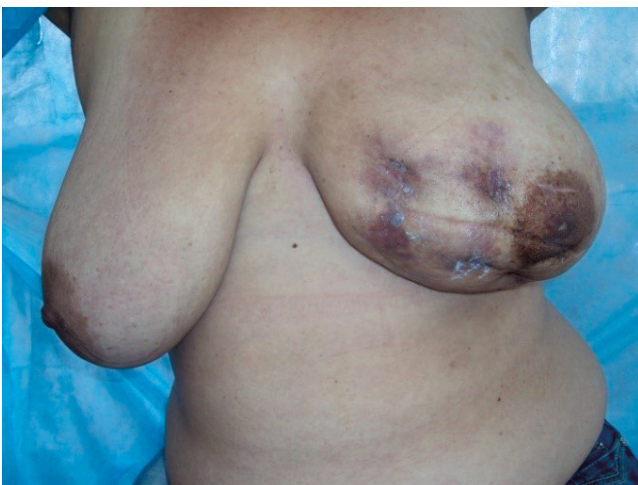## CASE REPORT

### First case

A 41-year-old patient had a painless 5-cm nodule in the left upper outer quadrant (UOQ). She underwent mammography and ultrasound, which revealed a cystic lesion measuring 4 × 4 cm, with solid areas in between, thick capsule, and without flow on Doppler examination. The acid-fast bacilli (AFB) culture was negative, and the surgical biopsy revealed the presence of IGM. After one month, the patient returned with infection, which was surgically drained, starting a corticosteroid therapy with dose escalation (20 mg for one month; 10 mg for 20 days; and 5 mg for 10 days) associated with a proton pump inhibitor. The patient came back after treatment presenting a decrease in the lesion, and, ten months after treatment, she had no complaints.

### Second case

A 30-year-old patient presented a typical sign of abscess (Figure 1) and a nodule in the right UOQ one month before her appointment.



**Figure 1.** Patient, 30 years old, presenting lesion compatible with an abscess in the left breast, with four erythematous foci.

Mammography revealed an area of hyperdensity in the right UOQ, without other findings. Ultrasound showed an irregular nodule of 6 × 4 cm in the right UOQ, without flow on Doppler and without posterior acoustic shadowing. Surgical biopsy identified IGM with foci of suppuration. Partial resection of the lesion (8 cm) and abscess drainage were performed, with negative AFB culture. Antibiotic therapy consisted of cefadroxil administered for 15 days associated with corticosteroid with dose escalation for two months. After five months, the patient returned without complaints, and the physical examination showed an area compatible with scar fibrosis at the surgical site.

### Third case

A 41-year-old patient had a retroareolar nodule in the left breast two months before her appointment. In the physical examination, the left breast presented a hardened retroareolar area associated with hyperemia with drainage of serosanguineous fluid through a fistulous orifice. The patient denied fever. She underwent mammography, which revealed a retroareolar nodule with ill-defined contours, extending to the UOQ and measuring 5 × 4 cm. Ultrasound showed an irregular hypoechoic lesion, no flow on Doppler, and no posterior acoustic shadowing. The biopsy confirmed IGM and abscess. The therapeutic approach adopted was antibiotic therapy with cefadroxil and corticosteroid with dose escalation for two months. After this period, the patient returned presenting considerable recovery of the left breast.

## DISCUSSION

The main signs and symptoms of IGM are the presence of unilateral breast nodule, pain, skin lesions, and fistulas<sup>4</sup>. Patients predominantly presented abscess (Figure 1) and unilateral breast nodules.

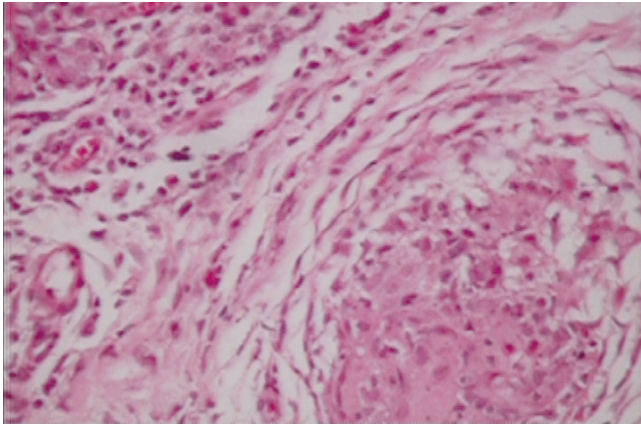
The IGM diagnosis is by exclusion, along with biopsy, because only a histopathological examination can establish a definitive diagnosis<sup>4</sup>. Specific histological findings are characterized by non-caseating and non-vascular granulomatous inflammatory changes, which can be observed in the center of the lobes<sup>5</sup>. Mammography radiological findings are not precise, and ultrasound is characterized by the presence of multiple irregular hypoechoic lesions and collections with finger-like tubular connections<sup>4</sup>.

All patients in this series underwent biopsy, tuberculosis test, and ultrasound. In all cases, the biopsy revealed fibrosis and chronic granulomatous inflammatory process (Figures 2 and 3), the tuberculosis test was negative, and the ultrasound showed hypoechoic nodules associated with cystic areas with thick content.

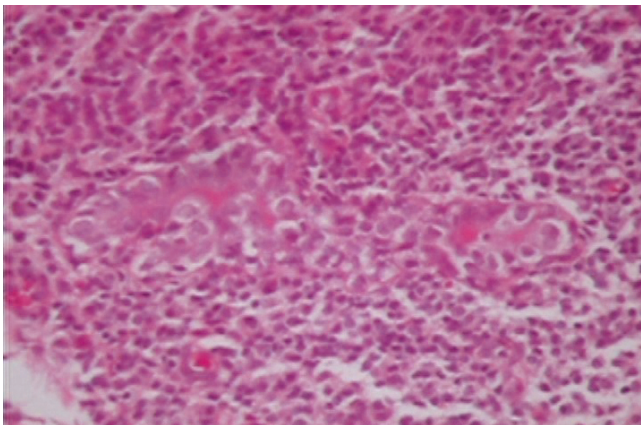
New studies demonstrate the importance of imaging records. Images, such as those from magnetic resonance, are useful in monitoring IGM behavior and clinical improvement, particularly in patients conservatively managed<sup>6</sup>. Also, elastography as adjuvant for conventional B-scan ultrasound, together with the calculated

stress rate, helps to differentiate IGM from malignant breast lesions<sup>7</sup>. These tests were not performed in the cases described.

There is no consensus on the best treatment approach yet. Surgical excision and steroid therapy are the most adopted<sup>8</sup>. However, in case of complications such as abscess, fistulas, and



**Figure 2.** Microscopy of a sample stained with hematoxylin-eosin, showing the presence of an edge of fibroblasts and connective tissue with T cells infiltrate, characterizing a granulomatous inflammatory process.



**Figure 3.** Microscopy of a sample stained with hematoxylin-eosin, showing a large macrophage and T lymphocyte infiltration, characterizing a chronic inflammatory process.

persistent wound infections, surgical resection can be considered the main treatment modality with curative intention, as well as in cases of localized diseases<sup>9,10</sup>.

Thus, complete resection of the affected tissue, with or without using corticosteroids, is often recommended as an ideal treatment, although it has long follow-up, recurrence in up to 38% of patients, and slow wound healing<sup>10</sup>. Nonetheless, surgical excision may be useful in providing accurate diagnosis<sup>10</sup>. After excision, if there is no infection, recurrence, or wound healing impairment, the treatment can be completed<sup>10,11</sup>.

DeHertogh et al.<sup>12</sup> were the first to recommend the use of corticosteroids to treat IGM. Steroid treatment can be administered after excision in complicated and resistant cases, or in patients who had only an incisional biopsy and in initially unresectable lesions before surgery<sup>11,13</sup>. Early diagnosis and administration of corticosteroids may prevent repetitive and deforming breast biopsies, as well as long-term recurrence<sup>13</sup>. However, the weighting of possible risks and benefits of the therapy is still difficult due to the lack of broader studies and the small number of reported cases<sup>10-13</sup>.

The use of immunosuppressants (methotrexate and azathioprine) is indicated in cases of resistance to corticosteroid therapy. The administration of immunosuppressants is more effective in controlling the inflammatory process and preventing future complications. The combination of methotrexate and azathioprine has been useful in the treatment of primary and recurrent diseases<sup>14</sup>.

A meta-analysis demonstrated that the IGM remission/resolution (RR) rate, with the use of oral corticosteroids was 71.8% with a recurrence rate of 20.9%, while remission with the use of topical corticosteroid was 98.8% with a recurrence rate of 14.3%. The association of oral corticosteroids with surgical resection presents resolution in 94.5% of the cases and a recurrence rate of 4%. This meta-analysis assessed 15 scientific publications, including 602 cases<sup>15</sup>.

## CONCLUSION

In the present study, all patients with IGM showed remission of the disease using corticosteroid therapy after an average follow-up of three months.

## REFERENCES

1. Stefanon CC, Goncalves AF, Lima R, Rossi K. Idiopathic granulomatous mastitis: clinical, mammography and ultrasound findings. *Radiol Bras.* 2005;38(3):225-30.
2. Olsen ML, Dilaveri CA. Idiopathic granulomatous mastitis: a case report of breast abscess. *BMJ Case Reports.* 2011;1-2. <http://dx.doi.org/10.1136/bcr.05.2011.4271>
3. Freeman CM, Xia BT, Wilson GC, Lewis JD, Khan S, Lee SJ, et al. Idiopathic granulomatous mastitis: a diagnostic and therapeutic challenge. *Am J Surg.* 2017;214(4):701-6. <https://doi.org/10.1016/j.amjsurg.2017.07.002>
4. Yildiz S, Aralasmak A, Kadioglu H, Toprak H, Yetis H, Gucin Z, et al. Radiologic findings of idiopathic granulomatous mastitis. *Med Ultrason.* 2015;17(1):39-44. <https://doi.org/10.11152/mu.2013.2066.171.rfm>
5. Li J. Diagnosis and treatment of 75 patients with idiopathic lobular granulomatous mastitis. *J Invest Surg.* 2018;32(5):414-420. <https://doi.org/10.1080/08941939.2018.1424270>
6. Fazzio RT, Shah SS, Sandhu NP, Glazebrook KN. Idiopathic granulomatous mastitis: imaging update and review. *Insights Imaging.* 2016;7(4):531-9. <https://doi.org/10.1007/s13244-016-0499-0>

7. Yağcı B, Erdem Toslak IT, Çekiç B, Öz M, Karakaş BR, Akdemir M, et al. Differentiation between idiopathic granulomatous mastitis and malignant breast lesions using strain ratio on ultrasonic elastography. *Diagn Interv Imaging*. 2017;98(10):685-91. <https://doi.org/10.1016/j.diii.2017.06.009>
8. Sheybani F, Sarvghad MR, Naderi HR, Gharib M. Treatment for and clinical characteristics of granulomatous mastitis. *Obstet Gynecol*. 2015;125(4):801-7. <https://doi.org/10.1097/AOG.0000000000000734>
9. Moris D, Damaskos C, Davakis S, Vailas M, Garmpis N, Spartalis E, et al. Is idiopathic granulomatous mastitis a surgical disease? The jury is still out. *Ann Transl Med*. 2017;5(15):309. <https://doi.org/10.21037/atm.2017.05.24>
10. Erozgen F, Ersoy YE, Akaydin M, Memmi N, Celik AS, Celebi F, et al. Corticosteroid treatment and timing of surgery in idiopathic granulomatous mastitis confusing with breast carcinoma. *Breast Cancer Res Treat*. 2010;123(2):447-52. <https://doi.org/10.1007/s10549-010-1041-6>
11. Deng JQ, Yu L, Yang Y, Feng XJ, Sun J, Liu J, et al. Steroids administered after vacuum-assisted biopsy in the management of idiopathic granulomatous mastitis. *J Clin Pathol*. 2017;70(10):827-31. <https://doi.org/10.1136/jclinpath-2016-204287>
12. DeHertogh DA, Rossof AH, Harris AA, Economou SG. Prednisone management of granulomatous mastitis. *N Engl J Med*. 1980;303(14):799-800. <https://doi.org/10.1056/NEJM198010023031406>
13. Mizrakli T, Velidedeoglu M, Yemisen M, Mete B, Kilic F, Yilmaz H, et al. Corticosteroid treatment in the management of idiopathic granulomatous mastitis to avoid unnecessary surgery. *Surg Today*. 2015;45(4):457-65. <https://doi.org/10.1007/s00595-014-0966-5>
14. Goulart APS, Silva RR, Volbrecht B, Viegas J, Zerwes FP, Frasson AL. Idiopathic lobular granulomatous mastitis: case report. *Rev Bras Mastologia*. 2011;21(1):46-9.
15. Lei X, Chen K, Zhu L, Song E, Su F, Li S. Treatments for idiopathic granulomatous mastitis: systematic review and meta-analysis. *Breastfeed Med*. 2017;12(7):415-21. <https://doi.org/10.1089/bfm.2017.0030>