

VALUE OF THE INTRAOPERATIVE CYTOLOGY EXAMINATION OF SENTINEL LYMPH NODE IN BREAST CANCER

Valor do exame citológico intraoperatório do linfonodo sentinela no câncer de mama

Talita Siemann Santos Pereira¹, Guilherme Loureiro Werneck², Henrique de Castro Rodrigues³,
Ana Helena Pereira Correia⁴, Flávia Clímaco⁴, Afrânio Coelho de Oliveira^{4*}

ABSTRACT

Objective: Evaluate the value of imprint cytology in the intraoperative analysis of sentinel lymph node (SLN) in patients with breast cancer. **Methods:** An agreement study for the evaluation of the imprint cytology technique as a diagnostic test for intraoperative SLN among patients diagnosed with breast cancer from January 2007 to January 2017. **Results:** We studied 210 cases of breast cancer patients submitted to intraoperative sentinel node imprint cytology, aged between 24 and 86 years (mean age 59 years and median age 60 years). The sensitivity of the intraoperative study was 58.3% (95%CI 46.1–69.8%) and the specificity was 97.8% (95%CI 93.8–99.5). The positive predictive value (PPV) was 93.3% (95%CI 81.7–98.6) and the negative predictive value (NPV) was 81.8% (95%CI 75.1–87.4). From the analyzed variables, the presence of macrometastasis was the only one that significantly increased the sensitivity of the imprint to 73.2% (95%CI 59.7–84.2), while micrometastasis presented a sensitivity of only 6.3% (95%CI 0.2–30.2). **Conclusion:** The use of imprint cytology in the intraoperative SLN study showed good accuracy in predicting axillary status. However, the surgeon and pathologist are fully aware of the set of clinical and histological variables that can influence the sensitivity of the method.

KEYWORDS: Sentinel lymph node; breast cancer; cell biology.

RESUMO

Objetivo: Avaliar o valor do *imprint* citológico na análise intraoperatória do linfonodo sentinela (LS) em pacientes com câncer de mama. **Métodos:** Estudo de concordância para avaliação da técnica do *imprint* citológico como teste diagnóstico do LS no intraoperatório, entre pacientes com diagnóstico de câncer de mama, no período de janeiro de 2007 a janeiro de 2017. **Resultados:** Foram estudados 210 casos de pacientes com câncer de mama submetidas à citologia de impressão (IC) do linfonodo sentinela no intraoperatório, com idade entre 24 e 86 anos (média de 59 anos e mediana de 60 anos). A sensibilidade do estudo intraoperatório foi de 58,3% (IC95% 46,1–69,8) e a especificidade de 97,8% (IC95% 93,8–99,5). O valor preditivo positivo (VPP) foi de 93,3% (IC95% 81,7–98,6) e o valor preditivo negativo (VPN) de 81,8% (IC95% 75,1–87,4%). Das variáveis analisadas, a presença de macrometástase foi a única que aumentou significativamente a sensibilidade do *imprint* para 73,2% (IC95%, 59,7–84,2%), enquanto na micrometástase apresentou sensibilidade de apenas 6,3% (IC95% 0,2–30,2). **Conclusão:** A utilização do *imprint* citológico no estudo intraoperatório do LS apresentou boa acurácia na previsão do *status* axilar. Entretanto, é importante o pleno conhecimento, pelo cirurgião e patologista, do conjunto de variáveis clínicas e histológicas que podem influenciar a sensibilidade do método.

PALAVRAS-CHAVE: Linfonodo sentinela; câncer de mama; citologia.

Study carried out at the Hospital Universitário Clementino Fraga Filho, Universidade Federal do Rio de Janeiro – Rio de Janeiro (RJ), Brazil.

¹Hospital Universitário Clementino Fraga Filho, Universidade Federal do Rio de Janeiro – Rio de Janeiro (RJ), Brazil.

²Instituto de Estudos em Saúde Coletiva, Universidade Federal do Rio de Janeiro – Rio de Janeiro (RJ), Brazil.

³Serviço de Epidemiologia e Avaliação, Hospital Universitário Clementino Fraga Filho, Universidade Federal do Rio de Janeiro – Rio de Janeiro (RJ), Brazil.

⁴Hospital Universitário Clementino Fraga Filho, Universidade Federal do Rio de Janeiro – Rio de Janeiro (RJ), Brazil.

*Autor correspondente: afranio.co@gmail.com

Conflict of interests: nothing to declare.

Received on: 04/23/2018. **Accepted on:** 07/14/2018

INTRODUCTION

Breast cancer is the second most frequent cancer in the world and the one with the highest incidence among women in Brazil. According to the National Cancer Institute (INCA), the number of new cases of breast cancer expected for Brazil in 2016 was 57,960, with an estimated risk of 57 cases per 100,000 women¹.

The early diagnosis of breast cancer has increased mainly because of mammography screening programs. Thus, less aggressive and more conservative treatments have been developed, with good cosmetic results and without affecting the control of the disease. In the twentieth century, the treatment of breast cancer evolved from the Halsted radical mastectomy to conservative surgery².

The work that consolidated the conservative surgery was a result of the classic study by Veronesi et al., who did not demonstrate difference in disease-free survival or overall survival between the groups (mastectomy vs. conservative surgery and radiotherapy). Based on these results, they concluded that the mastectomy subjected the patients to unnecessary mutilations³.

Despite the progression to conservative breast surgery, the only method that made it possible to evaluate the presence of axillary lymph node metastasis was the complete axillary lymphadenectomy of levels I, II and III according to the Berg classification, exposing large numbers of patients to sequelae, and without greater therapeutic benefits, especially when indicated in early-stage tumors^{4,5}.

In 1977, Cabanas proposed the concept of sentinel lymph node (SLN) in solid epithelial tumors, which consisted of the hypothesis that lymph nodes receiving the first lymphatic drainage of the tumor could be removed by smaller surgery and examined by means of an intraoperative study with the intention of determining the need for regional lymphadenectomy⁶.

The first study on SLN research in breast cancer patients was performed by Giuliano et al. at the John Wayne Cancer Institute at Saint John's Hospital and Health Center in Santa Monica, California, in 1994. It was proven that the technique improved staging accuracy and had the potential to replace axillary lymphadenectomy⁷. Since then, a large number of studies and publications have found that SLN determines lymph node status in early breast cancer with high accuracy, demonstrating that it is safe to omit axillary lymphadenectomy in cases of SLN without metastatic disease⁸⁻¹⁰.

In 2010, a study published by Giuliano et al. concluded that, despite the potential for residual axillary disease after LS biopsy, failure to perform axillary lymphadenectomy with metastatic involvement of one to two lymph nodes may provide excellent regional control and may be considered a treatment option for early-stage breast cancer patients treated with conservative surgery, tangential radiotherapy and adjuvant systemic therapies¹¹.

The techniques employed/utilized for the intraoperative study of SLN may be imprint cytology and frozen section.

Imprint cytology can provide rapid, technically feasible diagnosis by preserving tissue for the permanent section. By freezing the material, there is the disadvantage that the sections can undergo artefactual alterations, the tissues are consumed and the procedure may take a longer time to execute¹². However, the most important question is whether the intraoperative assessment of SLN, regardless of the technique used, is performed with a high degree of precision.

Considering the importance and the impact in breast cancer treatment and the minimally invasive approach that SLN represents, it is relevant that a referral service in the treatment of breast cancer obtains its data and evaluate the results of its intraoperative study. Therefore, the present study was performed with the purpose of demonstrating the value of imprint cytology in the evaluation of SLN in patients with breast cancer.

MATERIALS AND METHODS

This is an agreement study to the evaluation of the imprint cytology technique as an intraoperative LS diagnostic test in patients diagnosed with breast cancer at the University Hospital Clementino Fraga Filho (HUCCF) of Universidade Federal do Rio de Janeiro (UFRJ), in the period from January 2007 to January 2017. The definitive histopathological examination was used as the gold standard.

The intraoperative study was performed using the imprint cytology technique. The SLN examined was cut in two parts along its largest axis, and the imprint cytology of each of the obtained halves was performed. The cytology slides of the imprint were stained with toluidine blue or hematoxylin-eosin (H-E) and examined under an optical microscope to investigate cytological features of malignancy.

The sentinel lymph node was sectioned in slices with approximately 2 mm in thickness, fixed in 10% formalin solution, and sent in its entirety for routine histopathological processing, with inclusion in paraffin and obtaining definitive histological sections, stained with H-E. In cases where the first histopathological cut was negative, two additional cut levels of 200 µm each were stained with H-E. In the cases of infiltrating lobular carcinoma, the routine also included an anti-cytokeratin immunohistochemical test.

The data sources used were the database of the pathological anatomy service and notes on physical medical records. The variables evaluated in the database were the result of intraoperative imprint cytology and the definitive SLN report. In the medical records, the following data were collected: age (<50 years, 50 to 59 years, 60 to 69 years, ≥70 years), menopause, surgery performed, year of procedure, tumor size, histological type, histological grade, estrogen receptor, progesterone receptor, Her-2 gene, Ki67 antigen, number of evaluated SLN, axillary lymphadenectomy performed after SLN biopsy, axillary lymphadenectomy

after definitive assessment, final histopathology of axillary lymphadenectomy, type of SLN metastasis (micrometastasis or macrometastasis), presence of vascular embolization, neoadjuvant chemotherapy and staging (TNM).

The results of the intraoperative SLN assessment by means of imprint cytology were compared with the results of the definitive diagnosis. The sensitivity and specificity of the intraoperative examination were analyzed, as well as the positive and negative predictive values throughout the series of patients. Later, we studied the same parameters according to available clinical and histological data: age and menopause status, histological type and size of the tumor, presence of vascular embolism, histological grade, hormonal receptor status, neoadjuvant chemotherapy and size of nodal metastases.

Statistical analysis was performed using the Excel® and Stata® software. The overall results for each patient were classified as true positive (TP — presence of metastatic cells in the intraoperative examination and final histological examination), false positives (FP — presence of metastatic cells in the intraoperative examination, but not in the final histological examination), true negatives (TN — absence of metastatic cells in the intraoperative and final examinations) or false negatives (FN — presence of metastatic cells in the final histological examination that were not initially observed in the intraoperative examination).

Intraoperative studies were performed by different pathologists from the pathology department of HUCCF/UFRJ.

RESULTS

A total of 213 cases were selected. Three patients with incomplete results were excluded from the pathological anatomy service database. A total of 210 patients, all female, aged between 24 and 86 years, with an average of 59 years and a median of 60 years, were analyzed. Among the 210 patients, 172 (81.90%) were postmenopausal.

A total of 112 patients (53.33%) underwent conservative surgery and 98 (46.67%) underwent mastectomy. The mean tumor size in the final histopathological evaluation (pT) was 2.86 cm. Regarding staging, 64 (30.47%) were found in stage I, 120 (57.14%) in stage II, and 26 (12.39%) in stage III. Fifteen patients (7.14%) underwent neoadjuvant chemotherapy. The number of sentinel lymph nodes evaluated intraoperatively by imprint cytology was 510, with a mean of 2.4 lymph nodes/patient.

In the histological subtypes, 154 (73.33%) invasive ductal carcinomas were found (59 grade 3, 71 grade 2, 24 grade 1), 21 (10%) lobular carcinomas, eight (3.8%) ductal carcinomas *in situ* and 27 (12.85%) special subtypes, including, metaplastic (five), mucinous (four), tubular (three), papilar (five), micropapillary (four), spinal (five) and cribriform (one). The neoplastic embolization detected in the surgical specimen containing the carcinoma was present in 40 (19.04%) cases.

The immunohistochemical examination detected positivity for the estrogen receptor in 170 (80.95%) and for the progesterone receptor in 167 (79.52%) patients. Ki67 and Her2 were evaluated in 97 (46.20%) cases, and Her2 expression in 14 (6.6%) patients. Among the cases, we found 52 (24.76%) luminal A, 28 (5.9%) luminal B, 16 (7.61%) triple negatives and two (0.95%) pure Her2.

The correlation of the clinical-pathological variables of the sample with the intraoperative cytological imprint of the SLN are described in Table 1.

Table 1. Correlation between clinical and pathological variables and imprint cytology.

Variables	Number of cases	Positive SLN on imprint	Sensitivity (CI)
Age (years)			
<50	49	12	50% (95%CI 29.1–70.9)
50–59	60	16	77.8% (95%CI 52.4–93.6)
60–69	62	12	63.2% (95%CI 38.4–83.7)
>70	39	5	36.4% (95%CI 10.9–69.2)
Menopause			
Yes	172	37	60.7% (95%CI 46.8–73.5)
No	38	8	50% (95%CI 24.7–75.3)
Size (pT)			
T1	77	12	62.5% (95%CI 35.4–84.8)
T2	114	26	54.3% (95%CI 39–69.1)
T3	19	7	70% (95%CI 34.8–93.3)
Histological type			
IDC	154	37	61.8% (95%CI 47.7–74.6)
Grade 1	24	2	25% (95%CI 3.19–65.1)
Grade 2	71	21	72% (95%CI 50.6–87.9)
Grade 3	56	12	60% (95%CI 36.1–80.9)
ILC	21	4	36.4% (95%CI 10.9–69.2)
Others	27	4	66.7% (95%CI 22.3–95.7)
Estrogen receptor			
Positive	170	40	58.7% (95%CI 45.6–71)
Negative	40	5	55.6% (95%CI 21.2–86.3)
Neoplastic embolization			
Yes	40	18	72,7% (95%CI 49.8–89.3)
No	170	27	52% (95%CI 37.4–66.3)
Neoadjuvant Chemo			
Yes	15	-	-
No	195	45	60,9% (95%CI 48.4–72.4)
Metastasis size			
Micro	16	1	6,3% (95%CI 0.2–30.2)
Macro	56	41	73,2% (95%CI 59.7–84.2)

CI: confidence interval; IDC: infiltrating ductal carcinoma; Chemo: chemotherapy; ILC: infiltrating lobular carcinoma.

In the intraoperative imprint cytology, the result was positive in 45 patients (42%), with macrometastasis present in 44 (97.78%) and micrometastasis in one (2.22%). Among these positive cases, 42 (93.33%) were true positives. Among the 165 (78.57%) negative intraoperative sentinel lymph nodes, 135 (81.81%) were true negatives. In the final histopathological study, 72 patients (34.28%) presented metastasis in the sentinel lymph node, with 56 (77.78%) macrometastases and 16 (22.22%) micrometastases. The sensitivity of the intraoperative study was 58.3% (95%CI 46.1–69.8) and the specificity was 97.8% (95%CI 93.8–99.5). The PPV was 93.3% (95%CI 81.7–98.6) and the NPV was 81.8% (95%CI 75.1–87.4) (Table 2).

Two of the three patients who presented false positive results were aged between 50 and 59 years, and one was aged over 70 years old. All of them had grade 2 infiltrating ductal carcinoma, positive hormone receptors and two presented neoplastic embolization in the histopathological result. One patient underwent axillary lymphadenectomy. None of the patients performed neoadjuvant chemotherapy. One case presented a tumor size equal to 5 cm, one equal to 2 cm, and another equal to 1 cm.

Among the 30 patients (14.29%) with false negative results, 12 (40%) were younger than 50 years, four (13.34%) were aged between 50 and 59 years, seven (23.33%) were aged between 60 and 69 years, and seven (23.33%) were older than 70 years. Twenty-six (86.6%) were positive hormones and 21 (70%) had infiltrating ductal carcinoma, of which eight were grade 3, seven (23.33%) were infiltrating lobular carcinoma, one (3.33%) papillary and one (3.33%) tubular. In the positive sentinel lymph nodes (30/210), there were 15 cases of macrometastasis and 15 cases of micrometastasis. Regarding tumor size, six (20%) had a mean of 1.28 cm, 21 (70%) of 3.32 cm and three (10%) with a mean of 7.5 cm. In two patients, axillary lymphadenectomy was performed at the same surgical time, and one case presented metastasis in the other lymph nodes, and 12 (40%) underwent axillary lymphadenectomy in a second procedure, of which five presented metastasis in the sentinel lymph node only. Among the 16 patients who were not submitted to axillary lymphadenectomy, 12 (75%) presented micrometastasis in the SLN.

Among the 45 patients who presented with positive intraoperative SLN, 40 underwent axillary lymph node dissection at the same surgical time, and two after the final histopathological study, totaling 42 (20%) patients with axillary lymph node

dissection after the SLN biopsy. Only 19 (45.24%) presented positive sentinel nodes, with a mean of 10.73 resected lymph nodes.

Regarding the variables studied in this cohort, the intraoperative study showed sensitivity of 50% (95%CI 29.1–70.9) and specificity of 100% (95%CI 86.3–100) in the patients aged under 50 years (23.33%). In the 50–59 age group (28.57%), sensitivity was 77.8% (95%CI 52.4–93.6) and specificity was 95.2% (95%CI 83.8–99.4). Among those aged 60–69 years (29.52%), sensitivity was 63.2% (95%CI 38.4–83.7) and specificity was 100% (95%CI 91.8–100). Among the patients aged over 70 years (18.57%), sensitivity was 36.4% (95%CI 10.9–69.2) and specificity was 96.4% (95%CI 81.7–99.9) (Figure 1).

Patients who underwent neoadjuvant chemotherapy (15/210) did not present positive lymph nodes in the intraoperative study. The true negatives corresponded to 80% of the cases and the false negatives to 20%. In the patients who did not undergo neoadjuvant chemotherapy, the true negatives were 63.07% and the false negatives 13.84%; the imprint sensitivity in these cases was 60.9% (95%CI 48.4–72.4).

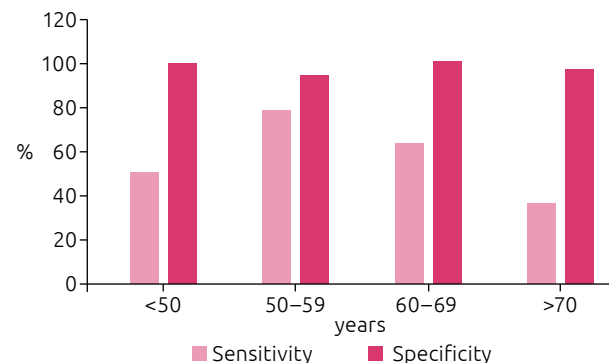
Regarding the histological type, in the patients with infiltrating ductal carcinoma, the intraoperative study presented a sensitivity of 61.8% (95%CI 47.7–74.6) and specificity of 97% (95%CI 91.4–99.4) with an NPV of 82.1% (95%CI 73.9–88.5). Among the patients with infiltrating lobular carcinoma, the sensitivity was 36.4% (95%CI 10.9–69.2) and 100% specificity (95%CI 69.2–100), with a negative predictive value of 58, 8% (95%CI 32.9–81.6). Other special subtypes resulted in sensitivity of 66.7% (95%CI 22.3–95.7) and specificity of 100% (95%CI 83.9–100) (Figure 2).

The T1 tumor size resulted in a sensitivity of 62.5% (95%CI 35.4–84.8), specificity of 96.7% (95%CI 88.7–99.6) and PPV of 83.3% (95%CI 51.6–97.9). Among patients with T2 tumors, the intraoperative study showed a sensitivity of 54.3% (95%CI 39–69.1) and specificity of 98.5% (95%CI 92.1–100) with PPV of 96.2% (95%CI 80.4–99.9). In those with T3 tumors, sensitivity was 70% (95%CI 34.8–93.3), 100% specificity (95%CI 66.4–100) and 100% PPV (95%CI 59–100).

In the cases with positive estrogen receptor, the sensitivity was 58.7% (95%CI 45.6–71) and the specificity was 97.2% (95%CI 92–99.4).

Table 2. Correlation between imprint cytology and definitive histopathological study.

Imprint cytology n (%)	Definitive histopathological study	
	Positive, n (%)	Negative, n (%)
Positive	45 (21.42)	42 (20) / 3 (1.42)
Negative	165 (78.58)	30 (14.29) / 135 (64.29)
Total	210 (100)	72 (34.29) / 138 (65.71)



IDC: Infiltrating ductal carcinoma; ILC: infiltrating lobular carcinoma.

Figure 1. Correlation between imprint cytology and age.

The positive predictive value was 92.5% (95%CI 79.6–98.4), and the negative predictive value was 80% (95%CI 72.1–86.5).

The presence of macrometastasis resulted in sensitivity in the intraoperative study of 73.2% (95%CI 59.7–84.2), and for micrometastasis, the sensitivity was 6.3% (95%CI 0.2–30.2), with significant difference. Among the 16 cases with micrometastasis, only one was intraoperatively positive, with 93.75% being false negative. In the 56 cases of macrometastasis, 41 were intraoperatively positive, with 26.78% being false negative (Figure 3).

The presence of neoplastic embolization in the final histopathological study resulted in sensitivity of 72.7% (95%CI 49.8–89.3) and specificity of 88.9% (95%CI 65.3–98.6), with a positive predictive value of 88.9% (95%CI 65.3–98.6). In cases without neoplastic embolization, sensitivity was 52% (95%CI 37.4–66.3) and specificity was 99.2% (95%CI 95.4–100).

DISCUSSION

Breast cancer is a common pathology among women and its incidence tends to increase with age. The aging of the population and the improved quality of life in the elderly population make it an important public health problem¹³. In the present study, 48.09% of the patients were aged 60 years or older, and the mean age was 59 years. These percentages are slightly lower than in other studies, which indicate that over 50% of breast cancer patients are aged 65 years or older, and about 30% are over 70 years of age^{14,15}.

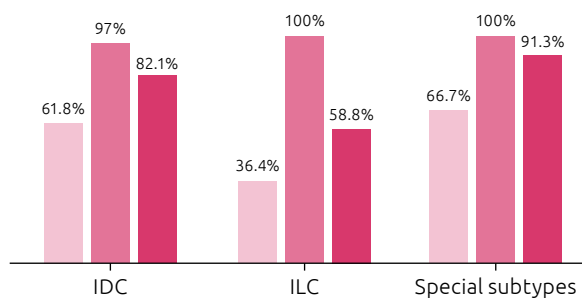


Figure 2. Correlation between imprint cytology and histological types.

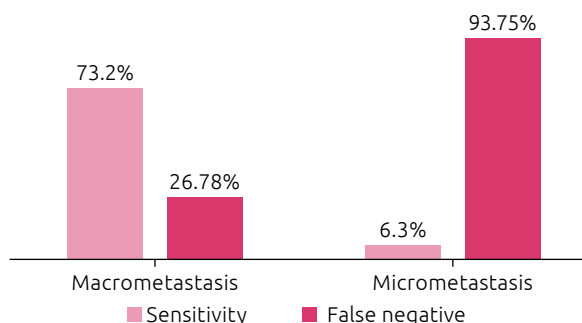


Figure 3. Correlation of sensitivity and false negative rate with lymph node metastasis size.

Strategies for the early detection of cancer are aimed at the diagnosis of cases in the early stages of their natural history. In middle- and low-income countries, breast cancers are predominantly diagnosed at more advanced stages¹⁶. In the present study, the tumors presented a mean of 2.86 cm in diameter and 57.14% of the patients had stage II breast cancer. As the accuracy of SLN in determining lymph node status in cancer is greater in the initial stage, smaller tumors are expected to be found in the SLN analysis studies, as can be observed in those carried out in first world countries, with an average of 12 to 15 mm, different from the results in this study^{17,18}.

The imprint sensitivity in the intraoperative study in our study was 58.3%, and the specificity was 97.8%. A study conducted by Pugliese et al., with 385 cases, presented results similar to the present study, with a sensitivity of 55% and specificity of 100%¹⁹. However, a study published in 2004 with 250 patients presented a low imprint sensitivity (34%), which is a consequence of the high proportion of micrometastases among their positive cases (42/102)²⁰. This variation in sensitivity can be evidenced in the meta-analysis published by Tew et al. in 2005, which analysed 31 studies and showed a mean sensitivity of 63%, ranging from 34 to 95%, and a mean specificity of 99%, varying from 94 to 99%²¹. The heterogeneity of these studies is explained by the inclusion criteria (tumor size, histological subtype, presence of palpable axillary lymph nodes), variations in the cytology technique and differences in the histological technique used by the laboratory to examine the removed lymph node (section thickness, inclusion of the entire lymph node region, and use of immunohistochemical techniques).

The cases of false positives were found in three sentinel lymph nodes from the studied sample. These cases were also reported by Lee et al. in 2002 and Ravichandran et al. in 2004, who found one between 155 and three out of 132 cases, respectively^{22,23}. False positives can be explained by the presence of isolated tumor cells ITC = or a focus of micrometastasis that are completely removed on the imprinted surface or by the presence of epithelial histiocytes, lymphocytes and tumefied endothelial cells that can be confused with tumor cells²¹.

When studying the variables, an increase in sensitivity could be observed in younger patients, aged under 60 years, which can be explained by the fact that these women tend to present bigger, more aggressive tumors, and higher histological grade. Consequently, lymph node metastases are greater and the cellular atypia is more marked, which makes cytology metastases easier to detect. Lorand et al. observed that patients ≤ 57 years of age presented significantly greater sensitivity and negative predictive value in relation to patients aged over 57 years. Sensitivity was also significantly higher among non-menopausal women in this study, which is probably related to the younger age of these patients¹⁷. In this study, non-menopausal women presented lower sensitivity than menopausal women, which can be explained by the low number of cases in this group.

In this casuistry, an increase was observed in the sensitivity of ductal carcinomas in lobular carcinomas and, as was the case in most of the literature, these values were not significant^{17,24,25}. In 2005, Cox et al., reported a 55.5% sensitivity in ductal carcinomas and 38.7 for lobular carcinomas, in the the detection of lymph node metastases at the intraoperative imprint ($p=0.012$)²⁶. This difference can be explained by the difficulty of intraoperative cytology analysis. According to Turner et al., the loss of e-cadherin results in an individual cell pattern in which metastatic lobular cells appear as small, regular, and round cells, making them difficult to distinguish from normal lymph node cells^{17,27}.

The intraoperative imprint sensitivity was higher among T3 tumors, although statistical significance was not observed. Zgajnar et al. presented significant values between intraoperative study sensitivity in tumors larger than 10 mm in comparison with those smaller than 10 mm, contraindicating the performance of intraoperative imprint for T1a and T1b tumors, justifying that such finding would occur due to the presence of a greater number of micrometastases in minor tumors²⁰. In this study, micrometastasis was observed in an 8 cm tumor and, in 15 cases of T1 and T2 tumors, with a mean tumor size of 2.94 cm.

The sensitivity did not change in relation to the presence of the hormonal receptors. This result was similar to that of Lorand et al., who also did not find significant results¹⁷. These results can be explained by the association of hormonal receptors with smaller tumors, with lower histological and nuclear grade, and a better prognosis²⁸.

The presence of neoplastic vascular embolization demonstrated an increase in sensitivity in the sample studied. In a study published in 2011, this relationship was significant ($p=0.04$)¹⁷. These findings are explained by the fact that lymph node metastasis is more frequent in the presence of vascular embolism.

In all patients submitted to neoadjuvant chemotherapy (15 cases), the intraoperative imprint cytology was negative. In twelve cases (80%), there was agreement between the imprint cytology and the histopathological study. Only three cases (20%)

were positive for the definitive histopathological study and negative for the imprint, two with macrometastasis and one with micrometastasis. Jain et al. evaluated the reliability of imprint in the detection of axillary lymph node metastasis after neoadjuvant chemotherapy and demonstrated a 100% agreement between cytology evaluation and definitive histopathology. Among the 17 patients evaluated in the neoadjuvant group, nine (53%) were positive and eight were negative (47%)²⁹. In the study conducted by Miller et al., intraoperative results showed to be in agreement with the final histology in 79% of the patients, demonstrating that the sensitivity of the intraoperative study is not significantly altered by chemotherapy³⁰.

This study concludes detection of micrometastases with intraoperative imprint is difficult, since the sensitivity is 6.3%, while the sensitivity of macrometastase detection is 73.2% with significant analysis. This is one of the findings presented by Tew et al. in the meta-analysis, in which the mean sensitivity of the detection of micrometastases with the cytology method was 22%, while that of the macrometastases was 81%²¹. Pugliese et al. demonstrated an increase in imprint sensitivity with increased SLN metastasis size, with results equal to 0, 4 and 74%, respectively, in lymph nodes with ITC, micrometastasis and macrometastasis¹⁹. The data found here were similar to that found by Cox et al., which found sensitivity of 6.4% for micrometastasis and 69.3% for macrometastasis²⁶.

CONCLUSION

Imprint cytology in the intraoperative examination is a fast, inexpensive method, and does not involve any loss of lymph node tissue that could compromise the definitive histological analysis, as well as showing good accuracy in predicting axillary status. Patient selection based on clinical and histological criteria may improve the sensitivity of the method. However, the only variable that resulted in a significant increase in sensitivity in this study was the presence of macrometastasis.

REFERENCES

1. Brasil. Ministério da Saúde. Secretaria de Atenção à Saúde. Instituto Nacional do Câncer José Gomes de Alencar. Coordenação de Prevenção e Vigilância de Câncer. Estimativa 2016: Incidência de Câncer no Brasil. Rio de Janeiro: Instituto Nacional do Câncer José Gomes de Alencar; 2016 [acessado em 12 jan. 2018]. Disponível em: <http://santacasadermatoazulay.com.br/wp-content/uploads/2017/06/estimativa-2016-v11.pdf>
2. Fisher B., Jeong JH., Anderson S., Bryant J., Fisher ER., Wolmark N. Twenty-five-year follow-up of a randomized trial comparing radical mastectomy, total mastectomy, and total mastectomy followed by irradiation. *N Engl J Med.* 2002;347(8):567-75. <https://doi.org/10.1056/NEJMoa020128>
3. Veronesi U, Saccozzi R, Del Vecchio M, Banfi A, Clemente C, De Lena M, et al. Comparing radical mastectomy with quadrantectomy, axillary dissection, and radiotherapy in patients with small cancers of the breast. *N Engl J Med.* 1981;305:6-11. <https://doi.org/10.1056/NEJM19810723050102>
4. Hoe AL, Iven D, Royle GT, Taylor I. Incidence of arm swelling following axillary clearance for breast cancer. *Br J Surg.* 1992;79(3):261-2.
5. Roses DF, Brooks AD, Harris MN, Shapiro RL, Mitnick J. Complications of Level I and II Axillary Dissection in the Treatment of Carcinoma of the Breast. *Ann Surg.* 1999;230(2):194-201.

6. Cabanas RM. An approach for the treatment of penile carcinoma. *Cancer*. 1977;39:456-66.
7. Giuliano AE, Kirgan DM, Guenther JM, Morton DL. Lymphatic mapping and sentinel lymphadenectomy for breast cancer. *Ann Surg*. 1994;220(3):391-401.
8. Keshtgar M, Aresti N, Macneil F. Establishing axillary Sentinel Lymph Node Biopsy (SLNB) for early breast cancer in the United Kingdom: a survey of the national training program. *Eur J Surg Oncol*. 2010;36(4):393-8. <https://doi.org/10.1016/j.ejso.2009.10.012>
9. Giuliano AE, Haigh PI, Brennan MB, Hansen NM, Kelley MC, Ye W, et al. Prospective observational study of sentinel lymphadenectomy without further axillary dissection in patients with sentinel node-negative breast cancer. *J Clin Oncol*. 2000;18:2553-9. <https://doi.org/10.1200/JCO.2000.18.13.2553>
10. Veronesi U, Paganelli G, Viale G, Luini A, Zurrada S, Galimberti V, et al. A randomized comparison of sentinel-node biopsy with routine axillary dissection in breast cancer. *N Engl J Med*. 2003;349:546-53. <https://doi.org/10.1056/NEJMoa012782>
11. Giuliano AE, McCall L, Beitsch P, Whitworth PW, Blumencranz P, Leitch AM, et al. Locoregional recurrence after sentinel lymph node dissection with or without axillary dissection in patients with sentinel lymph node metastases: the American College of Surgeons Oncology Group Z0011 randomized trial. *Ann Surg*. 2010 Sep;252(3):426-32. <https://doi.org/10.1097/SLA.0b013e3181f08f32>
12. Turner RR, Giuliano AE. Intraoperative pathologic examination of the sentinel lymphnode. *Ann Surg Oncol*. 1998;5:670-2.
13. Elomrani F, Zine M, Afif M, L'annaz S, Ouziane I, Mrabti H, et al. Management of early breast cancer in older women: from screening to treatment. *Breast Cancer*. 2015;7:165-71. <https://dx.doi.org/10.2147%2FBCCTT.S87125>
14. Binder-Foucard F, Bossard N, Delafosse P, Belot A, Woronoff AS, Remontet L. Incidence and mortality of cancer in France during the period 1980–2012: solid tumors. *J Epidemiol Publ Health*. 2014;62(2):95-108. <https://doi.org/10.1016/j.respe.2013.11.073>
15. Yancik R, Ries LA. Cancer in older persons: an international issue in an aging world. *Semin Oncol*. 2004;31(2):128-36.
16. Instituto Nacional de Câncer José Alencar Gomes da Silva. Diretrizes para a detecção precoce do câncer de mama no Brasil/Instituto Nacional de Câncer José Alencar Gomes da Silva. Rio de Janeiro: Instituto Nacional de Câncer José Alencar Gomes da Silva; 2015.
17. Lorand S, Lavoue V, Tas P, Foucher F, Mesbah H, Rouquette S, et al. Intraoperative touch imprint cytology of axillary sentinel nodes for breast cancer: A series of 355 procedures. *Breast*. 2011;20:119-23. <https://doi.org/10.1016/j.breast.2010.08.004>
18. Turner RR, Hansen NM, Stern SL, Giuliano AE. Intraoperative examination of the sentinel lymph node for breast carcinoma staging. *Am J Clin Pathol*. 1999;112:627-34.
19. Pugliese MS, Kohr JR, Allison KH, Wang NP, Tickman RJ, Beatty JD. Accuracy of intraoperative imprint cytology of sentinel lymph nodes in breast cancer. *Am J Surg*. 2006;192(4):516-9. <https://doi.org/10.1016/j.amjsurg.2006.05.014>
20. Zgajnar J, Frkovic-Grazio S, Besic N, Hocevar M, Vidergar-Kralj B, Gerljevic A, et al. Low sensitivity of the touch imprintcytology of the sentinel lymph node in breast cancer patients results of a large series. *J Surg Oncol*. 2004;85(2):82-6. <https://doi.org/10.1002/jso.20011>
21. Tew K, Irwig L, Matthews A, Crowe P, Macaskill P. Meta-analysis of sentinel node imprint cytology in breast cancer. *Br J Surg*. 2005;92(9):1068-80. <https://doi.org/10.1002/bjs.5139>
22. Lee A, Krishnamurthy S, Sahin A, Symmans WF, Hunt K, Sneige N. Intraoperative touch imprint of sentinel lymphnodes in breast carcinoma patients. *Cancer*. 2002;96:225-31. <https://doi.org/10.1002/cncr.10721>
23. Ravichandran D, Kocjan G, Falzon M, Ball RY, Ralphs DN. Imprint cytology of the sentinel lymph node in the assessment of axillary node status in breast carcinoma. *Eur J Surg Oncol*. 2004;30:238-42. <https://doi.org/10.1016/j.ejso.2003.11.005>
24. Molland JG, Donnellan M, Janu NC, Carmalt HL, Kennedy CW, Gillett DJ. Infiltrating lobular carcinoma--a comparison of diagnosis, management and outcome with infiltrating duct carcinoma. *Breast*. 2004;13(5):389-96. <https://doi.org/10.1016/j.breast.2004.03.004>
25. Creager AJ, Geisinger KR, Perrier ND, Shen P, Shaw JA, Young PR, et al. Intraoperative imprint cytology evaluation of sentinel lymph nodes for lobular carcinoma of the breast. *Ann Surg*. 2004;239(1):61-6. <https://dx.doi.org/10.1097%2F01.sla.0000103072.34708.e3>
26. Cox C, Centeno B, Dickson D, Clark J, Nicosia S, Dupont E, et al. Accuracy of intraoperative imprint cytology for sentinel lymph node evaluation in the treatment of breast carcinoma. *Cancer*. 2005;105:13-20. <https://doi.org/10.1002/cncr.20738>
27. Turner RR, Weaver DL, Cserni G, Lester SC, Hirsch K, Elashoff DA, et al. Nodal stage classification for breast carcinoma: improving interobserver reproducibility through standardized histologic criteria and image-based training. *J Clin Oncol*. 2008;26:258-63. <https://doi.org/10.1200/JCO.2007.13.0179>
28. Eisenberg ALA, Koifman S. Câncer de mama: marcadores tumorais (revisão de literatura). *Rev Bras Cancerol*. 2001;47(4):377-8.
29. Jain P, Kumar R, Anand M, Asthana S, Deo SV, Gupta R, et al. Touch imprint cytology of axillary lymph nodes after neoadjuvant chemotherapy in patients with breast carcinoma. *Cancer*. 2003;99:346-51. <https://doi.org/10.1002/cncr.11825>
30. Miller AR, Thomason VE, Yeh IT, Alrahwan A, Sharkey FE, Stauffer J, et al. Analysis of sentinel lymph node mapping with immediate pathologic review in patients receiving preoperative chemotherapy for breast carcinoma. *Ann Surg Oncol*. 2002;9:243-7.