







Bilateral risk-reducing mastectomy in a patient over 50 years of age: case report with an emphasis on the psychological aspect in the face of serious complications

Rafael Everton Assunção Ribeiro da Costa^{1*} , João Victor Caminha Lustosa Falcão² , Liana Carrias Bruno² , Marianne Magalhães Fortes² , Ana Lúcia Nascimento Araújo³ , Sabas Carlos Vieira⁴ 

ABSTRACT

Malignant breast neoplasia is the main cause of cancer mortality in women in Brazil, after non-melanoma skin cancer, and about 5 to 10% of these cases are associated with family inheritance; BRCA1 and BRCA2 genes are the most frequently mutated. In this sense, there has been a paradigm shift in medical practice regarding breast cancers in recent years, with the implementation of risk-reducing surgical procedures, such as bilateral mastectomy and salpingo-oophorectomy, which still have controversies in the indication, in addition to fears and sufferings of patients, before and after the procedure. A 54-year-old female patient has been undergoing routine examinations since 2009 (49 years), as she has a family history of breast cancer. In May 2014 (54 years old), the patient underwent genetic research, discovering the pathogenic 648delT mutation in heterozygosity in the BRCA1 gene. Although complementary exams did not indicate any neoplasia, the patient wanted to undergo risk-reducing surgery. After interprofessional discussion with the patient, bilateral risk-reducing mastectomy and salpingo-oophorectomy were performed. The patient had a postoperative infection, and one of the silicone prostheses was removed from her breast. In 2015 (55 years old), she underwent a new prosthesis inclusion, evolving without complications. Currently, she is being followed up and without evidence of active cancer disease. Despite the complication with the prosthesis, there was an improvement in psychological aspects that bothered her, referring to a reduction in anxiety and fear of cancer. Although beneficial, risk-reducing mastectomy has associated risks, especially in patients with advanced age and comorbidities. However, with an appropriate approach and focused on the complexities of each person, it is possible to provide the patient with a better overall psychological experience, as demonstrated in this case reported.

KEYWORDS: Mutation; Genes, BRCA1; Breast neoplasms; Prophylactic mastectomy; Salpingo-oophorectomy; Middle aged.

INTRODUCTION

According to data from the National Cancer Institute José Alencar Gomes da Silva (*Instituto Nacional de Câncer José Alencar Gomes da Silva* – INCA), malignant breast neoplasms are the main cause of cancer mortality among women in Brazil, after non-melanoma skin cancer.¹ Estimates show that from 5% to 10% of breast cancer cases are hereditary, and in these cases, they appear at an early age, in a bilateral way and affecting several generations.²

Mutations in the BRCA1 and BRCA2 genes represent about 20% of cases of hereditary breast cancer, which can lead to a

cumulative risk of developing the disease of about 50% to 80%.² As a result, risk-reducing surgeries are proposed for patients with pathogenic mutations in high penetration genes (BRCA, TP53, CHECK2, PALB2, PTEN) around 35–40 and 40–45 years old, in individuals with BRCA1 and BRCA2 mutations, respectively.^{3,4}

Surgical risk reduction procedures, especially bilateral mastectomy, have a great impact on patients' psychological aspects because they involve organs associated with sexuality, self-esteem, and self-perception of women's self-image.^{5,6} Therefore, considering the psychological aspects involved in these procedures is

¹Universidade Estadual do Piauí – Teresina (PI), Brazil.

²Centro Universitário Uninovafapi – Teresina (PI), Brazil.

³Hospital São Marcos – Teresina (PI), Brazil.

⁴Tocoginecologia, Oncocenter – Teresina (PI), Brazil.

*Corresponding author: rafaelearcosta@gmail.com

Conflict of interests: nothing to declare.

Received on: 09/02/2020. Accepted on: 09/22/2020

essential, and considering the complexity of each patient is also important, which makes interprofessionality necessary when approaching of these cases.^{5,6}

Given the importance of malignant breast neoplasms in the context of women's health and, more recently, the paradigm changes in the care model to patients with a family history of breast cancer, especially those germinative mutations of high penetration, we report a case of risk-reducing mastectomy in a patient over 50 years of age with a mutation in the BRCA1 gene that presented postoperative complications, and we evaluated the possible psychological impacts of surgery and complications for her quality of life.

CASE REPORT

A 54-year-old female patient has been undergoing routine examinations since 2009 (49 years old), as she has a family history of breast cancer: a sister who died at 52, and another sister who was diagnosed with the disease at 50, as well as their mother, who died at the age of 55, two maternal aunts, and two maternal cousins (one died under 50, and the other was diagnosed with breast cancer at 32), as well as a niece diagnosed at 34 (Figure 1).

In May 2014 (54 years old), the patient undertook genetic research for a specific BRCA1 mutation present in the family, and the pathogenic 648delT mutation was detected in heterozygosis. Breast MRI was normal. The possibility of bilateral mastectomy

and risk-reducing salpingo-oophorectomy was discussed with the patient on several occasions. She was afraid of developing breast cancer and dying due to her family history, because several members of her family died due to disease progression in the productive phase of life. The patient had difficulties in understanding the surgeries and surgical risks involved, as well as the low impact on reducing mortality in patients over 50 years of age.

The patient had the option of using chemoprophylaxis with tamoxifen for five years, annual follow-up with breast MRI, and mammography and transvaginal ultrasound and semiannual CA 125, highlighting the fact that there is no evidence of reduced mortality from ovarian cancer by screening with transvaginal ultrasound and CA 125.⁷

The patient was referred to psychotherapy because she was very confused. She was not sure how much the risk of developing breast cancer would be reduced with prophylactic surgery, besides the fact that her health insurance not having authorized the procedures. After extensive discussion with the patient, her family and psychologist, a decision was made to reduce the risk of breast and ovarian cancer after informed consent.

Bilateral mastectomy and risk-reducing salpingo-oophorectomy were performed, and breast reconstruction with the inclusion of a bilateral subpectoral prosthesis was also carried out. On the 14th postoperative day, the surgical wound showed necrosis of the lower part of the complete right papillary artery, and debridement was performed. On the 35th postoperative day, the patient

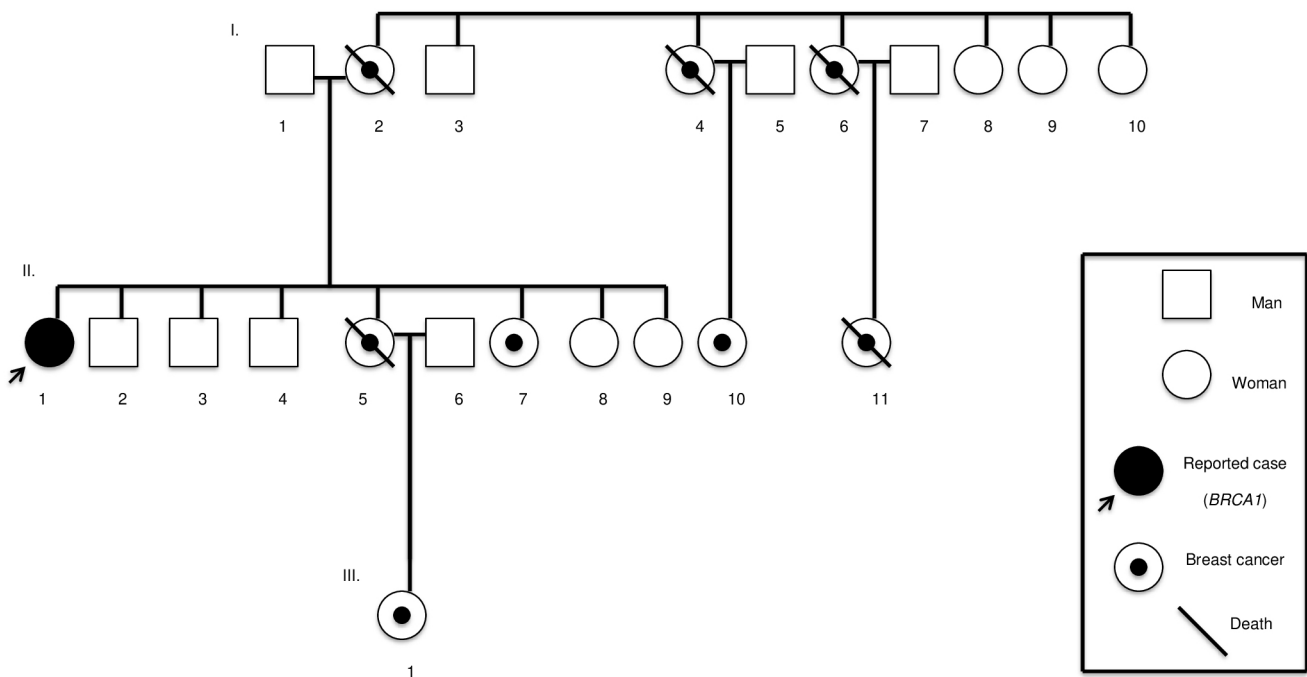


Figure 1. Heredogram of the family history of breast cancer in the reported case of a BRCA1 patient over 50 years of age who underwent bilateral risk-reducing mastectomy.

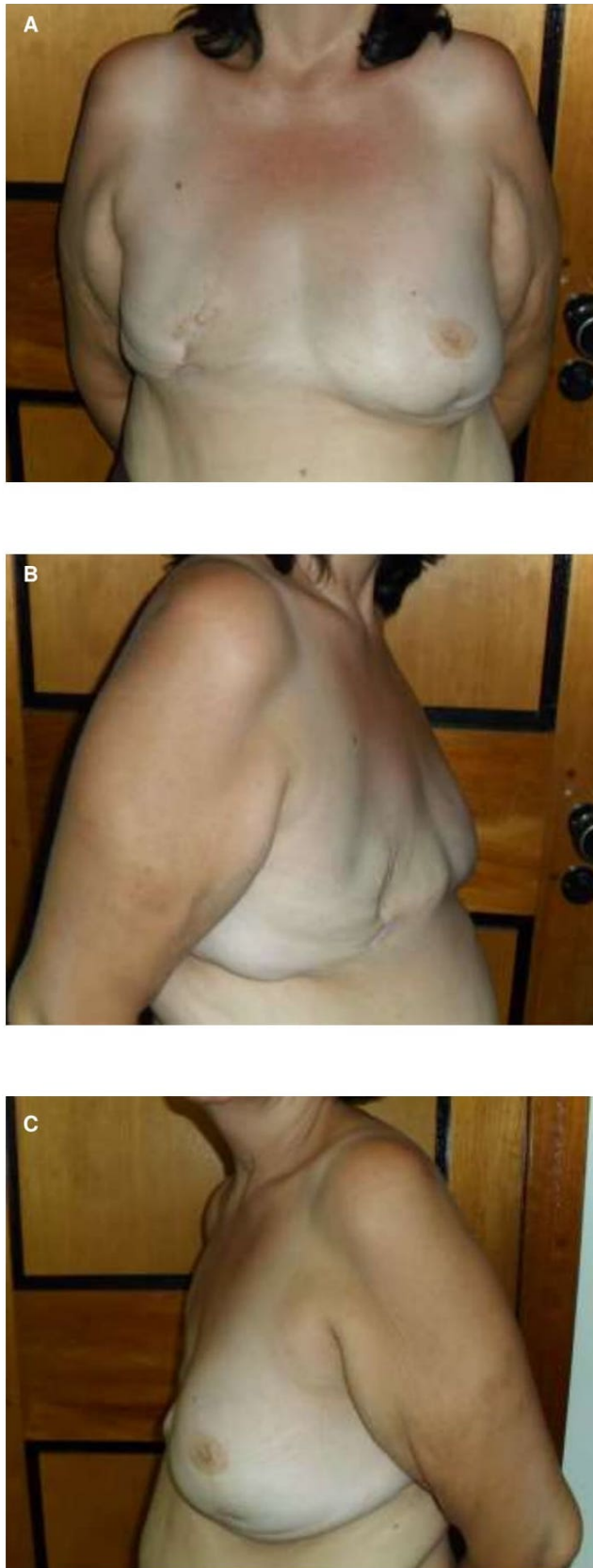

Figure 2. Final aspect of bilateral risk-reducing mastectomy with complications in a patient over 50 years of age. (A) Front view; (B) right side view; (C) left side view.

had dehiscence at angles of the submammary fold and necrosis of the papillae, and debridement was performed, but without prosthesis exposure and without seroma. On the 67th postoperative day, the right prosthesis was removed due to infection and the material was sent for culture, growing *Streptococcus agalactiae*. Since then, it has evolved well with surgical site healing.

Histological examination with specific protocol with serial cuts of the specimens of the breast, ovaries, and tubes did not detect any neoplasia.

In 2015 (55 years old), the patient underwent a new breast implant on her right breast, evolving without complications. Currently, she is being followed up and presents no evidence of active cancer disease (Figure 2). The patient, despite the complication with the prosthesis, showed improvement in psychological aspects that bothered her, referring to reduced anxiety and fear of developing cancer.

The study protocol was approved by the Research Ethics Committee (CEP) of Universidade Federal do Piauí (UFPI), Teresina City, Piauí State, Brazil, under CAAE No. 94518518.9.0000.5214, which includes the study of patients with breast cancer. The precepts contained in the resolution of the National Health Council No. 466/12 were observed.

DISCUSSION

Monteiro et al. pointed out in their study that, among women undergoing risk-reducing mastectomy, 30% have postoperative complications, such as bruising, infection and implant rupture, and 49% regret having the procedure performed.⁸

In the present study, the patient had complications, requiring the removal of the prosthesis and posterior surgery to place another prosthesis on her right breast. Despite these significant complications, she reported improvement in psychological aspects that bothered her, referring to less anxiety and fear of death from breast cancer. Therefore, a well-prepared preoperative discussion, which considers all dimensions of human nature, can be a key element for improving well-being and quality of life after risk-reducing bilateral mastectomy, even when there are complications, just like in the case reported, also affecting the general motivation in relation to the procedure.

Comorbidities that may increase the risk of complications, such as significant heart or lung disease, obesity, diabetes, smoking, steroid use, or chronic anticoagulation⁹ should also be considered upon surgery indication of surgery. The occurrence of these complications is due to vascular microlesions, either due to trauma during the handling of the skin flap of the breast envelope, or due to the patient's intrinsic conditions.⁹ In the present case, the patient did not present comorbidities.

Bilateral prophylactic mastectomy reduces the risk of developing breast cancer by about 90% to 95% in carriers of mutations in the BRCA10 genes. In addition to reducing the incidence of

malignant breast neoplasms, prophylactic procedures are associated with improving psychological aspects, such as reducing the fear of developing cancer and dying early, which is common in women with a family history.¹⁰

In a previous study by Giannakeas and Narod, they pointed out that the chances of being alive at the age of 80 after a mastectomy procedure at the age of 25 increased by 8.7% (from 42.7% to 51.3%). However, the estimated benefit when surgery is performed at 50 years of age is very small (2.8% at 80 years; from 42.7% to 45.5%).¹¹ Bilateral risk-reducing salpingo-oophorectomy alone decreases mortality from breast and ovarian cancer, in addition to decreasing the risk of breast cancer by 50% when performed before the age of 50. Therefore, such procedure must be discussed with these patients.^{3,4} The patient in the present case did not accept performing only salpingo-oophorectomy.

Even with a small survival benefit, the patient's quality of life must be considered. The fact that these women with pathogenic mutations who have not yet developed cancer have seen suffering and deaths in close family members due to breast cancer sometimes leads to intense suffering. Risk-reducing surgeries should only be performed after extensive discussion with a multidisciplinary team and effective patient participation, clarifying all the complications involved, including the aesthetic sequelae, often irreparable. In the present case, even in the face

of a serious complication, the patient accepted it well and has a good quality of life.

CONCLUSION

Although beneficial, risk-reducing mastectomy, like any surgery, presents associated risks, especially in old age and in the presence of comorbidities. However, with an appropriate approach and focused on the complexities of each individual, providing the patient with a better overall psychological experience is possible, with improved perception of anxiety and decreased fear of falling ill and dying early, just like demonstrated in the case reported.

AUTHORS' CONTRIBUTION

R.E.A.R.C.: study concept, data curation, formal analysis, methodology, project management, writing – original draft, writing – review & editing.

J.V.C.L.F.: study concept, data curation, formal analysis, methodology, project management, writing – original draft.

L.C.B.: data curation, research, methodology.

M.M.F.: data curation, research, methodology.

A.L.N.A.: formal analysis, methodology.

S.C.V.: formal analysis, methodology, writing – review & editing.

REFERENCES

1. Brazil. Ministério da Saúde. Instituto Nacional de Câncer José Alencar Gomes da Silva (INCA). Coordenação de Prevenção e Vigilância. Estimativa 2020: incidência de câncer no Brasil [Internet]. Rio de Janeiro: Ministério da Saúde; 2019 [accessed on Mar 16, 2020]. Available on: <https://www.inca.gov.br/sites/ufu.sti.inca.local/files/media/document/estimativa-2020-incidencia-de-cancer-no-brasil.pdf>
2. Amendola LCB, Vieira R. A contribuição dos genes BRCA na predisposição hereditária ao câncer de mama. *Rev Bras Cancerol.* 2005;51(4):325-30.
3. Coelho AS, Santos MAS, Caetano RI, Piovesan CF, Fiuza LA, Machado RLD, et al. Predisposição hereditária ao câncer de mama e sua relação com os genes BRCA1 e BRCA2: revisão da literatura. *RBAC.* 2018;50(1):17-21. <http://doi.org/10.21877/2448-3877.201800615>
4. Cabello C. Histerectomia durante a salpingooforectomia redutora de risco em mulheres com mutações deletérias nos genes brca1 ou brca2. Indicar ou não? *Rev Bras Mastologia.* 2017;27(1):1-2. <http://doi.org/10.5327/Z201700010001RBM>
5. Almeida RA. Impacto da mastectomia na vida da mulher. *Rev SBPH.* 2006;9(2):99-113.
6. Cesnik VM, Santos MA. Mastectomia e sexualidade: uma revisão integrativa. *Psicol Reflex Crit.* 2012;25(2):339-49. <https://doi.org/10.1590/S0102-79722012000200016>
7. Rebbeck TR, Friebel T, Lynch HT, Neuhausen SL, Van't Veer L, Garber JE, et al. Bilateral prophylactic mastectomy reduces breast cancer risk in BRCA1 and BRCA2 mutation carriers: the PROSE Study Group. *J Clin Oncol.* 2004;22(6):1055-62. <https://doi.org/10.1200/jco.2004.04.188>
8. Monteiro GA, Novaes JR, Carvalho Júnior JD, Rio JA, Ribeiro LLS, Silva LP, et al. O dilema da decisão de Mastectomia Bilateral como prevenção do Câncer de Mama: aspectos éticos e bioéticos. *Revista Bioethikos - Centro Universitário São Camilo.* 2011;5(4):443-50.
9. Cowen D, Gross E, Rouannet P, Teissier E, Ellis S, Resbeut M, et al. Immediate post-mastectomy breast reconstruction followed by radiotherapy: risk factors for complications. *Breast Cancer Res Treat.* 2010;121(3):627-34. <https://doi.org/10.1007/s10549-010-0791-5>
10. Ludwig KK, Neuner J, Butler A, Geurts JL, Kong AL. Risk reduction and survival benefit of prophylactic surgery in BRCA mutation carriers, a systematic review. *The Am J Surg.* 2016;212(4):660-9. <https://doi.org/10.1016/j.amjsurg.2016.06.010>
11. Giannakeas V, Narod SA. The expected benefit of preventive mastectomy on breast cancer incidence and mortality in BRCA mutation carriers, by age at mastectomy. *Breast Cancer Res Treat.* 2018;167(1):263-7. <https://doi.org/10.1007/s10549-017-4476-1>

