

# MASTOLOGY

*Official Journal of the Brazilian Society of Mastology*

Volume 29, Number 3, July-September 2019

ISSN 2594-5394



Sociedade Brasileira de  
**Mastologia**



# O MELHOR DA MASTOLOGIA MUNDIAL ESPERA POR VOCÊ EM

# 2020

PRESENCAS CONFIRMADAS!



**Christopher Comstock** (EUA)




**Lisa Newman** (EUA)



**Abram Recht** (EUA)



**Monica Morrow** (EUA)



## XXIII CONGRESSO BRASILEIRO DE MASTOLOGIA

**1 A 4 DE ABRIL 2020**  
CENTRO SUL - FLORIANÓPOLIS

**INSCREVA-SE:**  
**MASTOLOGIA2020**  
**.COM.BR**



Realização



Organização



Comunicação



# MASTOLOGY

*Official Journal of the Brazilian Society of Mastology*

---

Volume 29, Number 3, July-September 2019

---

## **EDITOR-IN-CHIEF**

Cícero Urban (Curitiba, PR, Brazil)

---

## **CO-EDITORS**

Fabio Postiglione Mansani (Ponta Grossa, PR, Brazil)

René Aloisio da Costa Vieira (Barretos, SP, Brazil)

Ruffo de Freitas Júnior (Goiânia, GO, Brazil)

## **SPECIALTY EDITORS: MASTOLOGY**

Alfredo Carlos D. de Barros (São Paulo, SP, Brazil)

Antonio Frasson (São Paulo, SP, Brazil)

Cesar Cabello dos Santos (Campinas, SP, Brazil)

Daniel Guimarães Tiezzi (Ribeirão Preto, SP, Brazil)

Délio Conde (Goiânia, GO, Brazil)

Fabrcio Brenelli (Campinas, SP, Brazil)

Gil Facina (Sao Paulo, SP, Brazil)

Gustavo Zucca Matthes (Barretos, SP, Brazil)

José Luis Bevilacqua (São Paulo, SP, Brazil)

José Luis Pedrini (Porto Alegre, RS, Brazil)

José Mauro Secco (Macapá, AP, Brazil)

Jose Roberto Filassi (São Paulo, SP, Brazil)

José Roberto Piato (São Paulo, SP, Brazil)

Jurandyr Moreira Andrade (Ribeirão Preto, SP, Brazil)

Maira Caleffi (Porto Alegre, RS, Brazil)

Regis R. Paulinelli (Goiânia, GO, Brazil)

Renato Zocchio Torresan (Campinas, SP, Brazil)

Roberto Vieira (Rio de Janeiro, RJ, Brazil)

Rodrigo Gonçalves (São Paulo, SP, Brazil)

Sabas Carlos Vieira (Teresina, PI, Brazil)

Vinicius Milani Budel (Curitiba, PR, Brazil)

## **INTERNATIONAL ADVISORY BOARD**

Benjamin Anderson (Seattle, USA)  
Eduardo Gonzáles (Buenos Aires, Argentina)  
Gail Lebovic (Dallas, USA)  
Luciane Cavalli (Washington, USA)  
Luiz Javier Gallón (Medellin, Colombia)  
Jaime Letzkus Berríos (Santiago, Chile)  
Juan Enrique Bargallo Rocha (Mexico City, Mexico)  
Mahmoud El-Tamer (New York, USA)  
Maria João Cardoso (Lisbon, Portugal)  
Marcelo Cruz (Chicago, USA)  
Mario Rietjens (Milan, Italy)  
Matthew Ellis (Houston, USA)  
Melissa Bondy (Houston, USA)  
Richard Raisburry (Winchester, UK)  
Rui Manoel dos Reis (Minho, Portugal)  
Vesna Bjelic Radisic (Graz, Austria)  
Virgilio Sacchini (Milan, Italy)

## **SPECIALTY EDITORS: PATHOLOGY**

Angela F. Logullo (São Paulo, SP, Brazil)  
Filomena Carvalho (São Paulo, SP, Brazil)  
Helenice Gobbi (Belo Horizonte, MG, Brazil)

## **SPECIALTY EDITOR: PHYSIOTHERAPY**

Anke Bergman (Rio de Janeiro, RJ, Brazil)

## **SPECIALTY EDITOR: TRANSLATIONAL RESEARCH**

Ismael Dale Cotrim Guerreiro da Silva (São Paulo, SP, Brazil)

## **SPECIALTY EDITORS: GENETICS**

José Cláudio Casali da Rocha (Curitiba, PR, Brazil)  
Maria Isabel Achatz (São Paulo, SP, Brazil)

## **SPECIALTY EDITORS: MEDICAL ONCOLOGY**

Carlos Barrios (Porto Alegre, RS, Brazil)  
Max Mano (São Paulo, SP, Brazil)  
Sérgio Simon (São Paulo, SP, Brazil)

## **SPECIALTY EDITORS: RADIOTHERAPY**

Nilceana Maya Aires Freitas (Goiânia, GO, Brazil)  
Robson Ferrigno (Campinas, SP, Brazil)  
Samir Abdullah Hanna (Sao Paulo, SP, Brazil)

## **SPECIALTY EDITORS: RADIOLOGY**

Helio Amâncio Camargo (Campinas, SP, Brazil)  
Simone Elias (São Paulo, SP, Brazil)

## **SPECIALTY EDITORS: EPIDEMIOLOGY AND PREVENTION**

Edesio Martins (Goiás, GO, Brazil)  
Luiz Cláudio Santos Thuler (Rio de Janeiro, RJ, Brazil)  
Maria Paula Curado (Goiania, GO, Brazil)



## FORMER PRESIDENTS

Alberto Lima de Morais Coutinho (1959–1961)  
Jorge de Marsillac (1962–1963)  
Eduardo Santos Machado (1964–1965)  
Carlos A. M. Zanotta (1966–1967)  
Alberto Lima de Morais Coutinho (1968–1969)  
Adayr Eiras de Araújo (1970–1971)  
João Luiz Campos Soares (1972–1973)  
Jorge de Marsillac (1974–1975)  
Alberto Lima de Morais Coutinho (1976–1977)  
João Sampaio Góis Jr. (1978–1982)  
Hiram Silveira Lucas (1983–1986)  
José Antonio Ribeiro Filho (1987–1989)  
Antônio S. S. Figueira Filho (1990–1992)  
Marconi Menezes Luna (1993–1995)  
Henrique Moraes Salvador Silva (1996–1998)  
Alfredo Carlos S. D. Barros (1999–2001)  
Ezio Novais Dias (2002–2004)  
Diógenes Luiz Basegio (2005–2007)  
Carlos Ricardo Chagas (2008–2010)  
Carlos Alberto Ruiz (2011–2013)  
Ruffo de Freitas Júnior (2014–2016)



## SOCIEDADE BRASILEIRA DE MASTOLOGIA

Praça Floriano, 55, sala 801, Centro – 20031-050 – Rio de Janeiro (RJ)  
Phone numbrs: (21) 2220-7711 / (21) 2220-7111  
E-mail: secretaria@sbmastologia.com.br

## ABOUT

Mastology is a quarterly publication of the Brazilian Society of Mastology. The responsibility for concepts emitted in the articles is exclusive of its authors

The total or partial reproduction of the articles is allowed, provided the source is mentioned.

Founder: Antônio Figueira Filho

Submissions - mailing address: Praça Floriano, 55, sala 801, Centro – Rio de Janeiro (RJ) – 20031-050

National and international subscription and advertising: Sociedade Brasileira de Mastologia - Phone number: (21) 2220-7711

## NATIONAL BOARD OF DIRECTORS OF SOCIEDADE BRASILEIRA DE MASTOLOGIA

### Triennium 2017-2019

#### Founder:

Alberto Lima de Morais Coutinho  
Antonio Luiz Frasson (RS)  
Vilmar Marques de Oliveira (SP)  
Cynthia Mara Brito Lins Pereira (PA)  
Roberto Kepler da Cunha Amaral (BA)  
Fabio Postiglione Mansani (PR)  
Felipe Eduardo Martins de Andrade (SP)  
Rodrigo Pepe Costa (DF)  
Rafael Henrique Szymanski Machado (RJ)  
Clécio Ênio Murta de Lucena (MG)  
José Ricardo Conte de Souza (RJ)  
Marco Antonio Nasser Aguiar (CE)  
Cícero de Andrade Urban (PR)  
José Luiz Pedrini  
Vinícius Milani Budel (PR)  
Fabrício Palermo Brenelli (SP)  
Felipe Pereira Zerwes (RS)  
Antonio Fortes de Pádua Filho (PI)  
Augusto Tufi Hassan (BA)  
Bárbara Pace Silva de Assis (MG)  
Carlos Henrique Menke (RS)  
Ivo Carelli Filho (SP)  
Luciana Naíra de Brito Lima Limongi (PE)  
Mônica Vieira M. Travassos Jourdan (RJ)  
Paula Cristina Saab (SE)

President  
National Vice President  
North Region Vice President  
Northeast Region Vice President  
South Region Vice President (Site)  
Southeast Region Vice President  
Midwest Region Vice President  
General secretary  
Assistant Secretary  
General Treasurer  
Assistant Treasurer  
Mastology Editor  
Mastologia News Editor  
Escola Brasileira de Mastologia Director  
Escola Brasileira de Mastologia Vice Director  
Mastology Specialist Title (TEMa)  
Special Counseling

#### PRODUÇÃO EDITORIAL



**FILANTROPIA**

Rua Bela Cintra, 178, Cerqueira César – São Paulo/SP - CEP 01415-000  
Zeppelini – Tel: 55 11 2978-6686 – www.zeppelini.com.br  
Rede Filantropia – Tel: 55 11 2626-4019 – www.filantropia.org

---

## CONTENTS

### EDITORIAL

#### 115 Axillary surgery in breast cancer: are we near the end of the road

*Cirurgia axilar no câncer de mama: estamos próximos ao fim da estrada?*

Clevertton César Spautz

### ORIGINAL ARTICLE

#### 118 Predictive values of breast imaging reporting and data system category 3 breast masses submitted to percutaneous biopsy by ultrasonography

*Valores preditivos dos nódulos mamários categoria 3 pelo sistema de laudos e registro de dados de imagem da mama submetidos à biópsia percutânea por ultrassonografia*

Leticia Pereira Gonçalves, Mariana Loureiro Lemos, Maria Julia Gregorio Calas

#### 125 Prevention of breast cancer through primary health care training

*Prevenção do câncer de mama por meio da capacitação na atenção básica*

Carlos Vinicius Pereira Leite, Mariana de Matos Porsani, Marilda Vargas Freitas Plácido, Daniel Rodrigues Nunes, Carla Leticia Carius Ferreira

#### 131 Epidemiological and clinical profile of men with breast cancer in Amazonas, Brazil

*Perfil epidemiológico e clínico de homens com câncer de mama no Amazonas*

Antônio Cosme Carvalho Neto, Gabriel Pacífico Seabra Nunes, Hilka Flávia Barra do Espírito Santo Alves Pereira, Gabriel Pacífico Seabra Nunes

#### 136 Oncoplastic surgery and immediate breast reconstruction in breast cancer patients: satisfaction and quality of life evaluation

*Cirurgia oncoplástica e reconstrução mamária imediata em pacientes com câncer de mama: avaliação da satisfação e qualidade de vida*

Lucimara Priscila Campos Veras Giorgi, Adriana Haack de Arruda Dutra

#### 144 Evaluation of delays in diagnosis and treatment of breast cancer in a reference center: a retrospective analysis

*Avaliação do atraso no diagnóstico e tratamento do câncer de mama em um centro de referência: uma análise retrospectiva*

Artur Lício Rocha Bezerra, Maria Carolina Muniz Bezerra, André Filipe Ferreira Lopes dos Santos, Fernando Moura Lima, Isabel Tenório de Brito Almeida, Larissa Miranda Galvão Ferreira

### IMAGE IN MASTOLOGY

#### 152 Imaging findings of absorbable vicryl mesh implanted after lumpectomy

*Achados de imagem de tela absorvível de Vicryl implantada após cirurgia conservadora*

Almir Galvão Vieira Bitencourt, Marília Mendes de Azevedo, Vinicius Cardona Felipe, Juliana Alves de Souza, Mauricio Doi, Hugo Fontan Kohler

#### 155 18F-FDG PET/CT helps to find occult carcinoma in a patient with multiple breast masses at magnetic resonance imaging

*PET/CT com 18F-FDG ajuda a identificar carcinoma oculto em paciente com múltiplos nódulos mamários na ressonância magnética*

Almir Galvão Vieira Bitencourt, Luciana Graziano, Carla Tajima, Fabiana Baroni Makdissi, Eduardo Nóbrega Pereira Lima

### CASE REPORT

#### 158 Transformation of fibroadenoma to phyllodes tumor and the use of oncoplastic technique for breast conservative treatment

*A transformação do fibroadenoma em tumor filóides e o uso de técnicas oncoplásticas no tratamento cirúrgico conservador de mama*

Julia Dias do Prado, Roberto José da Silva Vieira, Waldyr Gomes da Costa Neto, Linda Lorena Gonzalez de Castro, Bruno Bohrer Flores, Lea Pikelhaizen Velloso

#### 162 Case report: intraductal papilloma of the male breast

*Relato de caso: papiloma intraductal em mama masculina*

Vivian Milani, José Alano Costa Oliveira Júnior, Herbert Franchi Teixeira Andreghetto, Anita Mayara Feitosa Santos, Emília Virginia Lima Curvelo Fontes

#### 165 Anaplastic lymphoma mimicking breast carcinoma

*Linfoma anaplásico mimetizando carcinoma mamário*

Rafael da Silva Sá, Tatiana Veri de Arruda Mattos, Andressa Veri de Arruda Mattos, Hugo Máximo Oliveira Diniz, Maycon Luan Eburnio

### I INSTRUCTIONS TO AUTHORS

# AXILLARY SURGERY IN BREAST CANCER: ARE WE NEAR THE END OF THE ROAD

Cirurgia axilar no câncer de mama: estamos próximos ao fim da estrada?

Cleverton César Spautz<sup>1\*</sup> 

**S**urgical treatment of breast cancer has always addressed the breast and axilla together, and it was restricted until some decades ago to radical mastectomy. The first major change in breast approach occurred in the 1980s when Veronesi and Fischer introduced conservative breast surgery along with radiotherapy while maintaining axillary dissection<sup>1,2</sup>.

The possibility of more conservative surgical treatments culminated in breaking the paradigm that linked success to surgical radicality. With a better understanding of the natural history of the disease, there were changes in treatment that included chemotherapy, radiotherapy and hormone therapy, and even more recent lines such as target therapy and immunotherapy. The use of multiple therapeutic fronts propelled the search for less aggressive surgical treatments.

Despite the evolution of surgical techniques in the approach of the breast, axillary dissection was maintained. However, it is known that the consequences of this procedure, from the functional point of view, are more severe than the mastectomy itself. Lymphedema and monoparesis are frequent complications in this surgery, often progressive and irreversible, leading to substantial limitations in the daily lives of patients.

Because of the concern about reducing axillary dissection morbidity, in the late 1990s, the sentinel lymph node technique emerged, which allows patients with negative lymph nodes to be spared from axillary dissection.<sup>3</sup>

In the following years, the sentinel lymph node technique was established as the most appropriate for patients with a clinically negative axilla, leaving axillary dissection restricted to cases in which there was lymph node involvement. However, despite the continuous increase in early diagnosis linked to extensive screening campaigns, a still significant proportion of women with breast cancer have lymph node involvement at diagnosis. This is due to two factors: delayed diagnosis due to screening failure and aggressive tumor behavior itself.

After more than 10 years of using the sentinel lymph node procedure, a new step has been taken towards lower morbidity. Giuliano et al. led the American College of Surgeons Oncology Group Z0011 (ACOSOG Z0011) study, which demonstrated that even women with low lymph node involvement (1-2 lymph nodes without extracapsular spread) can avoid axillary dissection without increased risk of recurrence.<sup>4</sup> Interestingly, when the axillary dissection group was analyzed, 27.3% of the women had other involved lymph nodes, in addition to the sentinel lymph node(s), without survival impairment, which demonstrates the effectiveness of the adjuvant treatments. These data were corroborated in 2017 in an update of the same study with a 9.3-year follow-up showing no difference between groups in overall survival, disease-free survival, and axillary recurrence.<sup>5</sup>

Also, as an alternative to axillary dissection, AMAROS, a non-inferiority study, compared axillary dissection with axillary radiotherapy and concluded that the latter was not inferior in terms of overall and disease-free survival with lower lymphedema rate in the radiotherapy group.<sup>6</sup>

With the use of neoadjuvant treatments came the new possibility of less aggressive surgical treatments. This was clear from the outset for the breast approach, which made it possible to use conservative surgery in women who had previously undergone mastectomy. However, in patients with positive lymph nodes prior to neoadjuvant therapy, the use of sentinel lymph nodes is still debatable. Important points include lower lymph node identification rate as well as higher false-negative rate.

Questions arose: when is the ideal time to do the sentinel lymph node procedure, before or after neoadjuvants? What is the appropriate method, using one or two tracers? And what is the optimal number of resected sentinel lymph nodes? Further studies have been conducted in an attempt to answer these questions.

<sup>1</sup>Centro de Doenças Mama/Oncoclínica, Hospital Nossa Senhora das Graças – Curitiba (PR), Brazil.

\*Corresponding author: ccspautz@gmail.com

Conflict of interests: nothing to declare.

Received on: 09/07/2019. Accepted on: 09/08/2019



In the Sentinel Neoadjuvant (SENTINA) study, women were divided according to axilla status: positive or negative. Those with a negative axilla underwent sentinel lymph node evaluation before chemotherapy with an identification rate of 99.1%. Those with clinically positive axilla underwent sentinel lymph node biopsy after neoadjuvant therapy with an identification rate of 80.1% and respective false-negative rates of 24.3 and 18.5% when one or two lymph nodes were removed. The change in lymphatic drainage pattern due to chemotherapy response explains this difference in identification rate and the high false-negative rate found.<sup>7</sup>

ACOSOG Z1071 evaluated only women with a biopsy-proven positive axilla who had undergone neoadjuvant chemotherapy. The identification rate was 92.7% and the use of two tracers for sentinel node identification was more effective than one. The false-negative rate was 12.6% with a clear relationship with the number of sentinel lymph nodes found. When three or more sentinel lymph nodes were identified, the false negative was 9.1%.<sup>8,9</sup>

The use of lymph node tracers at the time of biopsy made it possible to improve the reliability of the sentinel lymph node technique. As already mentioned, changes occur in the lymphatic drainage path after neoadjuvant treatment, which makes the identification of the correct lymph node impossible in 23% of cases.<sup>10</sup> The advantage of prior marking of the axilla is the certainty that the involved lymph node is resected. Clips, radioactive iodine ( $I^{125}$ ) seed and charcoal are the most commonly used materials for this purpose.

Marking the axilla with radioactive iodine seeds (MARI) to indicate involved lymph nodes demonstrated a 97% identification rate and a 7% false-negative rate, proving to be a suitable method.<sup>11</sup>

Lymph node clip placement at the time of biopsy, target axillary dissection (TAD) and surgical removal in conjunction with

the conventional sentinel lymph node technique (patent blue and radiolabeled colloid) achieved a false-negative rate of 1.4%, providing the technique with reliability.<sup>10</sup> The need for pre-surgical marking of previously clipped lymph nodes is considered inconvenient.

The charcoal method for lymph node marking has also been shown to be effective, with high identification rates (96.9–100%)<sup>12-15</sup>. It is a simple technique with injection of 0.1 to 0.5 mL of charcoal suspension into the lymph node capsule at the same time as the biopsy. At the time of surgery, it is then located by staining, combining it with the conventional sentinel node technique.

Therefore, in neoadjuvant therapy, sentinel lymph node use is feasible for those patients whose axilla has become clinically negative after systemic therapy. For its reliability, the following guidelines should be observed: use of two tracers, identification of three or more lymph nodes<sup>16</sup> or prior lymph node marking at the time of biopsy (clip, radioactive iodine seed or charcoal) and its resection during the surgery.

As with early stages, there are current studies to prevent axillary dissection in women who continue to have positive lymph nodes after neoadjuvant therapy. These include Alliance A011202, which randomizes women after neoadjuvant chemotherapy with positive sentinel lymph node(s) for axillary dissection (levels I and II) or axillary radiotherapy. It is expected to end in 2024.

We will still see major changes in axillary surgery. There is a constant search for procedures with maximum effectiveness and minimum morbidity. In a few years, axillary dissection will probably not be a part of breast cancer treatment. However, the use of sentinel lymph nodes or even less aggressive and more precise techniques will remain within the scope of breast cancer treatment for some time to come.

## REFERENCES

- Veronesi U, Saccozzi R, Del Vecchio M, Banfi A, Clemente C, De Lena M, et al. Comparing radical mastectomy with quadrantectomy, axillary dissection, and radiotherapy in patients with small cancers of the breast. *N Engl J Med* [Internet]. 1981 [acessado em 31 mar. 2015];305(1):6-11. Disponível em: <http://www.ncbi.nlm.nih.gov/pubmed/7015141>. <https://doi.org/10.1056/NEJM198107023050102>
- Fisher B, Bauer M, Margolese R, Poisson R, Pilch Y, Redmond C, et al. Five-year results of a randomized clinical trial comparing total mastectomy and segmental mastectomy with or without radiation in the treatment of breast cancer. *N Engl J Med* [Internet]. 1985 [acessado em 8 abr. 2015];312(11):665-73. Disponível em: <http://www.ncbi.nlm.nih.gov/pubmed/3883167>. <https://doi.org/10.1056/NEJM198503143121101>
- Giuliano AE, Haigh PI, Brennan MB, Hansen NM, Kelley MC, Ye W, et al. Prospective observational study of sentinel lymphadenectomy without further axillary dissection in patients with sentinel node-negative breast cancer. *J Clin Oncol*. 2000;18(13):2553-9. <https://doi.org/10.1200/JCO.2000.18.13.2553>
- Giuliano AE, Hunt KK, Ballman KV, Beitsch PD, Whitworth PW, Blumencranz PW, et al. Axillary dissection vs no axillary dissection. *JAMA*. 2011;305(6):569-75. <https://doi.org/10.1001/jama.2011.90>

5. Giuliano AE, Ballman KV, McCall L, Beitsch PD, Brennan MB, Kelemen PR, et al. Effect of axillary dissection vs no axillary dissection on 10-year overall survival among women with invasive breast cancer and sentinel node metastasis: The ACOSOG Z0011 (Alliance) randomized clinical trial. *JAMA*. 2017;318(10):918-26. <https://doi.org/10.1001/jama.2017.11470>
6. Donker M, van Tienhoven G, Straver ME, Meijnen P, van de Velde CJH, Mansel RE, et al. Radiotherapy or surgery of the axilla after a positive sentinel node in breast cancer (EORTC 10981-22023 AMAROS): A randomised, multicentre, open-label, phase 3 non-inferiority trial. *Lancet Oncol*. 2014;15(12):1303-10. [http://dx.doi.org/10.1016/S1470-2045\(14\)70460-7](http://dx.doi.org/10.1016/S1470-2045(14)70460-7)
7. Kuehn T, Bauerfeind I, Fehm T, Fleige B, Hausschild M, Helms G, et al. Sentinel-lymph-node biopsy in patients with breast cancer before and after neoadjuvant chemotherapy (SENTINA): A prospective, multicentre cohort study. *Lancet Oncol*. 2013;14(7):609-18. [http://dx.doi.org/10.1016/S1470-2045\(13\)70166-9](http://dx.doi.org/10.1016/S1470-2045(13)70166-9)
8. Boughey JC, Suman VJ, Mittendorf EA, Ahrendt GM, Wilke LG, Taback B, et al. Sentinel lymph node surgery after neoadjuvant chemotherapy in patients with node-positive breast cancer. *JAMA*. 2013;310(14):1455-61. <http://doi.org/10.1001/jama.2013.278932>
9. Boughey JC, Suman VJ, Mittendorf EA, Ahrendt GM, Wilke LG, Taback B, et al. Factors affecting sentinel lymph node identification rate after neoadjuvant chemotherapy for breast cancer patients enrolled in ACOSOG Z1071. *Ann Surg Oncol*. 2013;20:S8-9. Disponível em: <https://www.ncbi.nlm.nih.gov/pmc/articles/PMC4324533/pdf/nihms598113.pdf>
10. Caudle AS, Yang WT, Krishnamurthy S, Mittendorf EA, Black DM, Gilcrease MZ, et al. Improved axillary evaluation following neoadjuvant therapy for patients with node-positive breast cancer using selective evaluation of clipped nodes: implementation of targeted axillary dissection. *J Clin Oncol*. 2016;34(10):1072-8. <http://doi.org/10.1200/JCO.2015.64.0094>
11. Donker M, Straver ME, Wesseling J, Loo CE, Schot M, Drukker CA, et al. Marking: axillary lymph nodes with radioactive iodine seeds for axillary staging after neoadjuvant systemic treatment in breast cancer patients the MARI procedure. *Ann Surg*. 2015;261(2):378-82. <https://doi.org/10.1097/SLA.0000000000000558>
12. Choy N, Lipson J, Porter C, Ozawa M, Kierny A, Pal S, et al. Initial Results with preoperative tattooing of biopsied axillary lymph nodes and correlation to sentinel lymph nodes in breast cancer patients. *Ann Surg Oncol*. 2015;22(2):377-82. <https://doi.org/10.1245/s10434-014-4034-6>
13. Park S, Koo JS, Kim GM, Sohn J, Kim S II, Cho YU, et al. Feasibility of charcoal tattooing of cytology-proven metastatic axillary lymph node at diagnosis and sentinel lymph node biopsy after neoadjuvant chemotherapy in breast cancer patients. *Cancer Res Treat*. 2018;50(3):801-12. <https://doi.org/10.4143/crt.2017.210>
14. Patel R, MacKerricher W, Tsai J, Choy N, Lipson J, Ikeda D, et al. Pretreatment tattoo marking of suspicious axillary lymph nodes: reliability and correlation with sentinel lymph node. *Ann Surg Oncol*. 2019;26(8):2452-8. <https://doi.org/10.1245/s10434-019-07419-3>
15. Spautz CC. Avaliação da taxa de identificação do linfonodo previamente marcado com suspensão de carvão a 4% em pacientes com câncer de mama submetidas à quimioterapia neoadjuvante [dissertação] [Internet]. Curitiba: Universidade Federal do Paraná; 2017 [acessado em 07 de setembro de 2019]. Disponível em: <https://acervodigital.ufpr.br/bitstream/handle/1884/55038/R - D - CLEVERTON CESAR SPAUTZ.pdf?sequence=1&isAllowed=y>
16. Mamtani A, Barrio AV, King TA, Van Zee KJ, Plitas G, Pilewskie M, et al. How often does neoadjuvant chemotherapy avoid axillary dissection in patients with histologically confirmed nodal metastases? Results of a prospective study. *Ann Surg Oncol*. 2016;23(11):3467-74. <https://doi.org/10.1245/s10434-016-5246-8>

# PREDICTIVE VALUES OF BREAST IMAGING REPORTING AND DATA SYSTEM CATEGORY 3 BREAST MASSES SUBMITTED TO PERCUTANEOUS BIOPSY BY ULTRASONOGRAPHY

Valores preditivos dos nódulos mamários categoria 3 pelo sistema de laudos e registro de dados de imagem da mama submetidos à biópsia percutânea por ultrassonografia

Leticia Pereira Gonçalves<sup>1\*</sup> , Mariana Loureiro Lemos<sup>1</sup> , Maria Julia Gregorio Calas<sup>1</sup> 

## ABSTRACT

**Introduction:** Breast Imaging Reporting and Data System (BI-RADS) classification allows standardization of breast masses findings, with a recommendation for individualized management. Because of their high frequency, masses classified as 3, probably benign, arouse interest in improving their characterization and in establishing the most appropriate behavior. **Objective:** Firstly, to demonstrate the positive and negative predictive values of the BI-RADS 3 classification of solid masses submitted to percutaneous biopsy by ultrasonography. Secondly, to suggest a different ultrasound follow-up conduct in these findings. **Methods:** We retrospectively studied 480 BI-RADS 3 masses, submitted to a biopsy under vacuum or core biopsy, with a conclusive histopathological result considered the gold standard. **Results:** From 480 masses in 396 patients, 473 were benign and 7 malignant. The positive predictive value for malignancy of category 3 masses was 1.5% (7/480), and the negative predictive value was 98.5%. **Conclusion:** In view of the low probability of cancer, it is recommended the performance of directed ultrasonography (second look) of masses classified as BI-RADS 3 performed by a specialist in breast radiology before the indication of an invasive procedure, what would substantially reduce the number of unnecessary biopsies, patient's anxiety, as well as costs and possible related complications. This will increase the possibility for the specialist to spend more time on really necessary and targeted examinations, better defining cases of follow-up (annual or biannual) of the indication of investigation in specific cases.

**KEYWORDS:** breast neoplasms; diagnosis; biopsy; ultrasonography.

## RESUMO

**Introdução:** A classificação do Breast Imaging Reporting and Data System (BI-RADS) permite a padronização dos achados das massas mamárias, com recomendação para o manejo individualizado. Por causa de sua alta frequência, massas classificadas como 3, provavelmente benignas, despertam interesse em melhorar sua caracterização e em estabelecer o comportamento mais adequado. **Objetivo:** Primeiramente, demonstrar os valores preditivos positivos e negativos da classificação de massas sólidas BI-RADS 3 submetidas a biópsia percutânea por ultrassonografia. Em segundo lugar, sugerir conduta de acompanhamento por ultrassonografia diferente nesses achados. **Metodologia:** Estudamos, retrospectivamente, 480 massas BI-RADS 3, submetidas a biópsia a vácuo ou core-biopsia, com resultado histopatológico conclusivo considerado padrão-ouro. **Resultados:** De 480 massas em 396 pacientes, 473 eram benignas e 7 malignas. O valor preditivo positivo para malignidade de categoria 3 foi de 1,5% (7/480) e o valor preditivo negativo foi de 98,5%. **Conclusão:** Em vista da baixa probabilidade de câncer, recomenda-se a realização de ultrassonografia direcionada (second look) de massas classificadas como BI-RADS 3 por especialista em radiologia da mama antes da indicação de um procedimento invasivo, o que reduziria substancialmente o número de biópsias desnecessárias, ansiedade do paciente, bem como possíveis complicações. Isso aumentará a possibilidade de o especialista passar mais tempo em exames realmente necessários e direcionados, definindo melhor os casos de acompanhamento (anual ou semestral) da indicação da investigação em casos específicos.

**PALAVRAS-CHAVE:** neoplasias de mama; diagnóstico; biópsia; ultrassonografia.

<sup>1</sup>Clínica de Diagnóstico por Imagem – Rio de Janeiro (RJ), Brazil.

\*Corresponding author: lpgoncalves@hotmail.com

Conflict of interests: nothing to declare.

Received on: 11/16/2018. Accepted on: 12/27/2018



## INTRODUCTION

The American College of Radiology, with other important institutions on United States, created Breast Imaging Reporting and Data System, known as BI-RADS<sup>®</sup>, used to describe the findings of various breast imaging modalities, including mammography, ultrasound and magnetic resonance imaging. It is also used to indicate a conduct for each case, with the aim of homogenizing the terms and reports, and facilitating the communication between the various professionals involved, as well as to better monitor and audit results<sup>1-3</sup>.

Breast ultrasound (US) has become a well-established imaging tool for breast cancer diagnosis. It is mainly due to the recent evolution of the equipment, allowing the identification of a greater number of hidden masses on mammography (27%) — especially in women aged less than 50 years and with dense breasts —, as well as the distinction between benign and malignant masses, increasing the specificity of mammography when used as a complementary exam<sup>4,6</sup>.

However, despite the enhancement of BI-RADS-US in the most recent edition of 2013, and the numerous publications available, category 3 for masses observed by ultrasonography screening remains a major challenge to breast radiologists<sup>1</sup>.

The first purpose of this study is to present the positive predictive value (PPV) and negative predictive value (NPV) of masses classified as category 3 BI-RADS-US, submitted an ultrasound percutaneous biopsy at a private clinic in the city of Rio de Janeiro, Brazil. The second is to recommend a conduct of ultrasonography follow-up of these findings, knowing that the misinterpretation of the obtained image results entails many negative implications, among which unnecessary biopsies, patient's and attending physician's anxiety, and costly excessive complementary examinations, so that the diagnostic investigation can be continued<sup>4</sup>.

## METHODS

A retrospective study was carried out on 396 patients, with 480 masses classified as BI-RADS-US category 3 on screening or diagnostic ultrasound, submitted to a percutaneous biopsy at a clinic dedicated to breast radiology in the city of Rio de Janeiro, Rio de Janeiro, Brazil.

The equipment used to perform the procedures was Logic P6 (GE Medical System Inc.) with a multi-frequency linear probe (7.5–12 MHz). The procedures performed, following the procedure described in the literature, by requested of the attending physician, were core biopsy or vacuum biopsy. The core biopsies were performed with BARD pistol with a range of 2.2 or 1.5 cm, according to the depth and size of the lesion, and with a 14 Gauge needle. Vacuum biopsies were performed with Atec probe (Surtec Atec Sapphire, Hologic Inc.) with a 12 Gauge needle.

The 5 radiologists who classified the masses at the time of procedure and performed the biopsies are experienced physicians (ranging from 10 to 25 years) in breast image and interventional radiology.

The material considered satisfactory and conclusive was evaluated by a pathologist specializing in breast disease, with 20 years of experience in percutaneous procedures.

A solid mass with a circumscribed margin, oval shape, and parallel orientation, with no posterior features or minimal posterior acoustic enhancement on US, was categorized as BI-RADS 3<sup>1</sup>.

These cases come from a private service, and the patients are already referred to the procedures according to their requesting physician, without data on family risk and changes in physical examination. Due the biopsies are guided by ultrasound, there was no comparison with possible mammography findings. There is no information regarding whether these masses were palpable or not.

The Research Ethics Committee approved the project, and informed consent form was applied and signed by all patients, alongside verbal explanation of procedure and possible complications and care instructions after the biopsy.

The retrospective data were obtained from clinical database, through an image capture system in digital file and electronic form (e-form).

For data management, a new database of these patients was created using Microsoft Excel 2000 software, following the data management methodology usually used in research protocols.

The tests used in order to prove the proposed objective were the calculation of the PPV and the NPV of the biopsies of BI-RADS-US 3 masses.

The predictive values evaluate the likelihood of a disease (breast cancer), given the results of a diagnostic test. They are determined not only by the sensitivity and specificity of the test but also by the prevalence of the disease in the specific population. PPV is the proportion of true positives among all individuals with positive test, and NPV is the proportion of true negative among individuals with negative test. Statistical analysis was exploratory, comparative and performed using the Statistical Package for Social Sciences (SPSS), version 20.0 (Chicago, IL, USA). Categorical variables will be presented as absolute frequencies and percentages.

The characteristics evaluated were the specialty of the professional who requested the biopsy, the type of procedure performed (core or vacuum biopsy) and the age of patients. Regarding the lesions, the size of the masses was evaluated, being divided in  $\leq 1$  and  $>1$  cm, and the satisfactory histopathological result was considered gold standard.

The results of the exams and procedures performed were informed to the patients and their respective requesting physicians. These professionals would use the information received and decide upon treatment independently of this study, that is, either continue with adequate treatment in carcinoma cases or keep patient in follow-up in benign cases. The data obtained are confidential, and the photographic records of the images were used in this work. The nominal identification in the photo was erased, so that anonymity was maintained.

## RESULTS

Of the total number of biopsy requests, 320 were performed by breast surgeons, 130 by gynecologists and 30 by doctors with other specialties, among which 17 oncologists, 9 plastic surgeon, 2 geriatricians, 1 dermatologist and 1 proctologist. Regarding the results of malignant masses, all had their biopsy requested by breast surgeons.

Of 480 masses identified in 396 female patients, classified as BI-RADS 3 on breast ultrasound, submitted to percutaneous biopsy, 389 cases were core biopsy and 91 were vacuum biopsy, with 473 benign and 7 malignant results. Among the malignant lesions, 3 underwent vacuum biopsy and 4 core biopsy.

Patients' ages varied between 15 and 89 years, with a mean of 43 years. The mean patient age with malignant lesions was 54.7 years (ranging from 42 to 66 years) and with benign lesions was 49.4 years (ranging from 28 to 62 years).

As for masses size, the largest mean was 5.6 cm in the largest diameter and the smallest 0.5 cm. The lesions were smaller than or equal to 1.0 cm in 250 cases (52%) and larger than 1.0 cm in 230 cases (48%). Malignant lesions averaged 1.45 cm, ranging from 0.88 to 2.62 cm.

Among the benign masses, the most common diagnosis was fibroadenoma; among the malignant, infiltrating ductal carcinoma was the most frequent finding.

The PPV for malignancy of category 3 masses in our study was 1.5% (7/480), and the NPV was 98.5% (473/480).

Table 1 presents the histopathological results of all percutaneous procedures, that were grouped in benign and malignant results. The benign ones were grouped into characteristic findings of proliferative and non-proliferative lesions, for a more objective presentation of the table presented.

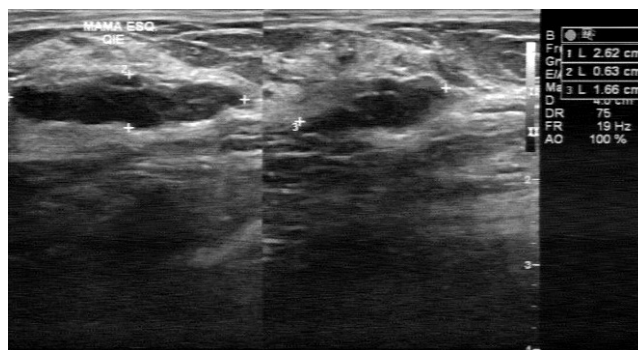
Figures 1 to 4 show cases of this study, classified as BI-RADS 3 before percutaneous biopsy, being: 2 malignant cases (Figures 1 and 2) and 2 benign cases (Figures 3 and 4).

## DISCUSSION

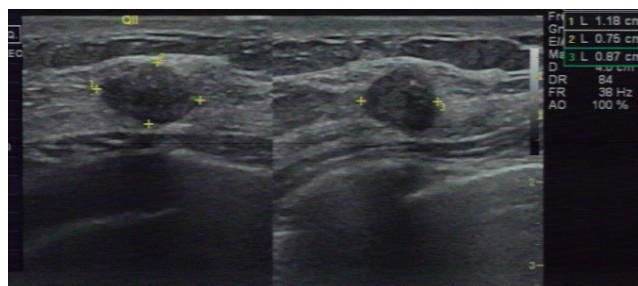
As ultrasound techniques continue to improve with higher-frequency linear transducers that increase spatial resolution, spatial

compounding to improve margin analysis, tissue harmonic imaging that reduces near-field artifacts and intensifies posterior acoustic features, and more robust power Doppler, radiologists have the opportunity to increase their diagnostic confidence. This may lead to further refinements of BI-RADS 3 ultrasound criteria. With the increasing use of breast US screening in women with dense breasts, category 3 lesions are being found more often<sup>6-8</sup>.

BI-RADS 3 in breast imaging is an evolving category. When used properly, the purpose of the short-term follow-up algorithm is to reduce the number of benign biopsies (reduce false-positive exams) while allowing the breast imager to maintain a high sensitivity for the detection of early stage breast cancer<sup>2,9</sup>.



**Figure 1.** Hypoechoic, oval and circumscribed, parallel mass, without posterior features, measuring 2.6 cm. Histopathologic result: Intracystic papillary carcinoma.



**Figure 2.** Hypoechoic, oval and circumscribed, parallel mass, with no posterior features, measuring 1.2 cm. Histopathologic result: invasive tubular carcinoma.

**Table 1.** Histopathological results of 480 masses submitted to percutaneous biopsy, classified as Breast Imaging Reporting and Data System (BI-RADS) 3.

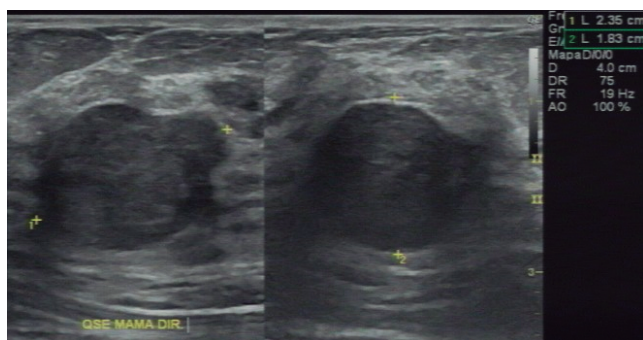
Histopathological	Absolute number	Percentage (%)	Result	C	V
Fibroepithelial neoplasms <sup>a</sup>	347	72.3	Benign	287	60
Non-proliferative injuries <sup>b</sup>	97	20.2	Benign	82	15
Proliferative lesions without atypia <sup>c</sup>	29	6.0	Benign	17	12
Invasive ductal carcinoma (non-special type)	6	1.2	Malignant	3	3
Intracystic papillary carcinoma	1	0.2	Malignant	0	1

<sup>a</sup>Fibroepithelial neoplasms: fibroadenomas; <sup>b</sup>non-proliferative lesions: fibrosis, cyst, pseudoangiomatous change, adipose inclusion, hamartoma, sclero-hyalinosis, lymphocytic infiltration; <sup>c</sup>Proliferative lesions without atypia: alteration of columnar cells without atypia, adenosis, typical ductal hyperplasia, papillary apocrine hyperplasia without atypia, tubule-papillary adenoma, intracystic papilloma; C: core biopsy; V: vacuum biopsy.

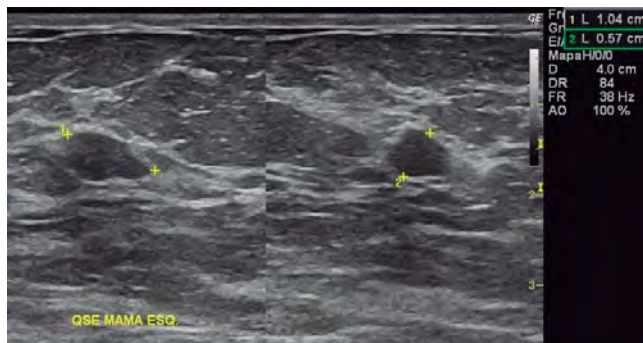BI-RADS 3 creates a wide variety of actions and reactions. It causes patient anxiety, eliminates some unneeded biopsies, and often ignored by patients and referring clinicians. Radiologists who are not sure about what to do with a finding often overuse BI-RADS 3. There are three principles for the use or not of BI-RADS 3:

1. if the lesion is indeterminate or has worrisome features it is not BI-RADS 3;
2. BI-RADS 3 should not be used to delay diagnosis of a malignant appearing finding;
3. BI-RADS 3 should only be used after a full diagnostic workup<sup>2,10-12</sup>.

In Lee's article<sup>2</sup>, the authors cited Chae et al. results, that demonstrated the radiologist's difficulty using BI-RADS 3 for breast ultrasound. In their experience, 14.6% of screening ultrasounds were read as BI-RADS 3. When, however, they reinterpreted the ultrasound exams using ACRIN 6666 criteria, 19.3% of cases had an assessment change. Of 225 patients who had a BI-RADS change, 213 were changed to BI-RADS 2 and 12 were upgraded to BI-RADS-4. Chae et al. also found that the malignancy rate was higher for those with abnormal mammograms compared with those who had normal mammograms (2.2 vs. 0.4%). This suggests an avenue for future research<sup>3,13,14</sup>.



**Figure 3.** Hypoechoic, circumscribed, oval, parallel mass, with minimal posterior acoustic enhancement, measuring 2.4 cm. Histopathological result: fibroadenoma.



**Figure 4.** Hypoechoic, circumscribed, oval, parallel mass, with no posterior features, measuring 1.0 cm. Histopathological result: fibroadenoma.

Interobserver concordance studies in breast ultrasound have Kappa indexes ranging from 0.28 (poor) to 0.83 (substantial) in the literature. This variation is very broad based on a subjective characterization of the images by the radiologist, depending on his experience<sup>7,15</sup>. According to Calas et al.<sup>6</sup>, the main difference features between a benign and a malignant mass are the contour and shape, the contour with the highest sensitivity and the shape the highest specificity.

BI-RADS describes a solid mass with circumscribed margin, oval shape and parallel orientation to the skin, with a probability of malignancy of up to 2%, within the defined range of probable benignity<sup>1,2,4,7-14</sup>.

BI-RADS category 3 is not an indeterminate category and should not be used in case of doubt by the radiologist for benign or suspected lesions (BI-RADS 2 and 4, respectively). It is reserved for specific cases with a chance of malignancy between 0 and 2%<sup>1,2,15-17</sup>.

The incidence of BI-RADS 3 lesions on US has been reported between 15.7 and 32.2%, and the malignancy rate between 0 and 2.6%<sup>16-18</sup>. Due to their high frequency and low probability of cancer, by both ultrasound screening and diagnosis, these nodules arouse in the professionals dedicated to breast radiology a great interest in improving their characterization and in establishing the most appropriate conduct<sup>7-14,18-24</sup>.

In the conduct for category 3, the initial follow-up interval is usually six months, regarding the breast with the probable benign finding, with the recommendation of a second short-term follow-up of six months of the breasts bilaterally (12 months of the initial study), assuming stability in the test<sup>1-3,5</sup>. After that, due to the stability of the 12 months already observed, the recommended follow-up is of 1 year. As in the follow-up of screening mammography, after 2 to 3 years of stability, the final evaluation category should be changed to benign (category BI-RADS 2)<sup>25-30</sup>.

Our study showed a PPV for malignancy of 1.5% and NPV of 98.5%.

Of the requests for biopsies performed, 66.6% were requested by breast surgeons, being the 7 cases of malignancy requested by them. Of all lesions, 56.4% were smaller than or equal to 1.0 cm, and 43.6% were larger than 1.0 cm, which could justify the indication of the biopsy of these masses, because they are larger than 1.0 cm and probably palpable.

In some studies<sup>20,21</sup>, the factors related to biopsies in category 3 masses were patients' preference (patient's wishes), patients' risk factors, suspicious changes in the follow-up interval (increase in volume and/or changes in lesion morphology) and investigator's doubts.

In our study, in addition to limiting the access to information regarding the need for biopsy, we can also cite: the access to the previous examinations (to evaluate image stability), the family or personal history of breast cancer, the lack of correlation with the mammographic findings, and, finally, information about the follow-up of these images with benign histopathology.



Badan<sup>24</sup> and Raza et al.<sup>25</sup> reported a PPV of 0 and of 0.8%, respectively, for malignancy for category 3 masses. They concluded that a conservative management of BI-RADS category 3 lesions on screening breast ultrasound would be adequate in order to avoid unnecessary biopsies.

In the study of Berg et al.<sup>17</sup>, with 127 masses in asymptomatic patients, with heterogeneously dense breasts and at least 1 risk factor for breast cancer, there was no case of malignancy over a 2-year follow-up. With the use of correctly ultrasonography features of each mass, these authors recommended 1-year follow-up for circumscribed and benign masses by US.

Barr et al.<sup>20</sup> presented results and similar follow-up proposals. They reported a 0.9% cancer rate in category 3 lesions in women at increased risk of breast cancer. Only one case presented suspicious modifications at the 6-month follow-up and another at the 1-year follow-up, both infiltrating ductal carcinomas, with negative axillary lymph nodes. Thus, it is recommended an annual follow-up of the BI-RADS lesions 3.

Some studies have related the findings as the findings are palpable or not. Park et al.<sup>22</sup> found a PPV of 0.6% (1 case of infiltrating ductal carcinoma grade 2 and 1 case of mucinous carcinoma, axillary negative lymph nodes) and 99.4% NPV, with no difference between palpable and impalpable masses. In the study by Barr et al.<sup>20</sup>, a rate of 19.5% of category 3 lesions was observed on screening ultrasonography in women at increased risk of breast cancer and with dense breasts, with a malignancy rate of 0.8%, all impalpable lesions.

Graf et al.<sup>16</sup>, with 448 masses, showed no malignant lesions, either on screening exams or at follow-up over a period of two years; the palpable lesions with benign morphology on the image might be similarly accompanied as non-palpable lesions.

Kapsimalakou et al.<sup>12</sup> concluded that it is critical that the attending physician be able to rely on the radiologist's ability to distinguish probably benign lesions from lesions that should be readily biopsied. Image follow-up would identify the progression of malignant lesions, but most cancers will continue to be diagnosed early, resulting in a favorable prognosis, a finding corroborated by Sickles<sup>13</sup>. They also include positive factors such as increased PPV of biopsies, reduction of morbidity associated with percutaneous or surgical biopsy, and reduction of costs.

Alimoglu et al.<sup>4</sup> found a 5.3% frequency of category 3 non-palpable masses in non-risk patients. Seventy percent of them remained stable for two years. The malignancy rate was 0.3%, and 85% of the changes occurred in the first two years of follow-up, namely, progression in size greater than 20% and morphological change. These authors also showed a 60% reduction in costs with follow-up compared to biopsy, with the advantage of lower morbidity, lower risk and fewer complications.

Stavros et al.<sup>19</sup> concluded that, although invasive procedures are well tolerated, they present some hindrances, such as

discomfort and patient anxiety, increased costs, which include recovery time and total health costs.

Another interesting point is that even BI-RADS 3 lesions that had the histopathological diagnosis established should continue the follow-up for two or three years for complete safety in stability, and, therefore, benignity. This fact makes follow-up even more cost-effective and not immediate biopsy<sup>1</sup>.

Briefly, there is a high incidence of BI-RADS 3 masses on US alongside a low incidence of cancer, inducing thereby to unnecessary control tests, as well as invasive procedures. However, several factors should be considered when determining the conduct of patients with category 3 BI-RADS masses. For example, cost evaluation (cost of a possible biopsy, percutaneous or surgical, emotional exhaustion, operational costs, unnecessary repetition of exams), especially in countries like Brazil, where the majority of the population uses public health services that are often precarious<sup>14</sup>.

Another still controversial point of interest would be the best interval for follow-up examinations of such masses and how this examination would be performed, *i.e.*, in a targeted fashion, unilateral, or bilateral and complete.

Prior to the biopsy request of a mass previously classified like BI-RADS 3, and in some cases BI-RADS 4A, the ultrasound performed in a targeted fashion to the image in question by an experienced professional in breast radiology, compared with previous exams and other imaging tests, could reduce the indication for biopsy and increase their PPV. This would result in reduction in both morbidity and patient's cost.

Short-term follow-up could hence be performed with greater safety, what would bring greater comfort for the attending physician to give up on the histopathological diagnosis, since ultrasonographic criteria for nodule classification are to be adequately applied by experienced breast radiologists. The images could be reclassified as BI-RADS 2 and be kept under annual control, or classification BI-RADS 3 could be maintained with a new directed study in 6 months or yet an indication for biopsy in the event of reclassifying the image as BI-RADS 4.

## CONCLUSION

Ultrasound is readily available, uses no ionizing radiation, and is well tolerated by patients. In women with dense breasts tissue, supplemental breast ultrasound imaging can increase cancer detection rates by 1.8 to 4.6 per 1,000<sup>20</sup>. However, in finding more cancers, supplemental ultrasound will also discover more benign masses that are not characteristically benign in appearance, increasing the number of biopsies and false-positive rates. Breast masses BI-RADS 3, probably benign, is a challenging assessment category.

From NPV results of 98.5% in our study, we recommend that a dedicated breast radiologist perform a US-directed

BI-RADS category 3 mass prior to the indication for a possible intervention. This would reduce substantially the number of unnecessary biopsies, as well as the costs and complications related to it. Moreover, this would give more confidence

to the assistant physician to characterize correctly lesions and to suggest an annual follow-up. However, a large series prospective study is needed before further studies validate this recommendation.

## REFERENCES






- Mendelson EB, Böhm-Vélez M, Berg WA, Whitman GJ, Feldman MI, Madjar H, et al. ACR BI-RADS ultrasound. In: D'Orsi CJ, Sickles EA, Mendelson EB, Morris EA, editors. ACR BI-RADS Atlas: Breast Imaging Reporting and Data System. Reston: American College of Radiology; 2013.
- Lee KA, Talati N, Oudsema R, Steinberger S, Margolies LR. BI-RADS 3: Current and Future Use of Probably Benign. *Curr Radiol Rep.* 2018;6(2):5. <https://doi.org/10.1007/s40134-018-0266-8>
- Jang JY, Kim SM, Kim JH, Jang MJ, Yun BL, Lee JY, et al. Clinical significance of interval changes in breast lesions initially categorized as probably benign on breast ultrasound. *Medicine.* 2017;96(12):e6415. <https://doi.org/10.1097/MD.00000000000006415>
- Alimoglu E, Bayraktar SD, Bozkurt S, Çeken K, Kabaalioglu A, Apaydin A, et al. Follow-up versus tissue diagnosis in BI-RADS category 3 solid breast lesions at US: a cost-consequence analysis. *Diagn Interv Radiol.* 2012;18(1):3-10. <https://doi.org/10.4261/1305-3825.DIR.4462-11.1>
- Kim SY, Han BK, Kim EK, Choi WJ, Choi Y, Kim HH, et al. Breast Cancer Detected at Screening US: Survival Rates and Clinical-Pathologic and Imaging factors Associated with Recurrence. *Radiology.* 2017;284(2):354-64. <https://doi.org/10.1148/radiol.2017162348>
- Calas MJG, Koch HA, Dutra MVP. Ultra-sonografia mamária: avaliação dos critérios ecográficos na diferenciação das lesões mamárias. *Radiol Bras.* 2007;40(1):1-7. <http://dx.doi.org/10.1590/S0100-39842007000100003>
- Calas MJG, Almeida RMVR, Gutflen B, Pereira WCA. Interobserver concordance in the BI-RADS classification of breast ultrasound exams. *Clinics.* 2012;67(2):185-9. [https://dx.doi.org/10.6061/2Fclinics%2F2012\(02\)16](https://dx.doi.org/10.6061/2Fclinics%2F2012(02)16)
- Lee S, Jung Y, Bae Y. Synchronous BI-RADS Category 3 Lesions on Preoperative Ultrasonography in Patients with Breast Cancer: Is Short-Term Follow-Up Appropriate? *J Breast Cancer.* 2015;18(2):181-6. <https://doi.org/10.4048/jbc.2015.18.2.181>
- Borders MH, Cheng L, Fitzpatrick KA, Krupinski EA. Patient Compliance in the Setting of BI-RADS Category 3: What Factors Impact Compliance With Short-Term Follow-Up Recommendations? *Breast J.* 2016;23(1):77-82. <https://doi.org/10.1111/tbj.12687>
- Gruber R, Jaromi S, Rudas M, Pfari G, Riedl CC, Flöry D, et al. Histologic work-up of non-palpable breast lesions classified as probably benign at initial mammography and/or ultrasound (BI-RADS category 3). *Eur J Radiol.* 2013;82(3):398-403. <https://doi.org/10.1016/j.ejrad.2012.02.004>
- Moon HJ, Kim MJ, Yoon JH, Kim EK. Follow-up interval for probably benign breast lesion on screening ultrasound in women at average risk for breast cancer with dense breasts. *Acta Radiol.* 2018;59(9):1045-50. <https://doi.org/10.1177/0284185117745906>
- Kapsimalakou S, Waldmann A, Katalinic A, Grande-Nagel I, Fischer D, Barkhausen J, et al. Follow-up of probably benign lesions in non-screening breast diagnostics. *Arch Gynecol Obstet.* 2014;290(3):543-51. <https://doi.org/10.1007/s00404-014-3233-5>
- Sickles EA. Probably benign breast lesions: when should follow-up be recommended and what is the optimal follow-up protocol? *Radiology.* 1999;213(1):11-4. <https://doi.org/10.1148/radiology.213.1.r99oc4611>
- Chala L, Endo E, Kim S, Castro F, Moraes P, Cerri G, et al. Gray-scale sonography of solid breast masses: diagnosis of probably benign masses and reduction of the number of biopsies. *J Clin Ultrasound.* 2007;35(1):9-19. <https://doi.org/10.1002/jcu.20298>
- Elverici E, Zengin B, Barca AN, Yilmaz PD, Alimli A, Araz L. Interobserver and intraobserver agreement of sonographic BIRADS lexicon in the assessment of breast masses. *Iran J Radiol.* 2013;10(3):122-7. <https://dx.doi.org/10.5812/2Firanjrad.10708>
- Graf O, Helbich TH, Hopf G, Graf C, Sickles EA. Probably benign breast masses at US: is follow-up an acceptable alternative to biopsy? *Radiology.* 2007;244(1):87-93. <https://doi.org/10.1148/radiol.2441060258>
- Berg WA, Zhang Z, Cormack JB, Mendelson EB. Multiple Bilateral Circumscribed Masses at Screening Breast US: Consider Annual Follow-up. *Radiology.* 2013;268(3):673-83. <https://doi.org/10.1148/radiol.13122251>
- Kim K, Song MK, Kim E-K, Yoon JH. Clinical application of S-Detect to breast masses on ultrasonography: a study evaluating the diagnostic performance and agreement with a dedicated breast radiologist. *Ultrasonography.* 2017;36(1):3-9. <https://doi.org/10.14366/usg.16012>
- Stavros AT, Thickman D, Rapp CL, Dennis MA, Parker SH, Sisney GA. Solid breast nodules: use of sonography to distinguish between benign and malignant lesions. *Radiology.* 1995;196(1):123-34. <https://doi.org/10.1148/radiology.196.1.7784555>
- Barr RG, Zhang Z, Cormack JB, Mendelson EB, Berg WA. Probably benign lesions at screening breast US in a population with elevated risk: prevalence and rate of malignancy in the ACRIN 6666 trial. *Radiology.* 2013;269(3):701-12. <https://doi.org/10.1148/radiol.13122829>

21. Nam SY, Ko EY, Han B-K, Shin JH, Ko ES, Hahn SY. Breast Imaging Reporting and Data System Category 3 Lesions Detected on Whole-Breast Screening Ultrasound. *J Breast Cancer*. 2016;19(3):301-7. <https://dx.doi.org/10.4048%2Fjbc.2016.19.3.301>
22. Park YM, Kim EK, Lee JH, Ryu JH, Han SS, Choi SJ, et al. Palpable breast masses with probably benign morphology at sonography: can biopsy be deferred? *Acta Radiol*. 2008;49(10):1104-11. <https://doi.org/10.1080/02841850802438504>
23. Ha SM, Chae EY, Cha JH, Shin HJ, Choi WJ, Kim HH. Growing BI-RADS category 3 lesions on follow-up breast ultrasound: malignancy rates and worrisome features. *Br J Radiol*. 2018;91(1087):20170787. <https://doi.org/10.1259/bjr.20170787>
24. Badan GM, Roveda Júnior D, Ferreira CAP, Ferreira FAT, Fleury EFC, Campos MSCA, et al. Valores preditivos positivos das categorias 3, 4 e 5 do Breast Imaging Reporting and Data System (BI-RADS®) em lesões mamárias submetidas a biópsia percutânea. *Radiol Bras*. 2013;46(4):209-13. <http://dx.doi.org/10.1590/S0100-39842013000400006>
25. Raza S, Chikarmane SA, Neilsen SS, Zorn LM, Birdwell RL. BI-RADS 3, 4, and 5 lesions: value of US in management: follow-up and outcome. *Radiology*. 2008;248(3):773-81. <https://doi.org/10.1148/radiol.2483071786>
26. Abdullah N, Mesurolle B, El-Khoury M, Kao E. Breast Imaging Reporting and Data System Lexicon for US: Interobserver Agreement for Assessment of Breast Masses. *Radiology*. 2009;252(3):665-672. <https://doi.org/10.1148/radiol.2523080670>
27. Shin JH, Han BK, Ko EY, Choe YH, Nam SJ. Probably benign breast masses diagnosed by sonography: is there a difference in the cancer rate according to palpability? *AJR Am J Roentgenol*. 2009;192(4):W187-91. <https://doi.org/10.2214/AJR.08.1404>
28. Calas MJG, Almeida RMVR, B. Gutfilem B, Pereira WCA. Intraobserver interpretation of breast ultrasonography following the BI-RADS classification. *Eur J Radiol*. 2010;74(3):525-8. <https://doi.org/10.1016/j.ejrad.2009.04.015>
29. Kim SJ, Chang JM, Cho N, Chung SY, Han W, Moon WK. Outcome of breast lesions detected at screening ultrasonography. *Eur J Radiol*. 2012;81(11):3229-33. <https://doi.org/10.1016/j.ejrad.2012.04.019>
30. Ackermann S, Schoenenberger C-A, Zanetti-Dällenbach R. Clinical Data as an Adjunct to Ultrasound Reduces the False-Negative Malignancy Rate in BI-RADS 3 Breast Lesions. *Ultrasound International Open*. 2016;2(3):E83-9. <https://dx.doi.org/10.1055%2Fs-0042-110657>



# PREVENTION OF BREAST CANCER THROUGH PRIMARY HEALTH CARE TRAINING

Prevenção do câncer de mama por meio da capacitação na atenção básica

Carlos Vinicius Pereira Leite<sup>1\*</sup> , Mariana de Matos Porsani<sup>1</sup> ,  
Marilda Vargas Freitas Plácido<sup>1</sup> , Daniel Rodrigues Nunes<sup>1</sup> , Carla Leticia Carius Ferreira<sup>1</sup> 

## ABSTRACT

**Introduction:** The main barrier to the management of breast cancer cases in Brazil is mainly due to the long periods of time between the diagnosis of the patient and the beginning of treatment. **Objective:** To improve access to information, treatment and screening of cancer cases through the training of primary health care professionals. **Methods:** Two “booklets” containing information on breast cancer were created: one for the Community Health Agents (CHAs) and the other for the Primary Health Care Nurses and Doctors (PHCND). Two theoretical and practical training modules were also created: one for the CHAs and another for the PHCNDs. The theoretical module consisted of lectures about breast cancer, and in the practical module, doctors and nurses were inserted in the mastology outpatient service of the Alcides Carneiro Hospital. **Results:** Clinical procedures in 2016 (before training) and 2017 (after training) showed a 31% increase in mastologist consultations, 41% in the number of patients undergoing surgeries and 42% in breast surgeries. From 2016 to 2017 there was a 16.5% reduction in the incidence of breast cancer and the number of deaths remained stable. **Conclusions:** Primary health care training increased and qualified the early detection of breast cancer in the city of Petrópolis-RJ, optimized the population’s access to the specialized service and improved the quality of life of women with breast cancer. Primary health care training was effective, low cost and could be replicated in other Brazilian municipalities.

**KEYWORDS:** breast cancer; training; primary health care.

## RESUMO

**Introdução:** A principal barreira na condução do câncer mama no Brasil ocorre principalmente por conta do elevado tempo entre o diagnóstico e o tratamento efetivo da paciente. **Objetivo:** Melhorar o acesso à informação, ao tratamento e ao rastreamento dos casos de câncer por meio da capacitação dos profissionais da atenção básica. **Métodos:** Duas cartilhas contendo informações sobre o câncer de mama foram elaboradas: uma para os agentes comunitários de saúde (ACS) e a outra para enfermeiros e médicos da atenção básica (EMAB). Dois módulos de treinamentos teóricos e práticos também foram criados: um para os ACS e outro para EMAB. O módulo teórico consistiu de palestras sobre câncer de mama, e no módulo prático, médicos e enfermeiros foram inseridos nos ambulatórios de mastologia do Hospital Alcides Carneiro. **Resultados:** Os procedimentos clínicos em 2017 (após as capacitações) mostraram um aumento de 31% nas consultas com um mastologista, 41% no número de pacientes operados e 42% nas cirurgias de mamas, em comparação com 2016 (antes das capacitações). De 2016 para 2017 houve uma redução de 16,5% dos casos de câncer de mama e o número de óbitos ficou estável. **Conclusões:** A capacitação da atenção básica ampliou e qualificou a detecção precoce do câncer de mama no município de Petrópolis, Rio de Janeiro, agilizou o acesso da população ao serviço especializado e melhorou a qualidade de vida da mulher com câncer de mama. A capacitação na atenção básica foi efetiva, de baixo custo e poderá ser replicada em outros municípios brasileiros.

**PALAVRAS-CHAVE:** câncer de mama; capacitação; atenção básica.

<sup>1</sup>Faculdade de Medicina de Petrópolis – Petrópolis (RJ), Brazil.

\*Corresponding author: carvin.leite@gmail.com

Conflict of interests: nothing to declare.

Received: 12/02/2018. Accepted: 12/27/2018

## INTRODUCTION

Breast cancer is the most common type of cancer among women in the world; and is the leading cause of death among women in Brazil<sup>1</sup>. This is due to the fact that a large number of cases of the disease are diagnosed in advanced stages, where the possibility of disease control is lower.

Cancer is relatively rare before the age of 35, however its occurrence is increasing progressively, especially after 50 years of age. As a result of population growth and aging, direct costs with diagnosis, medication and hospitalization, as well as indirect costs with loss of productivity due to early mortality and costs will continue to increase, becoming a global concern.

The Brazilian government and the agencies linked to the Ministry of Health are concerned about the growing increase of this malignant cancer. In the biennium 2018-2019, 59,700 new cases of breast cancer are estimated<sup>1</sup>. In order to educate and raise awareness among the female population every year during October, known as "Pink October", breast cancer prevention campaigns are publicized on television and in print media to alert women to the seriousness of this disease. One of the main recommended actions is primary prevention, firstly focusing on the importance of healthy habits, such as avoiding smoking, alcohol and fatty foods, and encourage fruit, vegetable and cereal intake, in addition to maintaining an ideal weight. Another important measure is related to secondary prevention, such as self-examination, clinical examination, mammography screening, and access to treatment when diagnosed with breast cancer. A well-informed population is an effective tool in the prevention of cancer and the early detection of the disease.

It is worth mentioning that the main aspects that prevent breast cancer related to changes in healthy habits, include: increased intake of fruits and vegetables, reduced consumption of red meats, processed foods and alcoholic beverages, as well as smoking, obesity and sedentary lifestyle<sup>2-5</sup>.

The main strategy for the early detection of breast cancer is through mammography screening. According to the Brazilian Society of Mastology (SBM), mammography is recommended from the age of 40, however, the Ministry of Health recommends this examination between 50 and 69 years of age, as mammography is an important intervention in primary health care, together with the identification of signs and symptoms by health professionals<sup>6</sup>. It is also emphasized that mammography does not prevent breast cancer, but rather helps with its early detection. According to data from the Hospital Cancer Registry of the Alcides Carneiro Teaching Hospital (HAC), it is verified that 49.8% of the patients diagnosed with breast cancer in the city of Petrópolis and treated in HAC from January 2011 to December 2016 are in the 50 to 69 age group, but 29.7%, who are between 40 and 49 years of age and between 70 and 74 years old, would not be included in the screening, without adding the 12.4% who are 75 years old and older<sup>7</sup>. Another important point to highlight is that the average

size of tumors in HAC during this period was 2 to 3 cm in diameter, and most were detected during self-examination or clinical examination. It is probable that with organized and timely screening, that these cancers could have been detected earlier, which could have contributed to a reduction in breast cancer and, consequently, to the number of deaths.

Thus, women start to become increasingly concerned after 40 years of age. Women considered to have low-incomes seek primary health care through the Unified Health System (SUS), while those with higher incomes seek private care. In SUS, patients have difficulties in receiving a breast cancer diagnosis as well as treatment. It is common for cancer patients to leave treatment because of the long waiting time to access the mastology service. Therefore, the main motivation for this research is to reduce the time between the diagnosis of cancer patients and the beginning of their treatment.

In order to improve the patient's access to the first consultation and shorten the interval before treatment, an intervention in primary health care was proposed in this study, as it is the main gateway for users and is responsible for the referral of those who require health units with more technological devices<sup>8,9</sup>.

Thus, the main objective of this research was to improve access to information and optimize the screening of cancer cases through the training of primary health care professionals to ensure that treatment is performed, guiding the community through face-to-face meetings so that their doubts were clarified and the information was absorbed in order to promote the patient's well-being and dignified health.

To achieve these objectives, the work with primary health care consisted of a set of integrated actions involving family health professionals, doctors, nurses and community health agents (CHA), aimed at increasing access to early breast cancer diagnosis, to train professionals and CHAs, in order to improve the treatment of cancer patients and to reduce the mortality from this disease.

The studies were carried out in the city of Petrópolis, Rio de Janeiro, and were supported by the Petrópolis Medical School (FMP), the HAC, the Petrópolis municipal government and the Roche chemical and pharmaceutical company S.A (ROCHE), which funded the research, aiming to accelerate the access of patients to the diagnosis of breast cancer and its treatment.

## METHODS

The medicine and nursing undergraduate students at the Faculdade de Medicina de Petrópolis (FMP) and Arthur Sá Earp Neto College (FASE), together with family health professionals and the CHAs participated in breast health research through social actions such as lectures and meetings, aiming to promote community integration and raise awareness about the social problem that breast cancer represents.

Firstly, the health professionals were trained and the students were informed about breast cancer, its importance as a public health problem, its epidemiology, diagnosis, treatment, implication in the patient's quality of life and the importance of early diagnosis.

Next, the integrative activities were developed by four academic areas: oncology, radiology, women's health and FMP family health, which planned actions in the communities aiming at the inclusion of breast health education. The results of the work provided the preparation of two booklets containing guidelines on breast care and health for primary health care professionals. One booklet was addressed to CHAs (Figure 1A) and the other to nurses and primary care physicians (Figure 1B).

The booklets present key information on breast cancer and emphasize cancer as a public health problem. They aimed to serve as a quick, practical and easily accessible guide for professionals, aiming at prevention, screening, symptom recognition, patient referral to specialized services and treatment follow-up. The booklets were distributed and used in training and in the health unit as reference sources<sup>10</sup>.

A timetable for training meetings was also created, in which the primary health care professionals were divided into groups so that they could participate more actively in the training, which lasted from May to September 2017. Two training modules were developed: one for the CHAs and another for primary health care nurses and doctors whose activities are described below.

### Training of community health agents

A total of about 350 CHAs from the Petrópolis municipality was divided into groups of 70 participants who were to be trained through scheduled meetings held in the auditorium of the FMP / FASE cultural center.

The programmed activities consisted of lectures on breast cancer, colorectal cancer and lymphomas. The main topics

covered were: importance of early diagnosis of breast cancer, risk factors, modification of lifestyle habits as protective factors, the preconception regarding the tests performed for the detection of tumors, their importance in the care of cancer patients and the identification of community members with a problem and who should be taken to the health care network.

As part of breast cancer-related activities, FMP / FASE students constructed theatrical sketches. The sketches addressed different themes, such as patients' right to privacy with respect to professional anonymity, the importance of seeing a health professional, self-examination, mammography and physical examination of the breasts. This strategy was recognized in 2017 as an innovative practice by the FMP / FASE, as it is an interesting way to break the user's bias in letting the doctor do the clinical breast examination and by showing the importance of the attitude of the CHA towards the stigma related to breast cancer in the community.


### Training of nurses and primary care physicians

Approximately 130 professional nurses and doctors from the city of Petrópolis received theoretical and practical primary health care training during their available hours. The professionals were initially organized into two groups of 65 participants, aiming to make this training more productive and participative. The training of nurses and primary health care physicians also included lectures on breast cancer, colorectal cancer and lymphomas. The main topics covered were: epidemiological overview of breast cancer, colorectal cancer and lymphoma, the main signs and symptoms, the importance of early diagnosis, diagnostic methods, screening and treatment of cancer.

The theoretical activities covered the main signs and symptoms of breast cancer, risk and protective factors, clinical examination of the breasts, detection strategies, mammography and breast ultrasonography, BIRADS system, treatment and follow-up of the patient, conditions for referral to mastology, referral and counter-referral.

In the practical training activities on breast cancer, the group of nurses and doctors was subdivided into 5 subgroups of 26 participants. The primary health care professionals were put in the outpatient clinics of the HAC in order to receive a practical experience on the subject. The breast cancer patient was attended by a maximum of two professionals per treatment room, in order to improve the performance of the practical experience and to help the patient feel comfortable.

It is worth noting that in order for the practical training to become didactic, patients with benign and malignant palpable nodules were selected, in order to improve the practice of the clinical examination of the breast and the differences between the malignant and benign tumors, the correlation with the findings of the physical examination with the phases of the menstrual cycle, clinical / radiological correlation and the BIRADS system.



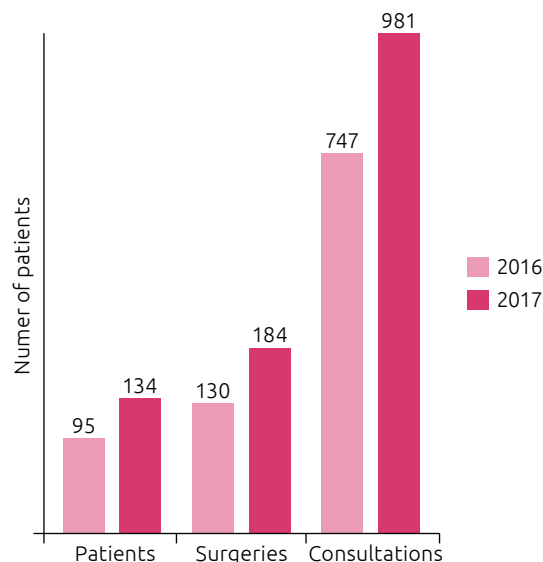
**Figure 1.** (A) Booklet for community health agents; (B) booklet for professional nurses and primary care physicians.

During the care of patients, prevention activities through the control of modifiable risk factors such as diet, physical activity and healthy lifestyle habits were reinforced as strategies for primary prevention of breast cancer. In addition, we have shown that adequate patient referral is critical to improving access to secondary care.

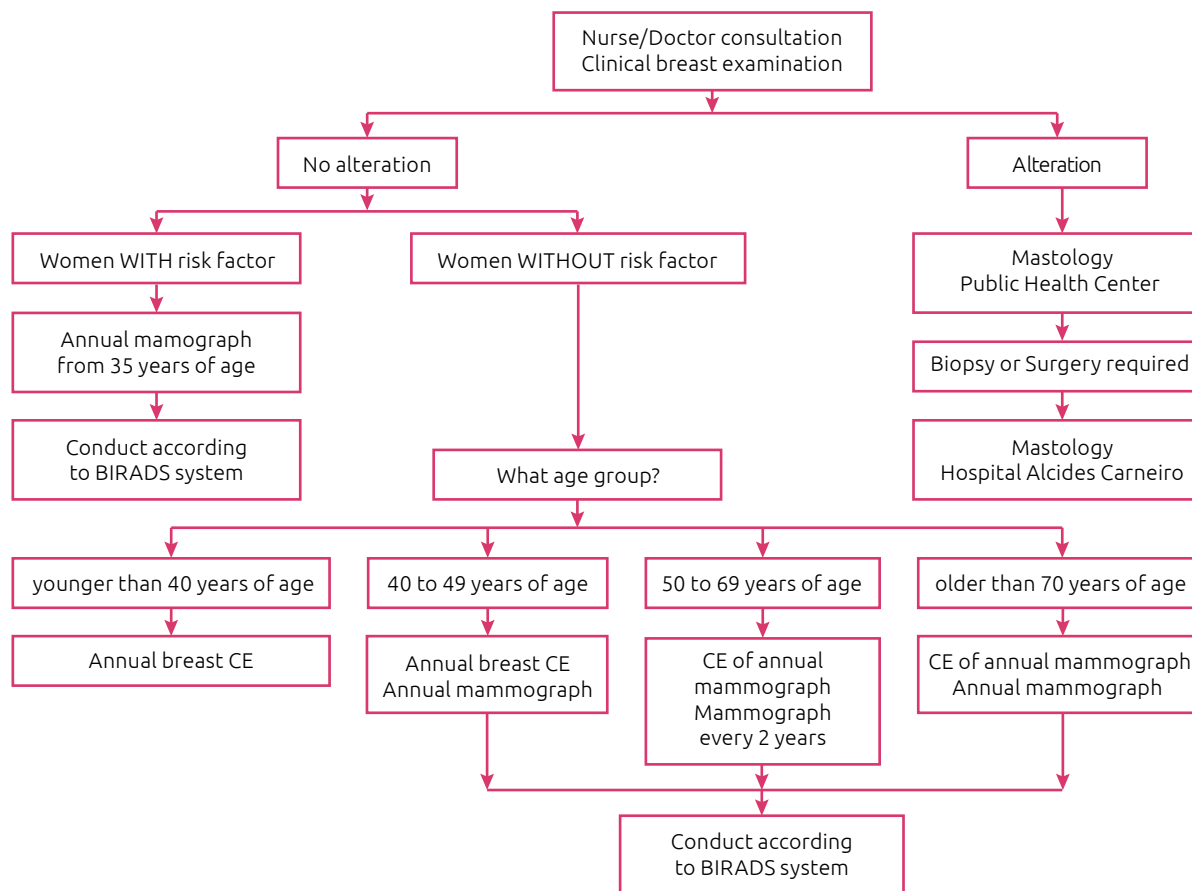
## RESULTS

After the training period of the CHAs, nurses and physicians, a comparative study of clinical procedures was performed in 2016 (before training) and 2017 (after training) on patients who had operations, surgeries and mastology consultations (Figure 2).

In addition, comparative studies of mammography examinations performed in the period from 2012 to 2017 for women residing in Petrópolis were performed. Table 1 shows the information of the patients related to the mammograph screening for the 50 to 69 age group, incidence of breast cancer and the number of deaths caused by breast cancer in the studied period.



**Figure 2.** Comparative study of clinical procedures performed in 2016 and 2017. 41% increase in patients undergoing surgeries, 42% in performed surgeries and 31% in mastology consultations.



CE: clinical examination.

**Figure 3.** Breast examination flowchart for primary health care in the city of Petrópolis, Rio de Janeiro.



As a consequence of this research, the Department of Health of the city of Petrópolis adopted a new flowchart focused on breast changes for primary health care (Figure 3). The flowchart prioritizes the care of patients who had already undergone imaging tests and who were classified as BIRADS category 4 or 5 (Figure 4).

## DISCUSSION

The breast health booklets (Figure 1A and 1B), which served as practical guides for nurses, physicians and CHAs, and the creation of the flow of patients by the Department of Health of the city of Petrópolis were essential procedures for the regulatory physician in the National System Regulation (SISREG) to make appropriate referrals and prioritize services to users.

The results showed a 31% increase in patients undergoing operations, 41% in surgeries and 42% in mastology consultation (Figure 2). Studies have confirmed that women have a greater awareness about breast cancer, with secondary prevention as a great option in the intervention process.

Table 1 shows that mammographs performed for the 50-69 age group indicate an increase in the period from 2012 to 2017. Regarding the incidence of breast cancer, there is a growth between 2013 and 2016, and a reduction of 16.5% from 2016 to 2017. It is also noted that deaths caused by breast cancer increased between 2014 and 2016, and that the number of deaths remained stable from 2016 to 2017. These results are significant, indicating that the reduction in the incidence and stability of deaths due to breast cancer is clear evidence of the success resulting from

the training in primary health care, which motivates the continuity of the study.

The new flowchart (Figure 3) adopted by the Health Department of Petrópolis gave fast access to patients with cancer classified as BIRADS category 4 or 5 (Figure 4) to the HAC mastology outpatient clinic. This procedure is focused on the histopathological investigation, improvement in access to effective treatment and, consequently, improvement in the quality of life of the patient.

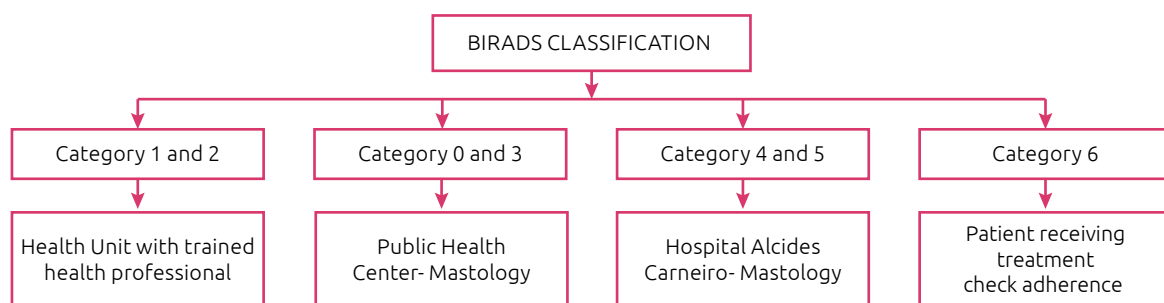
## CONCLUSIONS

This research expanded and qualified the early detection of breast cancer in the city of Petrópolis, through primary health care training, improving access to specialized services; and contributed to a reduction in mortality of patients with this disease.

The breast health booklets served as practical guides for nurses, physicians and CHAs, and were fundamental for the appropriate referral and prioritization of patient care.

In the period from 2016 to 2017, there was a 41% increase in patients who had had surgery, 42% in surgeries and 31% in mastology consultations, demonstrating a greater awareness among women regarding breast cancer. Consequently, there was a 16.5% reduction of breast cancer, and the number of deaths remained stable during this period.

This research allowed the coordination of health care of the Petrópolis Municipal Health Secretary to adopt a new flowchart for patients with breast disease, with a hierarchal flow of care. This fact allowed primary health care patients with imaging tests



**Figure 4.** Flowchart after screening mammography results in the city of Petrópolis, Rio de Janeiro.

**Table 1.** Comparative studies of mammography exams performed in the period from 2012 to 2017 for women residing in Petrópolis<sup>11</sup>.

Description: mammographs performed	2012	2013	2014	2015	2016	2017
Screening in the age range of 50-69 years	4.046	3.258	3.306	4.420	5.545	5.551
Incidence of breast cancer	134	103	133	149	164	137
Deaths from breast cancer	43	48	43	49	51	51

Source: based on SISMAAMA / HST / SMH / CTO / SISCAN data, subject to revision.

classified as BIRADS category 4 or 5 to be referred directly to the CHA, and prepared for treatment.

Together with primary health care, the use of the booklets and the new care flow chart adopted by the city of Petrópolis, Rio de Janeiro, the time between the first consultation, the diagnosis and the beginning of breast cancer treatment was reduced, reducing mortality and improving the quality of life of women with breast cancer. The studies showed that this primary health

care action was effective and low cost and can be replicated in other Brazilian municipalities.

## ACKNOWLEDGMENTS

To the Petrópolis Medical School, the Alcides Carneiro Teaching Hospital, the Petrópolis prefecture, ROCHE, the volunteers and the undergraduate students.

## REFERENCES

1. Instituto Nacional de Câncer José Alencar Gomes da Silva. Estimativa 2018 - Incidência de Câncer no Brasil. Brasil: Ministério da Saúde / Rio de Janeiro: INCA; 2017.
2. Fedirko V, Tramacere I, Bagnardi V, Rota M, Scotti L, Islami F, et al. Alcohol drinking and colorectal cancer risk: an overall and dose-response meta-analysis of published studies. *Ann Oncol.* 2011;22(9):1958-72. <https://doi.org/10.1093/annonc/mdq653>
3. World Cancer Research Foundation. Pancreatic Cancer 2012 report: food, nutrition, physical activity, and the prevention of colorectal cancer. Washington, D.C.: American Institute for Cancer Research; 2012.
4. Walter V, Jansen L, Hoffmeister M, Brenner H. Smoking and survival of colorectal cancer patients: systematic review and meta-analysis. *Ann Oncol.* 2014;25(8):1517-25. <https://doi.org/10.1093/annonc/mdu040>
5. Bouvard V, Loomis D, Guyton KZ, Grosse Y, Ghissassi FE, Benbrahim-Tallaa L, et al. Carcinogenicity of consumption of red and processed meat. *Lancet Oncol.* 2015;16(16):1599-600. [https://doi.org/10.1016/S1470-2045\(15\)00444-1](https://doi.org/10.1016/S1470-2045(15)00444-1)
6. Instituto Nacional do Câncer José de Alencar Gomes da Silva. Diretrizes para a detecção precoce do câncer de mama no Brasil. Rio de Janeiro: INCA; 2015.
7. Registro Hospitalar de Câncer do Hospital de Ensino Alcides Carneiro. Distribuição proporcional dos casos de câncer segundo faixa etária e sexo [Internet]. Petrópolis; 2018 [acessado em 14 out. 2018]. Disponível em: <https://irhc.inca.gov.br/RHCNet/consultaTabulador.action>
8. Brasil. Ministério da Saúde. Controle dos Cânceres do Colo do Útero e da Mama. Secretaria de Atenção à Saúde, Departamento de Atenção Básica, Cadernos de Atenção Básica. n. 13. Brasília: Ministério da Saúde; 2013.
9. Brasil. Ministério da Saúde. Protocolos da Atenção Básica: Saúde das Mulheres. Instituto Sírio-Libanês de Ensino e Pesquisa. Brasília: Ministério da Saúde; 2016.
10. Leite CVP. Capacitação das equipes da Estratégia Saúde da Família - um caminho para implementar a prevenção secundária do câncer de mama. Devolutiva. Petrópolis: Hospital de Ensino Alcides Carneiro, Prefeitura de Petrópolis, Faculdade de Medicina de Petrópolis, Serviço Social Autônomo Hospital Alcides Carneiro; 2017. 70 p.
11. Instituto Nacional de Câncer. Atlas da Mortalidade. Brasil: Instituto Nacional de Câncer; 2018 [acessado em 30 ago. 2018]. Disponível em: <http://mortalidade.inca.gov.br/Mortalidade/>

# EPIDEMIOLOGICAL AND CLINICAL PROFILE OF MEN WITH BREAST CANCER IN AMAZONAS, BRAZIL

Perfil epidemiológico e clínico de homens com câncer de mama no Amazonas

Antônio Cosme Carvalho Neto<sup>1\*</sup> , Gabriel Pacífico Seabra Nunes<sup>2</sup> ,  
Hilka Flávia Barra do Espírito Santo Alves Pereira<sup>1</sup> 

## ABSTRACT

The aim of the present study was to determine the epidemiological and clinical profile of men diagnosed with breast cancer at the Oncology Center Foundation (FCECON) of the state of Amazonas, Brazil. Male breast cancer is a rare disease, accounting for about 0.2% of all cancers, and it is responsible for 0.1% of male cancer deaths. Despite the rarity of the disease, statistics indicate that the incidence of male breast cancer has increased significantly from 0.86 to 1.06 per 100,000 men over the past 26 years. We conducted a retrospective longitudinal descriptive study of the medical records of male patients diagnosed with breast cancer from 2001 to 2013. In this study, there was a greater number of cases with ages over 55 years (83.54%), compared to an average age of 60-70 years reported in the literature. The histological type of the tumors analyzed was predominantly infiltrating ductal carcinoma (76.46%). We observed that tumors in stages IIIA and IIIB made up the majority of cases (58.82% in total), which was due to the patients' late search for medical care. There are no records of previous studies that address breast cancer in men in Amazonas, so we hope that our findings contribute relevant information about breast cancer in the state of Amazonas.

**KEYWORDS:** breast cancer; men; diagnosis; neoplasms; medical oncology.

## RESUMO

A presente pesquisa teve como objetivo conhecer o perfil epidemiológico e clínico de homens diagnosticados com câncer de mama na Fundação Centro de Oncologia (FCECON), do Amazonas. O câncer de mama masculino é uma doença rara, pois se apresenta em baixa frequência, representando 0,2% de todos os cânceres. É responsável por 0,1% das mortes por câncer no sexo masculino. Apesar da raridade da doença, estatísticas indicam que a incidência de câncer de mama masculino aumentou significativamente, de 0,86 a 1,06 por 100 mil homens ao longo dos últimos 26 anos. A proposta de estudo consistiu em uma pesquisa descritiva longitudinal retrospectiva, compor meio da análise de prontuários dos pacientes do sexo masculino diagnosticados com câncer de mama, no período de 2001 a 2013. Os trabalhos na literatura relatam idade média de 60 a 70 anos. Neste estudo, foi apresentado maior número de casos acima de 55 anos (83,54%). O tipo histológico dos tumores analisados foram predominantemente o carcinoma ductal infiltrante (76,46%). Neste trabalho, observou-se que os tumores em estágios IIIA e IIIB perfaziam a grande parte dos casos, 58,82% no total. Isso se deve à procura tardia dos pacientes por atendimento médico. Partindo do fato de que no estado do Amazonas não se encontraram registros de estudos anteriores que abordassem o câncer de mama em homens, como proposto por este trabalho, considera-se que a pesquisa pode somar esforços nessa empreitada. De forma mais específica, espera-se contribuir com informações qualificadas sobre o câncer de mama no estado Amazonas.

**PALAVRAS-CHAVE:** câncer de mama; homens; diagnóstico; neoplasia; oncologia.

<sup>1</sup>Fundação Centro de Controle de Oncologia – Manaus (AM), Brazil.

<sup>2</sup>Faculdade de Medicina, Universidade Nilton Lins – Manaus (AM), Brazil.

\*Corresponding author: antonioplast2013@gmail.com

Conflict of interests: nothing to declare.

Received on: 02/18/2019. Accepted on: 02/19/2019

## INTRODUCTION

The word *cancer* comes from Latin and means crab, because as the tumor grows into adjacent tissue, it looks like the shape of the crustacean<sup>1</sup>. Breast cancer is a disease caused by an abnormal growth of breast cells<sup>2</sup>.

Cancers may arise due to different risk factors, and their role in the etiology of the disease is well established today. Causes are multiple, such as environmental, cultural and socioeconomic factors, and lifestyle or habits, especially smoking and diet, but also of concern are genetic factors and the aging process itself.

Breast cancer is the most common type of cancer among women worldwide and in Brazil, after non-melanoma skin cancer, accounting for about 25% of new cases each year<sup>2</sup>. Male breast cancer is considered a rare disease, representing 0.2% of all cancers, 1% of breast cancers and 0.2% of all malignant tumors in men, and it is responsible for 0.1% of male cancer deaths. The male to female ratio is 1:100, and the disease occurs between 59 and 64 years of age<sup>3</sup>.

However, statistics indicate an increased incidence in both developed and developing countries. The incidence of male breast cancer has increased significantly from 0.86 to 1.06 per 100,000 men over the past 26 years<sup>3</sup>.

Due to the rarity of this pathology, the etiology of male breast cancer is little known. Among the main risk factors cited in the literature is family history with first-degree relatives 20% of the time. Genetic predisposition is associated with breast cancer, which can increase the risk of developing the disease by 2.5 times. Mutations in the early onset breast cancer 1 (BRCA1) gene are related to some cases, but the link between mutations in the breast cancer 2 (BRCA2) gene and male breast cancer is stronger<sup>3-5</sup>.

Most histological subtypes seen in women are also present in men, except the lobular type, which is very rare. In the literature, there are reports that exposure to electromagnetic fields results in the formation of mammary tumors in animals due to an inhibitory effect on the pineal gland, with a decrease in melatonin. Studies have shown an increased risk in this situation, but has not clearly defined the exposure time required<sup>6,7</sup>.

The clinical picture most often begins insidiously, with thickening of mammary glandular tissue, usually in the retroareolar region. There is also skin retraction, presence of solid lump, often bloody papillary discharge and, later, ulcer. The most common symptoms in male breast cancer patients are a subareolar painless nodule, nipple retraction and nipple bleeding<sup>8</sup>.

The diagnosis of breast cancer in males occurs later compared to females. In men, it occurs at age 60, whereas in women, it is detected on average 10 years earlier. This delay in diagnosis leads to advanced cases of the disease, due to lack of knowledge of the problem by the patient and often by the doctor<sup>9,10</sup>.

For breast cancer in men, the same treatment established for women is recommended: surgical treatment, after the use

or not of radiotherapy, chemotherapy and particularly hormone therapy. Breast cancer is essentially similar in the two sexes and their treatment is similar as well, but the survival rate in male patients is lower<sup>11</sup>.

The increasing incidence of cancer cases in most parts of the world means that several countries are increasingly looking to adopt effective prevention measures in primary care (related to early diagnosis) to reduce the number of new cases, and also to take measures to control and reduce mortality rates. According to the World Health Organization (WHO), about 40% of cancer deaths can be prevented, which makes prevention strategies an important component of any cancer control plan<sup>11-13</sup>.

Another aspect that deserves careful attention concerns the analyses and actions carried out in low- and middle-income countries, since according to GLOBOCAN data through the WHO Cancer Control Program, more than 70% of breast cancer deaths occur in these countries<sup>11</sup>.

In Brazil, the National Cancer Institute José Alencar Gomes da Silva (INCA) estimated for the biennium 2018–2019 600,000 new cases of cancer each year. According to this institute, 191.78/100,000 new cases are expected for women. Of these, the most frequent is breast cancer, with 59,700 new cases each year. In the North region, 1,730 new cases of breast cancer are estimated per year<sup>2</sup>.

Since there have been no previously reported studies on breast cancer in men in the state of Amazonas, we believe that the present research may make a valuable contribution.

## METHOD

A retrospective longitudinal descriptive study was conducted through the analysis of medical records of male patients diagnosed with breast cancer at the Oncology Center Foundation (FCECON), Amazonas, from 2001 to 2013.

The sample size was estimated according to the number of male breast cancer patients treated annually at the outpatient clinic of FCECON hospital, with a total of 17 patients between 2001 and 2013. The survey was census-based, with 100% of medical records of male patients diagnosed with breast cancer registered at the FCECON Medical Care and Emergency Service (SAME).

The inclusion criteria in the study were:

- male patients of any age;
- patients with breast cancer.

Data regarding age, diagnostic method, histological type, immunohistochemical panel, staging, treatment and follow-up time were collected.

The study was submitted for review by the FCECON Research Ethics Committee (CEP), through Plataforma Brasil, and was approved by the Ethics Appreciation Certificate (CAAE), No. 03845918.3.0000.0004.



## RESULTS

At FCECON do Amazonas, during the study period (2001–2013), 17 men were diagnosed with breast cancer and treated.

Regarding clinical characteristics, the following variables were considered: age (at the time of diagnosis), history of previous cancer, Breast Imaging-Reporting and Data System (BI-RADS) diagnosis, tumor location, histological type, histological grade and clinical staging.

Regarding age, at the time of diagnosis, the predominant age group was 56–65 years (41.17%,  $n = 7$ ), followed by >75 years (29.41%,  $n = 5$ ) (Table 1).

Among the men examined, 100% reported not having a history of previous cancer. Regarding mammographic diagnosis (BI-RADS), 52.94% ( $n = 9$ ) of mammograms were classified in category IV, followed by 29.41% ( $n = 5$ ), in category III, as shown in Table 1.

Regarding the location of the tumor, there was a slight predominance of the right breast (52.94%). The predominant histological type was infiltrating ductal carcinoma (76.46%,  $n = 13$ ), and other histological types found were: ductal carcinoma *in situ* (29.41%), invasive lobular carcinoma (5.88%) and invasive papillary carcinoma (5.88%). The predominant histological grade was moderately differentiated (58.82%,  $n=10$ ).

Regarding clinical staging, the most frequent stages were IIIA (29.41%) and IIIB (29.41%), followed by IIA (17.64%), while patients clinically diagnosed as stage 0, IA, IIB, and IV were few.

Regarding the characteristics of the treatments, the variables type of surgery and forms of treatment (radiotherapy and hormone therapy) were considered (Table 2). Regarding the type of surgery performed, it was evident that 88.23% ( $n = 15$ ) of cases underwent radical mastectomy, while in 11.77% ( $n = 2$ ), the surgical procedure was not performed. Patients were submitted to adjuvant treatment by radiotherapy (58.82%), chemotherapy (47.05%) and hormone therapy (58.82%). Regarding metastasis, there was no metastasis in 88.23% ( $n = 15$ ) of cases. This occurred only in two cases: bone and lung.

Table 3 shows the immunohistochemical profile, in which Ki-67 was expressed in 76.47% ( $n = 13$ ) of cases. Luminal A was the most significant, with 41.17% ( $n = 7$ ), followed by luminal B, with 32.29% ( $n = 06$ ).

Regarding the expression of markers by immunohistochemical profile, both estrogen receptor and progesterone receptor were expressed in 64.70% of the cases. HER2 was overexpressed by 5.88%, while 64.70% of cases were not expressed, as shown in Table 3.

Follow-up time was also evaluated as shown in Table 4. A period of 12 to 24 months was most common, with 23.52% ( $n = 4$ ) of patients, followed by periods of up to 12 months and 36–48 months, both 17.64% ( $n = 3$ ) of cases.

## DISCUSSION

Regarding the location of the tumor, a small difference was identified between the right (52.94%) and the left (47.056%) breast. Such numbers are close to those found in the literature.

The histological type of the analyzed tumors was infiltrating ductal, (76.46%), in agreement with reports of male breast cancers being mostly the ductal type.

**Table 1.** Clinical and diagnostic characteristics of cases of breast cancer in men.

Variables	N	%
Age at diagnosis (years)		
35–45	1	5.89
46–55	2	11.77
56–65	7	41.18
66–75	2	11.77
>75	5	29.39
History of previous cancer		
Yes	0	00.00
No	17	100
Diagnostic mammography (BI-RADS)		
I	1	5.89
III	5	29.41
IV	9	52.94
V	2	5.89
Tumor location		
Right breast	9	52.94
Left breast	8	47.06
Histological type		
Ductal carcinoma <i>in situ</i>	2	11.77
Infiltrating ductal carcinoma	13	76.45
Invasive lobular carcinoma	1	5.89
Invasive papillary carcinoma	1	5.89
Histological grade		
Undifferentiated	5	29.41
Moderately differentiated	10	58.82
Well differentiated	2	11.77
Clinical staging		
0	1	5.89
IA	1	5.89
IIA	3	17.64
IIB	1	5.89
IIIA	5	29.41
IIIB	5	29.41
IV	1	5.89

**Table 2.** Treatment characteristics in cases of breast cancer in men

Variables	N	%
Surgical treatment		
Radical mastectomy	15	88.23
None	2	11.77
Radiotherapy		
Yes	10	58.82
No	7	41.18
Chemotherapy		
Yes	8	47.05
No	9	52.95
Hormone therapy		
Yes	10	58.82
No	7	41.18
Location of metastases		
Bone	1	5.89
Lung	1	5.89
No metastasis	15	88.22

**Table 3.** Immunohistochemical profile of cases of breast cancer in men.

Variables	N	%
Ki-67		
Positive	13	76.47
Not tested	4	23.53
Luminal		
Luminal A	7	41.18
Luminal B	6	35.29
Not indicated	4	23.53
Estrogen		
Positive	11	64.70
Negative	2	11.77
Not indicated	4	23.53
Progesterone		
Positive	11	64.72
Negative	3	17.64
Not indicated	3	17.64
HER2		
Positive	1	5.89
Negative	11	64.70
Triple-negative	1	5.89
Not indicated	4	23.53

**Table 4.** Follow-up time of patients.

Variable (months)	N	%
Up to 12	3	17.64
12–24	4	23.52
24–36	2	11.77
36–48	3	17.64
48–60	2	11.77
60–72	1	5.89
>72	2	11.77

In this study, it was observed that tumors in stages IIIA and IIIB made up the majority of cases, 58.82% in total. This is due to the late search of patients for medical attention. Only 5.88% of the patients had a stage 0 tumor, carcinoma in situ, which was due to the few diagnoses made in the early stage of the tumor. Advanced tumors appeared in two cases (11.76%), stage V with pulmonary and bone metastases.

Immunohistochemistry revealed that luminal A tumors represented the largest number (41.17%), and luminal B (32.29%). Overexpressed HER2 receptor tumors occurred in only one case (5.88%). The status of estrogen and progesterone receptors was reported in 11 cases (64.70%). Only one case was reported as triple negative (5.88%).

The main treatment described in all studies was surgery, and modified radical mastectomy appeared as the most common procedure. In this study, patients underwent surgery in 88.23% (n = 15) of cases. In two cases (11.77%), no surgery was performed. In one of those cases in which surgery was not performed, the cancer was already at an advanced stage and there were lung and bone metastases. These are data similar to those of American studies, showing the similarity to our situation. Post-surgery radiotherapy was performed in only 58.82% of cases. The reasons for no radiotherapy were not noted in the medical records.

In 47.05% of cases, the patients received systemic treatment with adjuvant chemotherapy, and 58.82% were treated with tamoxifen, since they showed hormone-positive receptors<sup>1,10,11</sup>.

## CONCLUSIONS

The clinical, epidemiological and therapeutic aspects analyzed in a tertiary public health institution established a better understanding of the behavior of this disease in men during the study period.

Because it is a rare disease, prospective research on breast cancer in men will contribute to a better understanding of its biological behavior to improve the prognosis in these patients in the future.

## REFERENCES

1. Andrade SAFs de. Câncer de mama: um problema de saúde pública. *Rev Unilus Ensino Pesquisa*. 2014;11(23):70-7.
2. Instituto Nacional de Câncer José Alencar Gomes da Silva. Estimativa 2018: incidência de câncer no Brasil. Rio de Janeiro: INCA; 2018.
3. Boff RA, Polking A, Boff MI. Câncer de mama no homem. In: Boff RA, Kavanagh JJ, editores. *Ginecologia e Mastologia: um guia prático*. Caxias do Sul: EDUCS; 2002.
4. Duarte DL. Ginecomastia e câncer mamário em homem. In: Duarte DL, editor. *A mama em imagens*. Rio de Janeiro: Guanabara Koogan; 2006.
5. Lewis R. A genética do câncer. In: Lewis R. *Genética humana - conceitos e aplicações*. 5ª ed. Rio de Janeiro: Guanabara Koogan; 2004.
6. Smeltzer SC, Bare BG. Brunner & Suddarth: *Tratado de enfermagem médico-cirúrgica*. 13ª ed. Editora Guanabara; 2016. v. textbook
7. Chirife AM, Bello L, Celeste F, Giménez L, Gorostidy S. Sarcomas primários de mama. *Medicina (Buenos Aires)* [Internet]. 2006;66(2):135-8, 2006 [acessado em 15 ago. 2018]. Disponível em: <http://www.scielo.org.ar/pdf/medba/v66n2/v66n2a08.pdf>
8. Haas P, Costa AB, Souza AP de. Epidemiologia do câncer de mama em homens. *Rev Inst Adolfo Lutz*. 2009;68(3):476-81.
9. Montenegro MR. Neoplasias. In: Montenegro MR, Franco M, editores. *Patologia Processos Gerais*. 4ª ed. São Paulo: Atheneu; 2004. p. 241-54.
10. Sei M. Câncer de mama também é coisa de homem [Internet]. 2009 [acessado em 14 ago. 2018]. Disponível em: <http://www.faac.unesp.br/pesquisa/idosomidia/docs/marisa/cancermarisanoticia.pdf>
11. Brasil. Ministério da Saúde. Instituto Nacional de Câncer. *Estimativas 2010: Incidência de Câncer no Brasil*. Rio de Janeiro: INCA; 2009.
12. World Health Organization. GLOBOCAN 2012: estimated cancer incidence, mortality and prevalence worldwide in 2012 [Internet]. Lion: IARC; 2015 [acessado em 13 ago. 2018]. Disponível em: [http://globocan.iarc.fr/Pages/fact\\_sheets\\_cancer.aspx](http://globocan.iarc.fr/Pages/fact_sheets_cancer.aspx)
13. Selister R, Barcellos E. Esforço global pela saúde da mulher. *Rev Mulher Consciente*. 2009;(10).

# ONCOPLASTIC SURGERY AND IMMEDIATE BREAST RECONSTRUCTION IN BREAST CANCER PATIENTS: SATISFACTION AND QUALITY OF LIFE EVALUATION

Cirurgia oncoplástica e reconstrução mamária imediata em pacientes com câncer de mama: avaliação da satisfação e qualidade de vida

Lucimara Priscila Campos Veras Giorgi<sup>1\*</sup> , Adriana Haack de Arruda Dutra<sup>1,2</sup> 

## ABSTRACT

**Objective:** Oncoplastic surgery and breast reconstruction represent an advance in breast cancer surgeries, combining oncologic resection with plastic surgery techniques, and enabling optimal cancer treatment, good esthetic results, and improvement in patients' quality of life. The objective of this study was to evaluate the satisfaction and quality of life of patients submitted to surgical treatment of breast cancer through oncoplastic surgery and breast reconstruction techniques. **Methodology:** Cross-sectional study with women undergoing surgical treatment of breast cancer through oncoplastic and/or breast reconstruction techniques, treated in the mastology center of the Federal District, from December 2016 to May 2017. The research instrument employed to assess satisfaction and quality of life was BREAST-Q. Data analysis adopted Student's t-test or the Mann-Whitney test and simple linear regression to evaluate the relationship between age and the outcome investigated. **Results:** The final sample consisted of 15 women who met the eligibility criteria. The overall mean BREAST-Q score was greater than 54.2 for satisfaction and quality of life indicators. For each year of age, the sexual well-being score increased 0.15 ( $p < 0.02$ ); the satisfaction with medical team score, 0.83 ( $p < 0.02$ ); and the care satisfaction score, 0.23 ( $p < 0.04$ ). **Conclusion:** This study suggests that breast reconstruction improves satisfaction with breast appearance and quality of life in patients treated for breast cancer. Further longitudinal studies are necessary to elucidate the subject better.

**KEYWORDS:** breast neoplasms; mammoplasty; reconstructive surgical procedures; quality of life; patient satisfaction.

## RESUMO

**Introdução:** A cirurgia oncoplástica e reconstrutiva da mama representa um avanço nas cirurgias de câncer de mama e combina ressecção oncológica com técnicas de cirurgia plástica, possibilitando alcançar tratamento oncológico ideal, bons resultados estéticos e melhora na qualidade de vida das pacientes. Avaliar a satisfação e a qualidade de vida das pacientes submetidas ao tratamento cirúrgico do câncer de mama por meio de técnicas de cirurgia oncoplástica e reconstrutiva da mama. **Metodologia:** Estudo transversal com mulheres submetidas ao tratamento cirúrgico do câncer de mama por meio de técnicas oncoplásticas e/ou reconstrutivas da mama, atendidas no serviço de mastologia do Distrito Federal, no período de dezembro de 2016 a maio de 2017. O instrumento de pesquisa empregado para avaliar a satisfação e qualidade de vida foi o BREAST-Q. Na análise dos dados, foram utilizados os testes t ou Mann Whitney e regressão linear simples para avaliar a relação da idade com desfecho investigado. **Resultados:** A amostra final foi composta de 15 mulheres que preencheram os critérios de elegibilidade. A pontuação média global no BREAST-Q foi superior a 54.2 para os indicadores de satisfação e qualidade de vida. Observou-se que para cada ano de idade houve um aumento de 0.15 no escore de bem-estar sexual ( $p < 0.02$ ), 0.83 pontos no escore de satisfação com a equipe médica ( $p < 0.02$ ) e 0.23 pontos no score de satisfação com o cuidado recebido ( $p < 0.04$ ). **Conclusão:** Este estudo sugere que a reconstrução mamária melhora a satisfação com a aparência das mamas e a qualidade de vida nas pacientes tratadas de câncer de mama. É necessário a realização de novos estudos longitudinais que permitam elucidar melhor o tema.

**PALAVRAS-CHAVE:** neoplasias da mama; mamoplastia; procedimentos cirúrgicos reconstrutivos; qualidade de vida; satisfação do paciente.

<sup>1</sup>School of Health Sciences – Brasília (DF), Brazil.

<sup>2</sup>Universidade de Brasília – Brasília (DF), Brazil.

\*Corresponding author: lucimarapriscula@gmail.com

Conflict of interests: nothing to declare.

Received on: 12/11/2018. Accepted on: 02/24/2019



## INTRODUCTION

Breast neoplasm is the most common cancer among women worldwide, affecting more than 1.5 million of them annually<sup>1</sup>. In Brazil, it corresponds to approximately 28% of new patients each year, with 59,700 new cases estimated for 2018<sup>2</sup>.

Breast cancer is a chronic disease, and genetic and epigenetic events can result in the multiplication of abnormal cells, forming a tumor with different behavior patterns and therapeutic responses<sup>3</sup>.

Surgical treatment of breast cancer has made great strides over the years, with aggressive and mutilating surgeries giving way to conservative treatments, due to their association with radiotherapy and overall and disease-free survival rates being similar to mastectomy rates. Since the '80s, this treatment incorporated breast plastic surgery techniques, aiming to improve esthetic and functional results in the breast<sup>4-6</sup>.

The patient affected by this disease must be thoroughly evaluated. The therapy adopted, surgical or non-surgical, should aim to reduce morbidity and mortality, as well as improve the physical and psychological well-being of patients<sup>7,8</sup>. Surgical interventions associated with breast cancer treatment can have a negative impact on the patient's personal satisfaction and quality of life, often manifested through anxiety, shame, significant mood disturbances, decreased sexual interest, and depression<sup>7,8</sup>.

Several studies affirm that oncoplastic surgery has a positive result regarding efficacy and quality of life of women with breast cancer, including favorable esthetic outcomes<sup>9-11</sup>.

Immediate breast reconstruction has become an integral part of breast surgery, improving postoperative quality of life and mitigating deleterious effects. This procedure can help patients restore their body image and promotes physical and psychological well-being, in addition to being considered oncologically safe<sup>12-14</sup>.

Oncoplastic surgery and breast reconstruction play an important role in the management of breast cancer. Estimates indicate that more than 95,000 breast reconstructions are performed annually worldwide<sup>15</sup>. In Brazil, only 10% of the patients submitted to mastectomy have access to immediate breast reconstruction<sup>16</sup>.

Al-Ghazal and Schain evaluated the impact of immediate breast reconstruction on quality of life and concluded that patients who undergo this type of surgery are less predisposed to suffer from psychological disorders<sup>14,17</sup>.

Understanding the effects that breast cancer treatment can have on the physical and psychological well-being of patients affected by the disease is determinant in guiding care and search strategies that can minimize psychological imbalance and increase acceptance of body image. Nonetheless, we found no studies on the topic in the Federal District. This study aimed to evaluate the satisfaction and quality of life of patients submitted to surgical treatment of breast cancer through oncoplastic surgery and breast reconstruction.

## METHODOLOGY

### Design/population

This is a cross-sectional study with women treated in the mastology center of the Federal District Base Hospital, who underwent surgical treatment of breast cancer through oncoplastic surgery and immediate breast reconstruction from December 2016 to May 2017. The sample size was defined according to the flow of women treated in the institution who needed breast reconstruction. Among the 61 women treated for breast cancer, only 27 (44.26%) underwent breast reconstruction (Figure 1).

The Human Research Ethics Committee of the State Department of Health of the Federal District approved this research under name and registration: Presentation Certificate for Ethical Assessment 61442116.3.0000.5553. All women who participated in the present investigation signed the Informed Consent Form.

### Eligibility criteria

#### Inclusion criteria

We selected female patients of any age diagnosed with primary breast cancer and surgically treated with oncoplastic surgery and immediate breast reconstruction.

#### Exclusion criteria

We excluded patients diagnosed with systemic disease, inflammatory carcinoma, and those submitted to late breast reconstruction; deceased patients; those not found; the ones who did not sign the Informed Consent Form; or who refused to participate in the study.

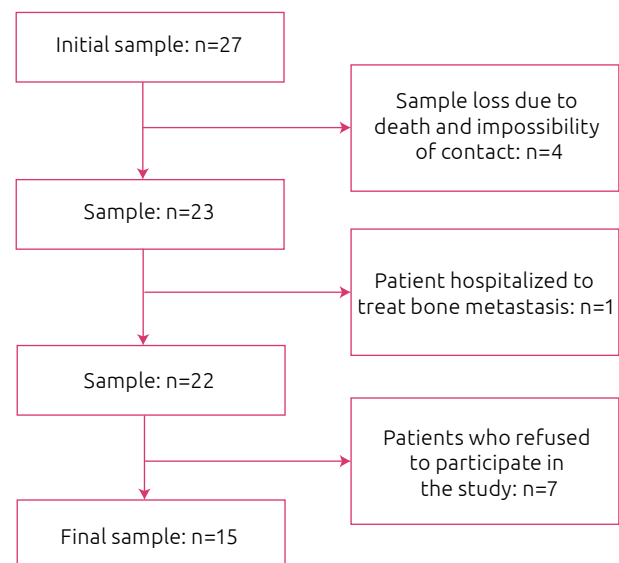


Figure 1. Selection of participants.

### Data collection procedure

Data collection initially consisted of identifying the names of patients submitted to surgical interventions according to eligibility criteria, described in the hospital surgical records. This information allowed us to find them in the electronic medical record.

After identification, we contacted them by telephone to schedule a medical appointment. The patients were invited to participate in the research and those who accepted signed the Informed Consent Form.

During data collection, we applied two questionnaires: sociodemographic and clinical characteristics; and BREAST-Q, a validated instrument with questions related to satisfaction and quality of life. All steps of data collection were individual to ensure the privacy and confidentiality of the participant. We gathered all clinical and anatomopathological data regarding the tumor in the electronic medical record after the interview. Patients who did not visit the ambulatory or did not answer the telephone call were contacted again two weeks after the first try.

### Data collection instrument

The survey was divided into sections:

- Identification and sociodemographic data;
- Clinical variables;
- Treatment-related variables;
- BREAST-Q.

### Criteria to define exposure and outcome

#### Exposure: Oncoplastic surgery and breast reconstruction

Women with primary breast cancer operated on using the following surgical techniques: reconstructive surgery (nipple-sparing mastectomy, skin-sparing mastectomy), volume displacement (glandular rotation, round block, oncoplastic reduction, elevation and centralization of the nipple-areola complex and areola complex) and volume replacement (latissimus dorsi muscle flap or transverse rectus abdominis musculocutaneous flap). This study had no comparison group, so only women who underwent surgical treatment were evaluated.

#### Outcome: Quality of life and patient satisfaction after surgery

We used the validated BREAST-Q to assess quality of life and patient satisfaction. This study applied the postoperative scale of the breast reconstruction module. This module is divided into multiple independent scales: health-related quality of life, including physical, psychosocial, and sexual well-being; patient satisfaction, which involves breast, outcome, and care.

Each patient response was entered into the Q-score software to provide a full scale ranging from 0 to 100 points. We classified quality of life and satisfaction with surgical results according to the score produced, with higher scores representing better satisfaction or quality of life.

### Data analysis procedure

The data collected were transcribed into an Excel spreadsheet for statistical analysis.

First, we performed a descriptive data analysis for categorical variables. Subsequently, we calculated medians, means, and standard deviations for the numerical information; visually inspected histograms; and used the Kolmogorov-Smirnov normality test to evaluate data distribution. Next, we used Student's t-test or the Mann-Whitney test with a 5% significance level, according to the classification of the homogeneity of results. Finally, the beta coefficients and their 95% confidence intervals were determined by simple linear regression using ordinary least squares to estimate the effect of the continuous age variable on satisfaction and quality of life indicators. The model used the  $R^2$  obtained in the analysis above. We performed the data analysis in the statistical package STATA®, version 15 for Windows, serial number: 301506206729 and presented the findings in tables and graphs.

## RESULTS

In total, 61 patients were submitted to surgical treatment of breast cancer during the study period, and only 27 (44.26%) women had their breasts reconstructed. The final sample of this investigation consisted of 15 (24.59%) women who underwent oncoplastic surgery and breast reconstruction and met the eligibility criteria of the study.

Their mean age was 46.73 years ( $\pm 7.16$ ), and the median age was 48 years, ranging from 35 to 60 years. Only 2 (13.33%) patients had not completed elementary school, 9 (60%) had no partners, and 11 (73.33%) had no stable employment (Table 1).

Two (13.33%) women had a family history of breast cancer, 2 (13.33%) were nulliparas, 14 (93.33%) had no diagnosis of diabetes, 12 (80%) had no diagnosis of hypertension, and 14 (93.33%) did not smoke (Table 2).

The most frequent tumor site was the upper outer quadrant, and 10 (66.67%) patients did not have clinically involved axillary lymph nodes. Most participants presented initial clinical staging of the disease. Nine (60%) patients were submitted to neoadjuvant chemotherapy, 9 (40%) to radiotherapy, and 11 (73.33%) to hormone therapy. Two (13.33%) patients could not undergo radiotherapy because they were not within the ideal deadline stipulated for the treatment. Immunohistochemical analysis indicated the molecular subtype luminal B as the most common finding (Table 3).

All cases were diagnosed as invasive ductal carcinoma, and 7 (58.33%) had histological grade 2. Neoadjuvant chemotherapy hindered the histological grade evaluation in three patients. We highlight that most patients underwent mastectomy followed by breast reconstruction, while the others were submitted to oncoplastic breast surgery. All women presented free surgical margins (Table 3).

The most used surgical techniques were nipple-sparing mastectomy followed by mastectomy and latissimus dorsi muscle flap with breast prosthesis. Oncoplastic techniques were preferred for symmetrization.

**Table 1.** Sociodemographic and lifestyle characteristics of women who underwent immediate breast reconstruction, treated in a public hospital in the Federal District, Brazil, 2017 (n=15).

Variables	N	%
Education		
Middle school	6	40.00
High school	6	40.00
College	1	6.67
Incomplete elementary school or with no schooling	2	13.33
Marital status		
Married	3	20.00
Domestic partnership	3	20.00
Single	4	26.67
Divorced	3	20.00
Widow	2	13.33
Occupation		
Stable employment	4	26.67
Informal employment	3	20.00
Not working or working at home	8	53.33

**Table 2.** Health and family history of women who underwent immediate breast reconstruction, treated at a public hospital in the Federal District, Brazil, 2017 (n=15).

Variables	N	%
Family history of breast cancer		
Yes	2	13.33
No	13	86.67
Parity		
Nullipara	2	13.33
Primipara	4	26.67
Multipara	9	60.00
Diabetes mellitus		
Yes	1	6.67
No	14	93.33
Arterial hypertension		
Yes	3	20.00
No	12	80.00
Previous breast surgeries		
Yes	2	13.33
No	13	86.67
Smoker		
Yes	1	6.67
No	14	93.33

**Table 3.** Variables related to cancer diagnosis and treatment in women who underwent immediate breast reconstruction, treated in a public hospital in the Federal District, Brazil, 2017 (n=15).

Variables	N	%
Breast size		
Big	1	6.67
Satisfactory	11	73.33
Small	3	20.00
Breast symmetry		
Yes	7	46.67
No	8	53.33
Desire to reconstruct the NAC		
Not applicable	4	26.67
Yes	11	73.33
Chemotherapy		
Adjuvant	4	26.67
Neoadjuvant	9	60.00
No	2	13.33
Radiotherapy		
Yes	9	40.00
No	6	60.00
Hormone therapy		
No	4	26.67
Yes	11	73.33
Location		
Upper outer quadrant (UOQ)	6	40.00
Upper inner quadrant (UIQ)	3	20.00
UIQ and central portion (CP)	1	6.67
CP	1	6.67
Junction of the lower quadrants (JLQ)/6 o'clock	1	6.67
Junction of the upper quadrants (JUQ)/12 o'clock	3	20.00
Clinical evaluation of the axilla		
Positive	5	33.33
Negative	10	66.67
Type of surgery		
Radical	11	73.33
Conservative	4	26.67
Clinical staging		
1 A	1	6.67
2 A	7	46.67
2 B	3	20.00
3 A	3	20.00
3 B	1	6.67
Histological type		
IDC	15	100.00
Histological grade		
1	3	25.00
2	7	58.33
3	2	16.67
Tumor subtype		
HER2 Hybrid	3	20.00
Luminal A	5	33.33
Luminal B	6	40.00
Triple negative	1	6.67
Surgical margin		
Free	15	100.00
Surgical resurfacing		
No	15	100.00
Early complications		
Yes	6	40.00
No	9	60.00
Surgical technique (cancerous breast)		
Nipple-sparing mastectomy with prosthesis	2	13.33
Skin-sparing mastectomy with prosthesis	5	33.33
Round block	2	13.33
Oncoplastic reduction with superior pedicle	1	6.67
Oncoplastic reduction with inferior pedicle	1	6.67
Latissimus dorsi muscle flap with breast prosthesis	4	26.67
Symmetrization		
Round block	1	6.67
Oncoplastic reduction with superior pedicle	3	20.00
Oncoplastic reduction with inferior pedicle	2	13.33
Breasts unsymmetrized	9	60.00

Less than half had early complications, with seroma (4–26.66%) and dehiscence (2–13.33%) being the main ones. All cases of dehiscence were submitted to additional sutures.

Most women perceived breast size as satisfactory. Nevertheless, more than half of them considered their breasts as asymmetrical. Only 2 (13.33%) participants underwent previous breast surgeries. All patients who had their nipple areola complex amputated expressed a desire to reconstruct it (Table 4).

Regarding satisfaction and quality of life indicators, the overall mean score was greater than 54.2 (Table 4). In the analysis of continuous variables, women presented higher average satisfaction indicators when they did not undergo radiotherapy and did not suffer surgical complications, although this result was not considered statistically significant for the variables assessed.

For each year of age, the sexual well-being score increased 0.15 ( $p < 0.02$ ); the satisfaction with the medical team score, 0.83 ( $p < 0.02$ ); and the care satisfaction score, 0.23 ( $p < 0.04$ ). The variables psychosocial well-being, physical well-being, satisfaction with breast, satisfaction with outcome, satisfaction with information, and satisfaction with surgeon were not statistically significant for the age of the participants (Figure 2).

## DISCUSSION

The main results of this study show that patients submitted to breast reconstruction and oncoplastic surgery techniques present an overall mean score for satisfaction and quality of life higher than 50 points on a scale ranging from 0 to 100.

For many years, satisfaction with the esthetic outcome and quality of life assessment were set aside, and the focus was essentially on the oncological treatment of breast cancer. The breast has always been considered a symbol of femininity and the psychosocial impact of its absence or deformity on the patient started to be highlighted in the treatment of breast cancer<sup>18,19</sup>.

Oncoplastic surgery and breast reconstruction have reached wide acceptance and allow patients to have adequate oncological treatment, with good esthetic results and improvement in their well-being.

Dean & Crittenden assessed pre- and postoperative quality of life in patients submitted to breast reconstruction at different times and observed that it was highly effective in terms of psychosocial, physical, and sexual well-being and the satisfaction with breasts when comparing preoperative scores with those calculated 6 months after the reconstruction<sup>9</sup>.

Howes et al. showed that women submitted to immediate breast reconstruction had better indicators of satisfaction with surgical results. Regarding sexual well-being, women who underwent mastectomy with reconstruction reached higher scores when compared to those who had conservative breast surgery or mastectomy without reconstruction<sup>10</sup>. The research by Shekhawat et al. revealed that patients submitted to therapeutic mastectomy had low scores for sexual well-being<sup>11</sup>.

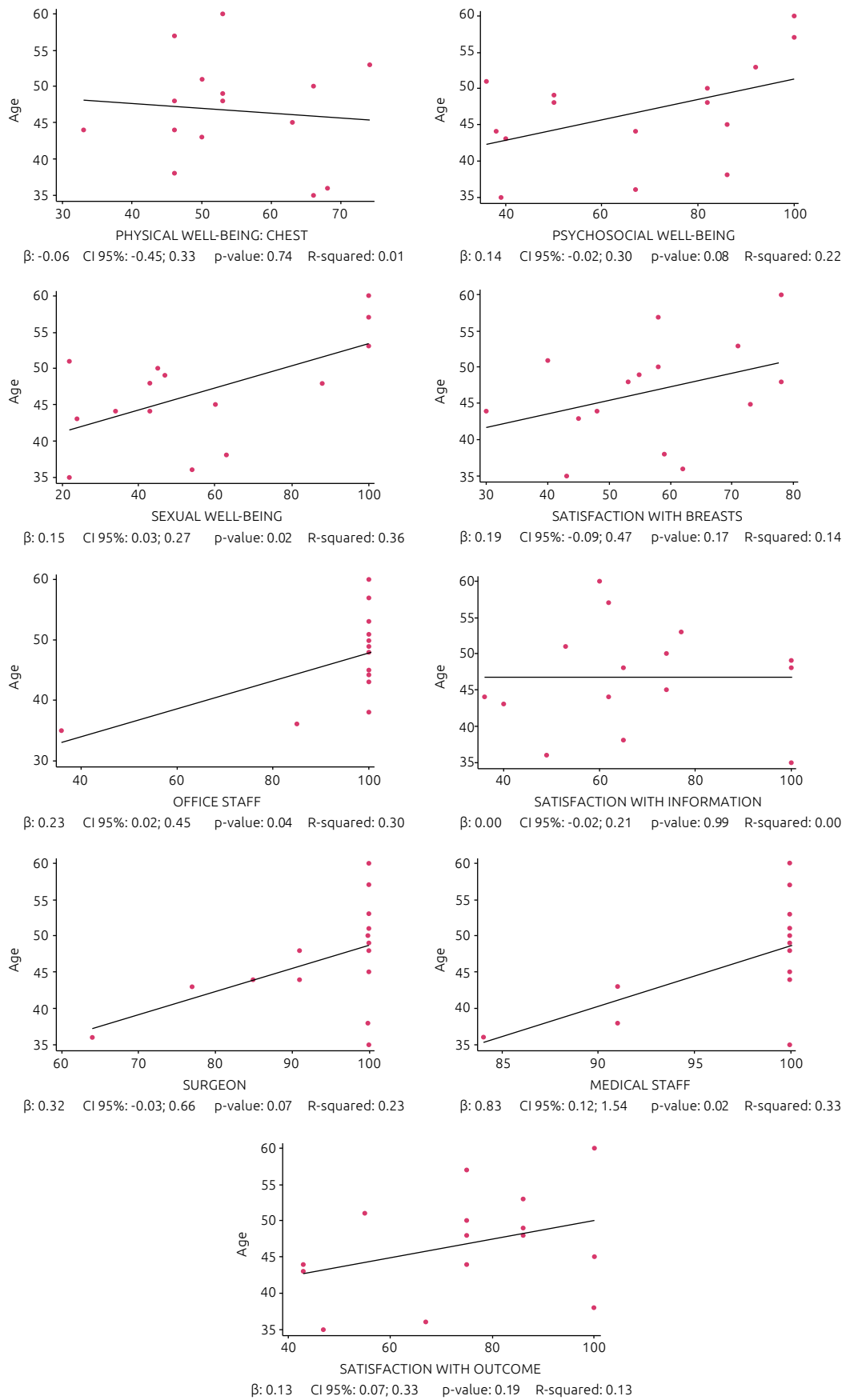
The study by Shekhawat indicated that breast reconstruction has a positive impact on the quality of life of women undergoing surgical treatment. The authors found that patients not submitted to breast reconstruction presented sexuality-related and psychological issues<sup>11</sup>.

Some studies demonstrated that most patients are satisfied with the surgeon and the information provided by this professional<sup>11</sup>. Susarla et al. evaluated the satisfaction of patients undergoing immediate reconstruction with implants in one or two stages and found that two-stage reconstruction was associated with greater satisfaction with the medical team and office staff<sup>20</sup>. The present research showed that the satisfaction score with the medical team and office staff was high, corroborating the findings of the mentioned studies. The research carried out by Ng et al. indicated results contrary to those presented in this study<sup>21</sup>.

**Table 4.** Measures of central tendency and dispersion of general characteristics and satisfaction and quality of life indicators in women who underwent immediate breast reconstruction, treated in a public hospital in the Federal District, Brazil, 2017 (n=15).

Variables	Median	Mean	Standard deviation ( $\pm$ )	Minimum–maximum
Age (years)	48	46.73	7.16	35–60
Body mass index	25.71	25.92	3.65	20.61–33.09
Physical well-being	53	54.2	11.00	33–74
Psychosocial well-being	67	67.66	23.70	36–100
Sexual well-being	47	56.33	28.36	22–100
Satisfaction with breasts	58	56.73	14.20	30–78
Satisfaction with outcomes	75	74.2	19.86	43–100
Satisfaction with information	65	67.8	20.30	36–100
Satisfaction with surgeon	100	93.87	10.84	64–100
Satisfaction with medical team	100	97.73	4.93	84–100
Satisfaction with care	100	94.73	16.70	36–100





**Figure 2.** Linear regression graphs and satisfaction and quality of life indicators in women who underwent immediate breast reconstruction, treated in a public hospital in the Federal District, Brazil, 2017 (n=15).

Egro et al. found an average breast satisfaction index of 69.8. The immediate reconstruction group had higher satisfaction rates<sup>22</sup>. In our study, the average satisfaction index was 73.69 points for the indicators investigated.

Complication rates in oncoplastic surgeries range from 10 to 60% and include seroma, hematoma, nipple necrosis, infection, wound dehiscence, and late wound healing<sup>22-27</sup>. This investigation found only two of these complications: seroma and operative wound dehiscence.

Patients surgically treated for breast cancer often have chest wall deformities and large asymmetries, which can lead to low self-esteem<sup>28</sup>. This change in the perceived body image is frequently related to depressive symptoms and dissatisfaction with social and sexual life in these patients, preventing them from maintaining a good quality of life<sup>29,30</sup>. Breast reconstruction has the purpose of restoring their body image, minimizing defects caused by surgery, and consequently improving quality of life and satisfaction with breast contour<sup>12,31</sup>.

Regarding the limitations of this research, we emphasize that its final sample is not representative of the women treated in the reference center of the Federal District, due to low participant adherence and the reduced number of procedures with immediate breast reconstruction. The sample size portrays the cases of total or partial breast reconstruction in the service, which suggests that few surgeons are qualified to perform the necessary techniques, cost of these procedures to the public system is high, and access to patients in the postoperative follow-up is difficult. The center rarely performs late breast reconstruction, considering that surgeries are primarily conducted to treat the disease.

Another weakness of the study was not having a comparison group to evaluate risk measures. This fact is related to selection

bias of research participants. Lastly, we can mention another limitation: the memory bias of the women interviewed. Most of the information collected was self-reported, which might affect the findings of this research.

The strengths of this study include a validated instrument used to evaluate satisfaction and quality of life of the women surgically treated, in an attempt to qualify the produced evidence and improve the internal validity of this investigation. We used robust analytical techniques, such as linear regression, to evaluate the effect of age on quality of life indicators.

## CONCLUSION

This study evaluated satisfaction and quality of life in patients submitted to partial or total breast reconstruction after breast cancer treatment in a mastology center and identified the profile of these patients and the number of reconstructions performed over a period of time. These data are just an initial step to show the service how breast reconstruction can improve quality of life and restore the body image of breast cancer patients.

The number of women submitted to oncoplastic surgery and breast reconstruction who agreed to participate in this study, even though not corresponding to the total number of reconstructions performed in the service, is superior to that described in the literature. This study suggests that breast reconstruction improves satisfaction with breast appearance and quality of life in patients treated for breast cancer. Further longitudinal studies with a larger number of patients and different comparison groups are necessary to improve the scientific evidence on the subject.


## REFERENCES

1. World Health Organization. Breast Cancer [Internet]. Geneva: World Health Organization [accessed on Feb. 17, 2018]. Available at: <http://www.who.int/cancer/prevention/diagnosis-screening/breast-cancer/en>
2. Instituto Nacional de Câncer. Tipos de câncer [Internet]. Brazil: Instituto Nacional de Câncer [accessed on Feb. 17, 2018]. Available at: [http://www2.inca.gov.br/wps/wcm/connect/tiposdecancer/site/home+/mama/cancer\\_mama](http://www2.inca.gov.br/wps/wcm/connect/tiposdecancer/site/home+/mama/cancer_mama)
3. Instituto Nacional de Câncer. Conceito e magnitude do câncer de mama [Internet]. Brazil: Instituto Nacional de Câncer [accessed on Feb. 17, 2018]. Available at: [http://www2.inca.gov.br/wps/wcm/connect/acoas\\_programas/site/home/nobrasil/programa\\_controle\\_cancer\\_mama/conceito\\_magnitude](http://www2.inca.gov.br/wps/wcm/connect/acoas_programas/site/home/nobrasil/programa_controle_cancer_mama/conceito_magnitude)
4. Chagas CR, Menke CH, Vieira R, Boff RA. Tratado de Mastologia da SBM. Rio de Janeiro: Revinter; 2011.
5. Veronesi U, Cascinelli N, Mariani L, Greco M, Saccozzi R, Luini A, et al. Twenty-year follow-up of a randomized study comparing breast-conserving surgery with radical mastectomy for early breast cancer. *N Engl J Med*. 2002;347(16):1227-32. <https://doi.org/10.1056/NEJMoa020989>
6. Kaur N, Petit JY, Rietjens M, Maffini F, Luini A, Gatti G, et al. Comparative study of surgical margins in oncoplastic surgery and quadrantectomy in breast cancer. *Ann Surg Oncol*. 2005;12(7):539-45. <https://doi.org/10.1245/ASO.2005.12.046>
7. Troidl H, Kusche J, Vestweber K, Eypasch E, Koeppen L, Bouillon B. Quality of Life: An Important Endpoint Both in Surgical Practice and Research. *J Chron Dis*. 1987;40(6):523-8. [https://doi.org/10.1016/0021-9681\(87\)90009-9](https://doi.org/10.1016/0021-9681(87)90009-9)
8. Revicki D. FDA Draft Guidance and Health-Outcomes Research. *Lancet*. 2007;369(9561):540-2. [https://doi.org/10.1016/S0140-6736\(07\)60250-5](https://doi.org/10.1016/S0140-6736(07)60250-5)

9. Dean NR, Crittenden T. A five year experience of measuring clinical effectiveness in a breast reconstruction service using the BREAST-Q patient reported outcomes measure: A cohort study. *J Plast Reconstr Aesthet Surg.* 2016;69(11):1469-77. <http://dx.doi.org/10.1016/j.bjps.2016.08.015>
10. Howes BH, Watson DI, Xu C, Fosh B, Canepa M, Dean NR. Quality of life following total mastectomy with and without reconstruction versus breast-conserving surgery for breast cancer: A case-controlled cohort study. *J Plast Reconstr Aesthet Surg.* 2016;69(9):1184-91. <http://dx.doi.org/10.1016/j.bjps.2016.06.004>
11. Shekhawat L, Busheri L, Dixit S, Patel C, Dhar U, Koppiker C. Patient-reported outcomes following breast reconstruction surgery and therapeutic mammoplasty: Prospective evaluation 1-year post-surgery with BREAST-Q questionnaire. *Indian J Surg Oncol.* 2015;6(4):356-62. <https://doi.org/10.1007/s13193-015-0432-x>
12. Oiz B. Breast Reconstruction and Psychological Benefit. *An Sist Sanit Navar.* 2005;28(Suppl. 2):19-26.
13. Pusic A, Chen CM, Cano S, Klassen A, McCarthy C, Collins ED, et al. Measuring Quality of Life in Cosmetic and Reconstructive Breast Surgery: A Systematic Review of Patient Reported Outcome Instruments. *Plast Reconstr Surg.* 2007;120(4):823-37. <https://doi.org/10.1097/01.prs.0000278162.82906.81>
14. Schain WS, Wellisch DK, Pasnau RO, Landsverk J. The Sooner the Better: A Study of Psychological Factors in Woman Undergoing Immediate Versus Delayed Breast Reconstruction. *Am J Psychiatry.* 1985;142(1):40-6. <https://doi.org/10.1176/ajp.142.9.A40>
15. American Society of Plastic Surgeons. 2013 Plastic Surgery Statistics Report [Internet]. American Society of Plastic Surgeons; 2013 [accessed on Dec. 17, 2017]. Available at: <https://www.plasticsurgery.org/documents/News/Statistics/2013/plastic-surgery-statistics-full-report-2013.pdf>
16. Sociedade Brasileira de Mastologia. Menos de 10% das mulheres brasileiras têm acesso à cirurgia de reconstrução mamária [Internet]. Brazil: Sociedade Brasileira de Mastologia [accessed on June 21, 2016]. Available at: [http://www.sbmastologia.com.br/index.php?option=com\\_content&view=article&id=847:menos-de-10-das-mulheres-brasileiras-têm-acesso-à-cirurgia-de-reconstrução-mamária&catid=141&Itemid=684&device](http://www.sbmastologia.com.br/index.php?option=com_content&view=article&id=847:menos-de-10-das-mulheres-brasileiras-têm-acesso-à-cirurgia-de-reconstrução-mamária&catid=141&Itemid=684&device)
17. Al-Ghazal SK, Sully L, Fallowfield L, Blamey RW. The Psychological Impact of Immediate Rather than Delayed Breast Reconstruction. *Eur J Surg Oncol.* 2000;26(1):17-9.
18. Castilho RS, Amorim WC, Santos Júnior JL, Rezende CAL. Cirurgia conservadora da mama 1981-2002: uma visão histórica. *Rev Médica de Minas Gerais.* 2008;18(1):49-55.
19. Bostwick J, Vasconez LO, Jurkiewics MJ. Breast reconstruction after a radical mastectomy. *Plast Reconstr Surg.* 1978;61(5):682-93.
20. Susarla SM, Ganske I, Helliwell L, Morris D, Eriksson E, Chun YS. Comparison of clinical outcomes and patient satisfaction in immediate single-stage versus two-stage implant-based breast reconstruction. *Plast Reconstr Surg.* 2015;135(1):1e-8e. <https://doi.org/10.1097/PRS.0000000000000803>
21. Ng SK, Hare RM, Kuang RJ, Smith KM, Brown BJ, Hunter-Smith DJ. Breast reconstruction post mastectomy patient satisfaction and decision making. *Ann Plast Surg.* 2016;76(6):640-4. <https://doi.org/10.1097/SAP.0000000000000242>
22. Egro FM, Pinell-White X, Hart AM, Losken A. The use of reduction mammoplasty with breast conservation therapy: an analysis of timing and outcomes. *Plast Reconstr Surg.* 2015;135(6):963e-71e. <https://doi.org/10.1097/PRS.0000000000001274>
23. Losken A, Styblo TM, Carlson GW, Jones GE, Amerson BJ. Management algorithm and outcome evaluation of partial mastectomy defects treated using reduction or mastopexy techniques. *Ann Plast Surg.* 2007;59(3):235-42. <https://doi.org/10.1097/SAP.0b013e31802ec6d1>
24. Spear SL, Pelletiere CV, Wolfe AJ, Tsangaris TN, Pennanen MF. Experience with reduction mammoplasty combined with breast conservation therapy in the treatment of breast cancer. *Plast Reconstr Surg.* 2003;111(3):1102-9. <https://doi.org/10.1097/01.PRS.0000046491.87997.40>
25. Losken A, Pinell XA, Eskenazi B. The benefits of partial versus total breast reconstruction for women with macromastia. *Plast Reconstr Surg.* 2010;125(4):1051-6. <https://doi.org/10.1097/PRS.0b013e3181d0ab08>
26. Patel KM, Hannan CM, Gatti ME, Nahabedian MY. A head-to-head comparison of quality of life and aesthetic outcomes following immediate, staged-immediate, and delayed oncoplastic reduction mammoplasty. *Plast Reconstr Surg.* 2011;127(6):2167-75. <https://doi.org/10.1097/PRS.0b013e3182131c1c>
27. van Paridon MW, Kamali P, Paul MA, Wu W, Ibrahim AMS, Kansal KJ, et al. Oncoplastic breast surgery: Achieving oncological and aesthetic outcomes. *J Surg Oncol.* 2017;116(2):195-202. <https://doi.org/10.1002/jso.24634>
28. Parker PA, Youssef A, Walker S, Engquist KB, Cohen L, Gritz ER, et al. Short-Term and Long-Term Psychosocial Adjustment and Quality of Life in Women Undergoing Different Surgical Procedures for Breast Cancer. *Ann Surg Oncol.* 2007;14(11):3078-89. <https://doi.org/10.1245/s10434-007-9413-9>
29. Schain WS, Jacobs E, Wellisch DK. Psychological Issues in Breast Reconstruction: Intrapsychic, Interpersonal and Practical Concerns. *Clin Plast Surg.* 1984;11(2):237-51.
30. Cho BC, McCready DR. Oncological Principles in Breast Reconstruction. *Clin Plast Surg.* 2007;34(1):1-13. <https://doi.org/10.1016/j.cps.2006.11.005>
31. Cano SJ, Klassen A, Pusic A. The science behind quality of life measurement: a primer for plastic surgeons. *Plast Reconstr Surg.* 2009;123(3):98e-106e. <https://doi.org/10.1097/PRS.0b013e31819565c1>

# EVALUATION OF DELAYS IN DIAGNOSIS AND TREATMENT OF BREAST CANCER IN A REFERENCE CENTER: A RETROSPECTIVE ANALYSIS

Avaliação do atraso no diagnóstico e tratamento do câncer de mama em um centro de referência: uma análise retrospectiva

Artur Lício Rocha Bezerra<sup>1</sup> , Maria Carolina Muniz Bezerra<sup>1\*</sup> , André Filipe Ferreira Lopes dos Santos<sup>1</sup> ,  
Fernando Moura Lima<sup>1</sup> , Isabel Tenório de Brito Almeida<sup>1</sup> , Larissa Miranda Galvão Ferreira<sup>1</sup> 

## ABSTRACT

**Objectives:** To evaluate possible causes of delay in the diagnosis and treatment of breast cancer in a population treated exclusively by the Brazilian Unified Health System (SUS) of Brazil. **Methods:** A retrospective analysis of the medical patient charts of 173 patients treated at IMIP, between January 2011 and December 2017. Time intervals (biopsy and treatment intervals) were associated with sociodemographic and clinical variables utilizing statistical analysis. **Results:** The mean age was 56.36 years, 116 (67.1%) were from Recife's metropolitan region and the majority were illiterate or had up to 8 years of schooling. The biopsy interval ranged between 0 and 826 days (41.42; med 12.50) while the treatment interval ranged from 0 and 460 days (94.6; med 69.0). There was no statistically significant association of these intervals with clinical variables such as origin, educational level, age, tumor staging, type of treatment and clinical situation of the patients at the end of the study. **Conclusions:** Although the early diagnosis and treatment of breast cancer are fundamental, the data of this present investigation showed that median delays of 3 months for starting treatment in a public hospital were not associated with worsening of prognosis or survival of the patients.

**KEYWORDS:** breast cancer; late diagnosis; survival.

## RESUMO

**Objetivos:** Avaliar possíveis causas de atraso no diagnóstico e tratamento do carcinoma mamário em uma população atendida exclusivamente pelo Sistema Único de Saúde (SUS) do Brasil. **Métodos:** Foi realizada uma análise retrospectiva dos prontuários de 173 pacientes tratadas no Instituto Materno Infantil Prof. Fernando Figueira (IMIP), entre janeiro de 2011 e dezembro de 2017. Intervalos de tempo (intervalo de biópsia e de tratamento) foram relacionados com variáveis sociodemográficas e clínicas por meio de análise estatística. **Resultados:** A média de idade foi 56,36 anos, 116 mulheres (67,1%) eram da região metropolitana do Recife e a maioria era analfabeta ou tinha até 8 anos de escolaridade. O intervalo de biópsia variou entre 0 e 826 dias (41,42; med 12,50), enquanto o intervalo de tratamento variou entre 0 e 460 dias (94,6; med 69,0). Não houve associação estatisticamente significativa desses intervalos com variáveis clínicas como procedência, nível educacional, idade, estadiamento, tipo de tratamento e situação clínica das pacientes ao final do estudo. **Conclusões:** Embora o diagnóstico e tratamento precoces do câncer de mama sejam fundamentais, os dados da presente investigação mostraram que atrasos medianos de três meses para início do tratamento em hospital público não foram associados com piora do prognóstico ou sobrevida das pacientes.

**PALAVRAS-CHAVE:** neoplasias da mama; diagnóstico tardio; sobrevida.

<sup>1</sup>Faculdade Pernambucana de Saúde – Recife (PE), Brazil.

\*Corresponding author: camunizb@hotmail.com

Conflict of interests: nothing to declare.

Received: 09/27/2018. Accepted: 02/10/2019

## INTRODUCTION

According to the National Cancer Institute (INCA), breast cancer has a high incidence among Brazilian women, with an estimated 57,960 new cases by 2017. Pernambuco in the Northeast of Brazil has the highest incidence of this type of cancer, with an estimated rate of 53.18 new cases of breast cancer per 100,000 women for the biennium 2016/20171.

When detected and treated early, breast cancer has a good prognosis. Despite this, survival in developing countries is 57%, in contrast with 73% in developed countries<sup>2</sup>. The high mortality rate for breast cancer in the less developed nations can be explained mainly by the lack of screening programs and organization, with a large proportion of cases diagnosed at an advanced stage. In addition, the population's lack of knowledge about cancer, fear, prejudice and difficulty accessing health services increases the number of individuals who delay or do not adhere to treatment<sup>3,4</sup>.

The literature demonstrates that the effective screening of breast cancer through mammography can detect the disease during the pre-clinical phase, interrupting its natural history and have a favorable impact on the mortality rate<sup>4</sup>. Consequently, delays leading to diagnostic and / or treatment delay allow tumor growth, resulting in more aggressive treatment, higher costs and the potential to reduce the chances of cure for patients.

The definition of the delay in time in cancer care is comprised of three different moments: the first occurs from the onset of symptoms until the first doctor's consultation; the second, between the first consultation and the first access to the specialized service; and the third, from the first evaluation in the specialized service to the specific treatment<sup>5-7</sup>. A systematic review showed that a delay of more than three months between symptom identification and treatment is associated with a 12% decrease in survival for patients with breast cancer<sup>8</sup>. Access and time for the diagnosis and treatment of breast cancer vary in different regions of Brazil. A preliminary study, conducted at the clinical oncology services of the Faculdade de Medicina do ABC (FMABC), showed that the delay in the diagnosis of breast cancer is mostly related to the time it takes the patient to seek health services from the detection of the first signal or symptom<sup>9</sup>.

Systematic review studies have found an association between delayed treatment of breast cancer and the patient's age<sup>10</sup>, advanced stage<sup>10-12</sup>, tumor size<sup>13</sup> and axillary lymph node involvement<sup>14</sup>. Some of these showed greater delay associated with being black, low educational level, low socioeconomic level and living far away from the treatment location<sup>15</sup>.

A study carried out in the United States with women with low incomes showed that one in ten waited for 60 days or more to start treatment after the diagnosis, a time interval associated with a decrease in overall survival of 66% and breast cancer in 85% among patients with advanced stage<sup>16</sup>. Another study evaluated the impact that curative surgery has on survival and concluded that in relation to breast cancer, intervals longer than 12 weeks

are associated with increased mortality<sup>17</sup>. However, studies that analyzed only some stages of the journey between the diagnosis and the treatment of breast cancer did not find a relation between the delay with poor prognosis or survival<sup>18,19</sup>.

The objective of the present study was to describe the possible stages of delay for patients with breast cancer diagnosis within the oncology department of a public hospital in the state of Pernambuco, in addition to evaluating the possible association of delay at the beginning of treatment with factors such as staging and patient survival.

## METHODS

This is a cross-sectional retrospective study with women with breast cancer diagnosed and treated at Instituto Materno Infantil Prof. Fernando Figueira (IMIP), located in the city of Recife, between January 2011 and December 2017.

The patient's medical charts were reviewed and the following variables were analyzed: age, origin, histological subtype, family history of cancer, gestations, smoking, consultation dates, examinations, treatments, type of diagnosis, staging (TNM), type of surgical treatment and need for neoadjuvant and / or adjuvant treatment, in addition to the clinical situation at the end of the study.

All patients with suspected primary breast cancer and who later received a positive diagnosis in the IMIP, having undergone complete treatment within the institution, were initially included in the study. Exclusion criteria were: patients with previous diagnosis of breast cancer who were referred to IMIP for treatment and follow-up, ductal carcinoma in situ and patients with other cancers.

The indication of a quadrantectomy or mastectomy was dependent on the assessment of the institution's mastologist surgeon. Simple mastectomy was characterized by the removal of the entire mammary gland, while in a radical mastectomy, it was associated with axillary lymphadenectomy. In general, locally advanced tumors underwent previous chemotherapy (neoadjuvant chemotherapy) before surgery.

Adjuvant (post-surgery) treatment, with radiotherapy and / or chemotherapy, was dependent on the presence of adverse prognostic factors.

Patient follow-up included consultations and regular examinations every three months in the first two years, every six months in the two subsequent years, and annually from the fifth year. At the end of the follow-up, the patients were classified as living without disease, living with disease, dead due to other causes and dead due to disease.

Two intervals were used to evaluate the treatment time of patient care: the first between the date of the first consultation at IMIP and the histopathological diagnosis, called the biopsy interval; and the second between the biopsy and the start of treatment (with surgery or neoadjuvant chemotherapy), called the treatment interval.



The values obtained by the study of each quantitative variable were organized and described in table form with their respective absolute and relative frequencies. Statistical Package for Social Sciences (SPSS) 13.0 for Windows and Excel 2016 were used for the statistical analysis. To verify the existence of association between categorical variables, the  $\chi^2$  test and the Fisher exact test were used. A 95% confidence index (95% CI) was applied to all tests.

The research was approved by the Ethics Committee on Research with Human Beings of the IMIP (CEP-IMIP) (CAAE: 70726017.9.0000.5201), and followed the norms established by Resolution No. 466/2012 of the National Health Council (CNS).

The Informed Consent Form was dismissed considering that the studied patients were no longer receiving treatment in the institution as well as the spaced out follow-up intervals which made contact extremely difficult.

## RESULTS

A total of 173 patients were analyzed. The age ranged from 21 to 87 years (mean:  $56.36 \pm 12.28$  years). One hundred and sixteen (67.1%) patients were from the metropolitan area of Recife, while 52 (30.1%) were from the interior of the state. In relation to the schooling level, 15 (8.7%) women were illiterate; 75 (43.4%) had up to 8 years of schooling and 71 (41%), more than 8 years of schooling. The mean number of gestations was  $3.19 \pm 3.04$ . At the start of the study, 75 (43.3%) women had not yet entered menopause. This sociodemographic data are presented in Table 1.

Considering the 155 cases in which information can be retrieved, the majority of women (81; 46.8%) had no family history of breast cancer. In the first evaluation, 19 (11%) women had stage I; 61 (35.3%), stage II; 49 (28.3%), stage III; and 10 (5.8%), stage IV. There was no information on the initial staging in the 34 patient medical records (19.6%).

The main complaints were: breast lumps (91 cases, 52.6%), breast pain (24 cases, 13.9%), skin alterations (17 cases, 9.8%), bulging (6 cases; 3.5%) and abscesses (1 case, 0.6%). Forty-five patients (26%) found the change by routine examination (USG and / or mammography), of which 20 (44.4%) presented BIRADS 4 on mammography, and 6 (13.3%), BIRADS 5.

The most frequent histological type was infiltrating ductal carcinoma, diagnosed in 148 cases (85.5%). The mean tumor size was  $4.3 \pm 2.86$  cm. The main surgical treatment was radical mastectomy, performed in 97 patients (56.1%), followed by quadrantectomy (31 cases, 17.9%) and simple mastectomy (15 cases, 8.7%). Neoadjuvant chemotherapy was used in 46.2% of cases. The aforementioned clinical data are presented in Table 2.

At the end of the study, 110 (63.6%) patients were alive without disease; 28 (16.2%), alive with disease; 2 (1.2%) died from other causes; and 14 (8.1%); from cancer. It was not possible to obtain this information in 19 medical records.

The biopsy interval (time between the first visit and the histopathological diagnosis) ranged from 0 to 826 days (41.42; med 12.50), while the treatment interval (time between histopathological diagnosis and treatment with surgery or chemotherapy) ranged from 0 to 460 days (94.6; med 69.0). There was no statistically significant association of these intervals with clinical variables such as origin, educational level, age, tumor staging, type of treatment and clinical status of patients at the end of the study (Tables 3 and 4).

**Table 1.** Sociodemographic characteristics of 173 patients with breast cancer. Recife, 2011-2017.

	n	%
Age (years)		
<50	49	28,3
≥50	124	71,7
Race		
White	20	11,6
Black	9	5,2
Brown	96	55,5
Information not given	48	27,7
Schooling level		
Illiterates	15	8,7
Up to 8 years	75	43,4
More than 8 years	61	35,3
Information not given	22	12,6
Smoke		
Yes	52	30,0
No	97	56,1
Information not given	24	13,9
Alcohol use		
Yes	32	18,5
No	116	67,0
Information not given	25	14,5
Breastfeed		
Yes	87	50,3
No	40	23,1
Information not given	46	26,6
Contraceptive use		
Yes	18	10,4
No	67	38,7
Information not given	88	50,9
Menopause		
<40 years	11	6,4
≥40 years	79	45,7
Information not given	8	4,6

## DISCUSSION

Aiming to evaluate possible delays in diagnosis and its correlation with clinical factors, the present study analyzed a total of 173 breast cancer patients diagnosed and treated at IMIP, an institution in Pernambuco that exclusively treats patients from the Unified Health System (SUS).

The study population presents comparable socio-demographic and clinical aspects to the majority of specialized researches in the literature. The patients had a mean age of 56 years, the majority self declared as brown and had an schooling level of up to

**Table 2.** Clinical characteristics of 173 patients with breast cancer. Recife, 2011-2017.

	n	%
<b>Histological type</b>		
IDC	148	85,5
Varied	8	4,7
Information not given	17	9,8
<b>Staging</b>		
Stage I	19	11,0
Stage II	61	35,3
Satge III	49	28,3
Stage IV	10	5,8
Information not given	34	19,6
<b>Type of surgery</b>		
Simple Mastectomy	15	8,7
Radical Mastectomy	97	56,1
Quadrantectomy	31	17,9
Information not given	30	17,3
<b>Neoadjuvance</b>		
CT	76	44,0
RT	8	4,6
CT + RT	4	2,3
None	76	43,9
Information not given	9	5,2
<b>Adjuvance</b>		
CT	38	22,0
RT	45	26,0
CT + RT	47	27,2
None	23	13,3
Information not given	20	11,5
<b>Differentiation grade</b>		
G1	24	13,9
G2	77	44,5
G3	47	27,2
Information not given	25	14,4

IDC: Invasive ductal carcinoma; CT: chemotherapy; RT: radiotherapy.

8 years (8% were illiterate). Regarding the level of schooling, the results are similar to other Brazilian studies, because the sample is predominantly composed of people attended by SUS. In a study by Barros et al.<sup>15</sup>, about 53% of the patients were illiterate or had attended school for up to four years.

The main complaint – breast nodule (53% of cases) - and the most common histological subtype - infiltrating ductal carcinoma (85.5% of cases) - are similar to those found in other specialized studies<sup>4,20</sup>. Considering 139 patients who had information on the initial staging, the majority - 110 women - were diagnosed with intermediate stages. Upon analyzing 73 patients in the state of São Paulo, Trufelli et al.<sup>4</sup> reported 17 cases of stage I, 28 cases of stage II, 17 case of stage III and 4 cases of stage IV. In a study by Angeles Llerenas et al.<sup>20</sup>, in a Mexican multi-institutional analysis with 854 patients, this distribution was also similar: 88 cases of stage I, 324 cases of stage II, 342 cases of stage III and 62 cases of stage IV.

The most frequent type of surgery in our patients was radical mastectomy (56% of cases) more than likely due to advanced staging. Seventy-six (44%) patients underwent neoadjuvant chemotherapy, reinforcing the late diagnosis in this group of patients. Two other Brazilian studies report neoadjuvant chemotherapy in less than 30% of cases<sup>4,15</sup>.

Delay in the diagnosis and treatment of breast cancer is discussed in the literature as having a negative impact on the prognosis of these patients. In a meta-analysis, Richard et al.<sup>8</sup> concluded that the delay in the treatment of breast cancer is associated with more advanced stages and worse survival. On the other hand, in a retrospective analysis that included 36,222 patients, through the Yorkshire Cancer Registry (England), Sainsbury et al.<sup>5</sup>, concluded that there was no evidence that treatment delay negatively affected the survival of these women. The fact is that it is difficult to exclude the influence of many other variables, such as tumor aggressiveness, genetic mutations and real onset of symptoms, with the final outcome and evolution of these patients.

Any lesion suspected of breast cancer should be investigated as early as possible, however many detected cancers appear to have existed for a long time in certain individuals, suggesting a less aggressive phenotype or a long tumor duplication, as discussed in the study by Sainsbury et al. al.<sup>5</sup>. On the other hand, some more aggressive cancers metastasize early. In both cases, a slightly earlier detection may not decisively influence overall survival, justifying conflicting literature data.

The analysis of the delay in the diagnosis and treatment of breast cancer is always performed by retrospective studies,<sup>4,20</sup> similar to the present investigation, or by systematic reviews<sup>8</sup>. The ethical impediment for prospective studies is obvious for the subject, since it is not possible to randomize groups and wait for a malignant cancer to evolve.

Another much debated issue in the literature is the time interval analyzed by the various authors. The time between the

detection of symptoms and the first consultation - related to patient problems - or the time between the first consultation and the beginning of treatment - related to problems of the medical service - are the most evaluated intervals. In Brazil, as of 2013, it was determined by the Ministry of Health that all patients with malignant cancer should start treatment within 60 days of diagnosis<sup>21</sup>.

The determination of the time between the first symptoms and the diagnosis is susceptible to many interpretation errors. Patients do not remember the onset of symptoms clearly, and confuse the symptoms with those of other diseases.

In studies that evaluate the delay in relation to the time interval from the first symptoms, a high median, often from 7 to 9 months, is almost always observed<sup>15</sup>. An exception is a study by the US National Cancer Institute, finding that approximately 40% of women report a 4-week delay in breast cancer diagnosis from the earliest symptoms; and that about 25% complain of an 8-week delay<sup>22</sup>.

In this study, the biopsy - time interval between the first consultation and the histopathological diagnosis - was an average of 41 days, while the treatment - time interval between the histopathological diagnosis and the actual treatment - was 95 days on average (approximately three months).

Upon evaluating 250 cases, Barros et al.<sup>15</sup> reported that most of their patients started treatment after 90 days of the first consultation. Another Brazilian study<sup>23</sup>, carried out in Vale do Cariri, Ceará, compares this waiting time to start treatment between private and public institutions. The mean time was significantly lower in the private institution (39 days) than in the public institution (71.5 days) ( $p = 0.031$ ). In a Mexican study<sup>20</sup>, the mean treatment interval was 37 days.

The biopsy and treatment intervals of this study were separated in two periods: less than or equal to 60 days and greater than 60 days. We did not observe a statistically significant association between these intervals or variables such as age, educational level, tumor staging, type of treatment and clinical status

**Table 3.** Association between the biopsy interval and the clinical variables of patients with breast cancer. Recife, 2011-2017.

Variables	Time (days) between the first visit and the biopsy		
	≤60 days n (%)	>60 days n (%)	p
Origin			
RMR	89 (78,1)	25 (21,9)	1,000*
Interior	40 (78,4)	11 (21,6)	
Out of state	2 (100,0)	0 (0,0)	
Age(years)			
<50	39 (83,0)	8 (17,0)	0,412**
≥50	95 (77,2)	28 (22,8)	
Schooling			
Up to 8 years	56 (75,7)	18 (24,3)	0,270**
More than 8 years	59 (83,1)	12 (16,9)	
Staging			
I and II	61 (78,2)	17 (21,8)	0,973**
III and IV	46 (78,0)	13 (22,0)	
Treatment type			
Neoadjuvance	71 (83,5)	14 (16,5)	0,147**
Surgery or surgery + adjuvant	61 (74,4)	21 (25,6)	
Clinical situation at the end of the study			
Alive	81 (75,0)	27 (25,0)	0,205*
Alive with disease	23 (85,2)	4 (14,8)	
Dead due to disease	13 (92,9)	1 (7,1)	
Dead due to other causes	1 (50,0)	1 (50,0)	
Dead			
Yes	14 (87,5)	2 (12,5)	0,525*
No	104 (77,0)	31 (23,0)	

RMR: Metropolitan Region of Recife; \*Fisher exact test; \*\* $\chi^2$  test.

of the patients at the end of the study. These data are similar to those of another national author<sup>4</sup>, who also did not observe statistical association between the diagnostic-treatment interval with age, type of treatment or patient evolution.

However, in a study by Barros et al.<sup>15</sup>, there was a significant association between the level of schooling and the delay in diagnosis and / or treatment. Women with lower educational level had a significant delay in time between the first symptoms and diagnosis ( $p = 0.04$ ) and between diagnosis and treatment ( $p = 0.03$ ).

The association of low level of education with delayed treatment seems to be due to the lack of knowledge of these patients about the disease and the means of diagnosis. In addition, there is a tendency for these individuals to consider the disease as incurable.

Our patients over 50 years old or less than 50 years old had a similar distribution in relation to the delay in the biopsy interval ( $p = 0.616$ ). However, in the study by Sainsbury et al.<sup>5</sup>, it was observed that a high proportion of patients aged up to 50 years

had a diagnosis delay of 90 days or more (8% of cases), compared to older patients (3% had a delay). Similar results are presented in a Colombian study<sup>24</sup>. It is suggested that this difference may be related to a greater clinical suspicion of cancer in the elderly with consequent fast diagnosis.

The patients in this study were mostly in stages II and III at the first specialist consultation. The distribution of stages in relation to delays in diagnosis and treatment was similar and not significant (Tables 3 and 4). The results of the literature are also discordant. In a study by McLaughlin et al.<sup>25</sup>, the time interval between diagnosis and treatment did not affect survival in case with early stages, but it did affect survival in the more advanced stages, especially when the delay was longer than 60 days. Similar results are presented by Pineros et al.<sup>24</sup>.

The treatment interval of the patients analyzed in this study was the same among the 14 cases that evolved to death, and there was no significant association between the biopsy intervals and

**Table 4.** Association between the treatment interval and the clinical variables of patients with breast cancer. Recife, 2011-2017.

Variables	Time (days) between biopsy and general TTO		
	≤60 days n (%)	>60 days n (%)	p
Origin			
RMR	57 (49,1)	59 (50,9)	0,149*
Interior	18 (34,6)	34 (65,4)	
Out of state	1 (50,0)	1 (50,0)	
Age (years)			
<50	23 (46,9)	26 (53,1)	0,616**
≥50	53 (42,7)	71 (57,3)	
Schooling level			
Up to 8 years	33 (44,0)	42 (56,0)	0,764**
More than 8 years	33 (46,5)	38 (53,5)	
Staging			
I and II	30 (37,5)	50 (62,5)	0,704**
III and IV	24 (40,7)	35 (59,3)	
Treatment type			
Neoadjuvance	40 (45,5)	48 (54,5)	0,493**
Surgery or surgery + adjuvant	33 (40,2)	49 (59,8)	
Clinical situation at the end of the study			
Alive	41 (37,3)	69 (62,7)	0,122*
Alive with disease	15 (53,6)	13 (46,4)	
Dead due to disease	7 (50,0)	7 (50,0)	
Dead from other causes	2 (100,0)	0 (0,0)	
Dead			
Yes	9 (56,2)	7 (43,8)	0,230**
No	56 (40,6)	82 (59,4)	

TTO: treatment; RMR: Metropolitan Region of Recife; \*Fisher exact test; \*\* $\chi^2$  test.

the treatment intervals with the clinical evolution. What most likely interfered in this evolution was the stage in which they were in during the first specialist consultation (11 stages III and 3 stages IV).

We chose to separate the time intervals above and below 60 days, as this is the time recommended by the Brazilian government for cancer treatment to be started. Perhaps this relatively small delay is the reason that there was no significant association of the intervals with the variables mentioned above. In a review by Richards et al.<sup>8</sup> -an analysis of 87 studies with a total

of 101,954 patients - only delays of 3 to 6 months are associated with a 12% decrease in patient survival.

As a conclusion, we can infer the extreme importance of an early diagnosis of breast cancer with implication in the reduction of mortality, as demonstrated by several authors<sup>8,9,15,16</sup>. On the other hand, the mean time of three months between diagnosis and treatment did not interfere in the evolution of the patients in this investigation. There is a need to ratify this data by broadening the investigation with more cases and investigating other possible time intervals.

## REFERENCES

1. Instituto Nacional de Câncer (INCA). Estimativa 2016: incidência de câncer no Brasil. [Internet]. Rio de Janeiro: Instituto Nacional de Câncer; 2016 [acessado em 12 maio 2017]. Disponível em: <https://www.inca.gov.br/campanhas/dia-nacional-de-combate-ao-cancer/2015/estimativa-2016-incidencia-de-cancer-no-brasil>
2. Tfayli A, Temraz S, Abou Mrad R, Shamseddine A. Breast cancer in low- and middle-income countries: an emerging and challenging epidemic. *J Oncol*. 2010;2010:490631. <https://doi.org/10.1155/2010/490631>
3. Harford J, Azavedo E, Fischietto M. Guideline implementation for breast healthcare in low- and middle-income countries: breast healthcare program resource allocation. *Cancer*. 2008;113(8 Supl.):2282-96. <https://doi.org/10.1002/cncr.23841>
4. Trufelli DC, Miranda VC, Santos MBB, Fraile NMP, Pecoroni PG, Gonzaga SFR, et al. Análise do atraso no diagnóstico e tratamento do câncer de mama em um hospital público. *Rev Assoc Med Bras*. 2008;54(1):72-6. <http://dx.doi.org/10.1590/S0104-42302008000100024>
5. Sainsbury R, Johnston C, Haward B. Effect on survival of delays in referral of patients with breastcancer symptoms: a retrospective analysis. *Lancet*. 1999;353(9159):1132-5. [https://doi.org/10.1016/s0140-6736\(99\)02374-0](https://doi.org/10.1016/s0140-6736(99)02374-0)
6. Stiefel F. Understanding why women delay in seeking help for breast cancer symptoms. *J Psychosom Res*. 2006;60(3):309-10. <https://doi.org/10.1016/j.jpsychores.2006.01.005>
7. Ezeome ER. Delays in presentation and treatment of breast cancer in Enugu, Nigeria. *Niger J Clin Pract*. 2010;13(3):311-6.
8. Richards MA, Westcombe AM, Love SB, Littlejohns P, Ramirez AJ. Influence of delay on survival in patients with breast cancer: a systematic review. *Lancet*. 1999;353(9159):1119-26. [https://doi.org/10.1016/s0140-6736\(99\)02143-1](https://doi.org/10.1016/s0140-6736(99)02143-1)
9. Trufelli DC, Bensi CG, Pane CEV, Ramos E, Otsuda FC, Tannous NG, et al. Onde está o atraso? Avaliação do tempo necessário para o diagnóstico e tratamento do câncer de mama nos serviços de oncologia da Faculdade de Medicina do ABC. *Rev Bras Mastologia*. 2007;17(1):14-7.
10. Sharma K, Costas A, Shulman LN, Meara JG. A systematic review of barriers to breast cancer care in developing countries resulting in delayed patient presentation. *J Oncol*. 2012;2012:121873. <https://doi.org/10.1155/2012/121873>
11. Yau TK, Choi CW, Ng E, Yeung R, Soong IS, Lee AW. Delayed presentation of symptomatic breast cancers in Hong Kong: experience in a public cancer centre. *Hong Kong Med J*. 2010;16(5):373-7.
12. Ukwanya AY, Yusufu LM, Nmadu PT, Garba ES, Ahmed A. Delayed treatment of symptomatic breast cancer: the experience from Kaduna, Nigeria. *S Afr J Surg*. 2008;46(4):106-10.
13. Brito C, Portela MC, Vasconcellos MT. Sobrevida de mulheres tratadas por câncer de mama no estado do Rio de Janeiro. *Rev Saúde Pública*. 2009;43(3):481-9. <http://dx.doi.org/10.1590/S0034-89102009000300012>
14. Ramirez AJ, Westcombe AM, Burgess CC, Sutton S, Littlejohns P, Richards MA. Factors predicting delayed presentation of symptomatic breast cancer: a systematic review. *Lancet*. 1999;353(9159):1127-31. [https://doi.org/10.1016/s0140-6736\(99\)02142-x](https://doi.org/10.1016/s0140-6736(99)02142-x)
15. Barros ÂF, Uemura G, Macedo JLS de. Tempo para acesso ao tratamento do câncer de mama no Distrito Federal, Brasil Central. *Rev Bras Ginecol Obstet*. 2013;35(10):458-63. <http://dx.doi.org/10.1590/S0100-72032013001000006>
16. McLaughlin JM, Anderson RT, Ferketich AK, Seiber EE, Balkrishnan R, Paskett ED. Effect on survival of longer intervals between confirmed diagnosis and treatment initiation among low-income women with breast cancer. *J Clin Oncol*. 2012;30(36):4493-500. <https://doi.org/10.1200/JCO.2012.39.7695>
17. Shin DW, Cho J, Kim SY, Guallar E, Hwang SS, Cho B, et al. Delay to curative surgery greater than 12 weeks is associated with increased mortality in patients with colorectal and breast cancer but not lung or thyroid cancer. *Ann Surg Oncol*. 2013;20(8):2468-76. <https://doi.org/10.1245/s10434-013-2957-y>



18. Olivotto IA, Borugian MJ, Kan L, Harris SR, Rousseau EJ, Thorne SE, et al. Improving the time to diagnosis after an abnormal screening mammogram. *Can J Public Health*. 2001;92(5):366-71.
19. Masood S. Coming together to conquer the fight against breast cancer in countries of limited resources: the challenges and the opportunities. *Breast J*. 2007;13(3):223-5. <https://doi.org/10.1111/j.1524-4741.2007.00413.x>
20. Ángeles-Llerenas A, Torres-Mejía G, Lazcano-Ponce E, Uscanga-Sánchez S, Mainero-Ratchelous F, Hernández-Ávila JE, et al. Effect of care-delivery delay on the survival of Mexican women with breast cancer. *Salud Publica Mex*. 2016;58(2):237-50.
21. Brasil. Ministério da Saúde. Secretaria de Atenção à Saúde. [Internet]. 2013 [acessado em 17 maio 2017]. Disponível em: <http://bvsm.s.saude.gov.br/sus/publicacoes/controler-canceres-colo-utero2013.pdf>.
22. Coplan LS, Helzlsouer KJ, Shapiro S, Wesley MN, Edwards BK. Reasons for delay in breast cancer diagnosis. *Prev Med* 1996;25(2):218-24.
23. Ferreira NAS, Carvalho SMF, Valenti VE, Bezerra IMP, Batista HMT, Abreu LC, et al. Treatment delays among women with breast cancer in a low socio-economic status region in Brazil. *BMC Womens Health*. 2017;17(1):13.
24. Piñeros M, Sánchez R, Cendales R, Perry F, Ocampo R. Patient delay among Colombian women with breast cancer. *Salud Publica Mex*. 2009;51(5):372-80.
25. McLaughlin JM, Anderson RT, Ferketich AK, Seiber EE, Balkrishnan R, Paskett ED. Effect on survival of longer intervals between confirmed diagnosis and treatment initiation among low-income women with breast cancer. *J Clin Oncol*. 2012;30(36):4493-500.







#### Attachment 1. Data collection instrument.

Name: \_\_\_\_\_ Registration: \_\_\_\_\_  
 Origin: 1 ( ) RMR 2 ( ) State interior 3 ( ) Outside of state  
 Age: \_\_\_\_\_  
 Race: 1 ( ) white 2 ( ) black 3 ( ) brown Occupation: \_\_\_\_\_  
 Educational level: \_\_\_\_\_  
 ( ) Illiterate ; ( ) 1–2 years; ( ) 3–4 years; ( ) 5–6 years; ( ) 7–8 years; ( ) 9–12 years; ( ) More than 12 years;  
 Smoke: 1 ( ) Yes 2 ( ) No  
 Drink alcohol: 1 ( ) Yes 2 ( ) No  
 Age of menarche: \_\_\_\_\_ Age of menopause: \_\_\_\_\_  
 Parity: \_\_\_\_\_ Breastfeed: 1 ( ) Yes 2 ( ) No  
 Contraceptive use: 1 ( ) Yes 2 ( ) No  
 Family history: 1 ( ) Yes 2 ( ) No  
 History of benign breast disease 1 ( ) Yes 2 ( ) No  
 History of other neoplasms: 1 ( ) Yes 2 ( ) No  
 Date of last mammography: \_\_\_\_\_  
 Date of last clinical breast examination: \_\_\_\_\_  
 Reason for making doctor appointment:  
 1 ( ) Routine appointment  
 2 ( ) symptom (palpable nodule, retraction, hyperemia, bulging, abscess, breast pain, abscess, changes in the skin of the breast and axilla)  
 Date of first medical appointment: \_\_\_\_\_  
 Date of mammography request: \_\_\_\_\_ Date of mammography result: \_\_\_\_\_  
 Outcome / Result of mammography : BIRADS: \_\_\_\_\_ Size of nodule: \_\_\_\_\_ Compromised lymph nodes: 1 ( ) Yes 2 ( ) No  
 Date of request for breast ultrasound: \_\_\_\_\_ Date of breast ultrasound result: \_\_\_\_\_  
 Outcome / Results of breast ultrasound : BIRADS: \_\_\_\_\_ Size of nodule: \_\_\_\_\_ Compromised lymph nodes: 1 ( ) Yes 2 ( ) No  
 Date of biopsy: \_\_\_\_\_ Date of biopsy result: \_\_\_\_\_  
 Histopathological biopsy result: \_\_\_\_\_  
 Did you have any examination in the private service? 1 ( ) yes 1.1 ( ) What? \_\_\_\_\_ 2 ( ) No  
 Neoadjuvant treatment: 1 ( ) Yes 1.1 Start date: \_\_\_\_\_ 2 ( ) No  
 Date of surgery: \_\_\_\_\_  
 Type of surgery: 1 ( ) Radical mastectomy 2 ( ) Modified radical mastectomy 3 ( ) Simple mastectomy 4 ( ) Quadrantectomy  
 5 ( ) Setorectomy 6 ( ) Sentinel lymph node  
 Clinical Tumor Staging: \_\_\_\_\_  
 Tumor size(cm): \_\_\_\_\_ Histological type: \_\_\_\_\_  
 Histological stage: ( ) I ( ) II ( ) III  
 Did you do immunohistochemistry? 1 ( ) Yes 2 ( ) No  
 Immunohistochemistry result: \_\_\_\_\_  
 Chemotherapy: 1 ( ) Yes 1.1 Start date: \_\_\_\_\_ 2 ( ) No  
 Radiotherapy: 1 ( ) Yes 1.1 Start date: \_\_\_\_\_ 2 ( ) No  
 Hormone Therapy: 1 ( ) Yes 1.1 Start date: \_\_\_\_\_ 2 ( ) No  
 Clinical situation at the end of the study: 1 ( ) alive 2 ( ) alive with disease 3 ( ) death due to illness 4 ( ) death from other causes

RMR: Metropolitan Region of Recife.

# IMAGING FINDINGS OF ABSORBABLE VICRYL MESH IMPLANTED AFTER LUMPECTOMY

Achados de imagem de tela absorvível de Vicryl implantada após cirurgia conservadora

Almir Galvão Vieira Bitencourt<sup>1\*</sup> , Marília Mendes de Azevedo<sup>1</sup> , Vinicius Cardona Felipe<sup>1</sup> , Juliana Alves de Souza<sup>1</sup> , Mauricio Doi<sup>2</sup> , Hugo Fontan Kohler<sup>3</sup> 

## ABSTRACT

The Vicryl mesh implantation after lumpectomy, which was first proposed in 2003, is a simple technique, less expensive than other proposed implantable biomaterials. However, the postoperative follow-up may be difficult, since the implanted mesh impairs the evaluation of surrounding breast parenchyma at both mammography and ultrasound. Magnetic resonance imaging can be used as a problem-solving tool if there are equivocal findings at physical exam, mammography, or ultrasound. Nevertheless, there are only few reports in literature about the imaging aspects of implanted absorbable mesh in the breast. The images presented in this case show the typical presentation of a foreign body granuloma associated with the Vicryl mesh. Breast radiologists and surgeons should be aware of these imaging aspects to avoid misdiagnosis and unnecessary additional exams.

**KEYWORDS:** mammography; ultrasonography; magnetic resonance imaging; postoperative care; surgical mesh.

## RESUMO

A implantação da tela de Vicryl após quadrantectomia, proposta pela primeira vez em 2003, é uma técnica simples, sendo menos dispendiosa do que outros biomateriais implantáveis. Entretanto, o acompanhamento pós-operatório pode ser difícil, uma vez que a tela implantada compromete a avaliação do parênquima mamário adjacente, tanto na mamografia quanto na ultrassonografia. A ressonância magnética pode ser utilizada se houver achados duvidosos no exame físico, na mamografia ou na ultrassonografia. No entanto, existem poucos relatos na literatura sobre os aspectos de imagem da tela absorvível implantada na mama. As imagens apresentadas neste caso mostram a apresentação típica de um granuloma de corpo estranho associado à tela de Vicryl. Radiologistas e cirurgiões devem estar cientes desses aspectos de imagem para evitar diagnósticos incorretos e exames adicionais desnecessários.

**PALAVRAS-CHAVE:** mamografia; ultrassonografia; imagem por ressonância magnética; cuidados pós-operatórios; telas cirúrgicas.

<sup>1</sup>Imaging Department, A. C. Camargo Cancer Center – São Paulo (SP), Brazil.

<sup>2</sup>Mastology Department, A. C. Camargo Cancer Center – São Paulo (SP), Brazil.

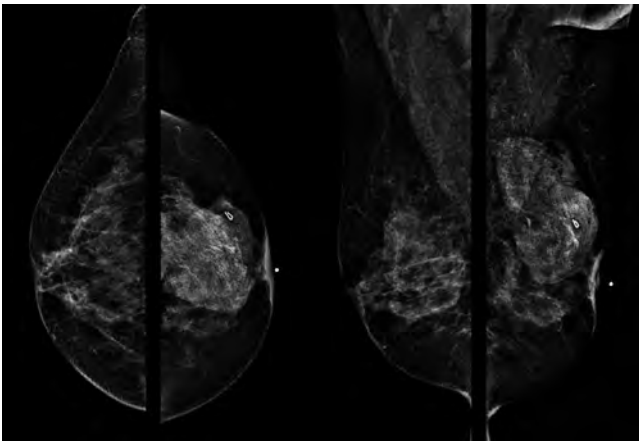
<sup>3</sup>Head and Neck Department, A. C. Camargo Cancer Center – São Paulo (SP), Brazil.

\*Corresponding author: almir.bitencourt@accamargo.org.br

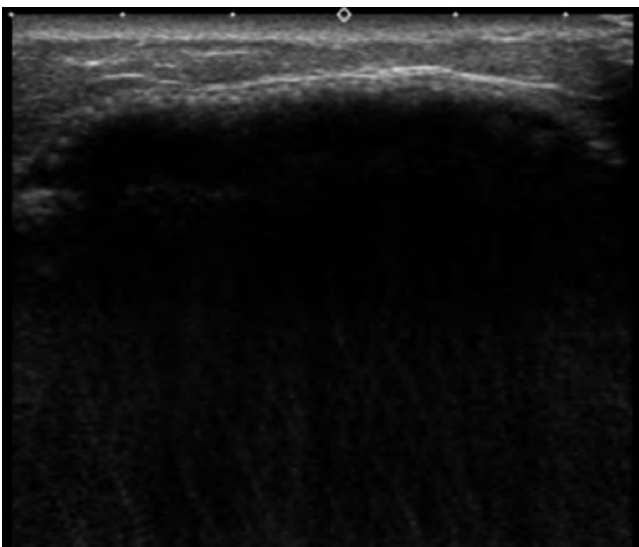
Conflict of interests: nothing to declare.

Received on: 11/27/2018. Accepted on: 12/27/2018

A 64-year-old female patient, who performed left breast conservative surgery five years ago for a tubular carcinoma (T1miN0M0), complained of left breast lump near the surgical scar. At surgery, an absorbable polyglactin 910 (Vicryl) mesh was inserted to fill the surgical defect and improve cosmetic outcome. Mammography showed focal asymmetry in the upper quadrants of the left breast with a surgical clip inside it (Figure 1). Ultrasound presented a linear hyperechoic image with intense posterior acoustic shadowing (Figure 2). Breast magnetic resonance imaging (MRI) showed a well-encapsulated cystic mass with thin walls and content with low signal at T1-weighted images and heterogenous high signal



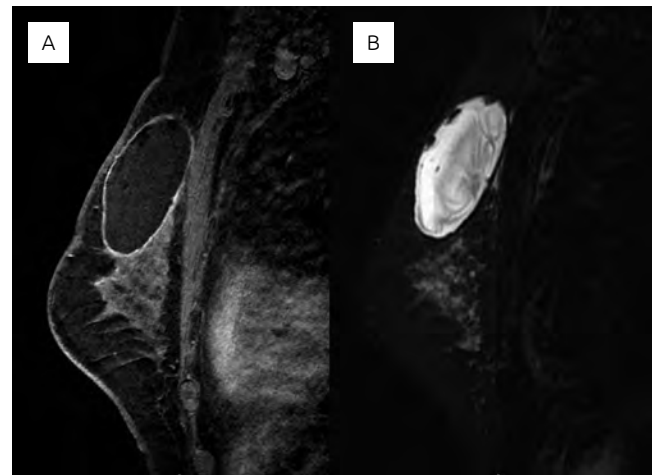**Figure 1.** Mammography (craniocaudal and mediolateral oblique views) shows signs of previous left breast surgery, with a metallic surgical clip and a focal asymmetry at the left breast upper quadrants.



**Figure 2.** Ultrasound shows a linear hyperechoic image with intense posterior acoustic shadowing at the left breast upper quadrants, which impair the evaluation of the underlying breast parenchyma.

on T2-weighted images, demonstrating linear hypointense images inside it (Figure 3). The imaging aspects are compatible with a foreign body granuloma associated with the Vicryl mesh. However, if there was no detailed information about the previous surgery, it could be misdiagnosed as a breast collection or intracapsular rupture implant. Although breast conserving surgery has been a standard surgical treatment for breast cancer, it results in breast deformity. Many surgical techniques have been used to improve the cosmetic outcome, such as tissue flaps, artificial implants, and mesh materials<sup>1</sup>.

Vicryl mesh is a synthetic and absorbable material that has been extensively used in many surgical specialties. Its implantation after lumpectomy, which was first proposed in 2003, is a simple technique, less expensive than other proposed implantable biomaterials<sup>2,3</sup>. Nevertheless, it may increase postoperative complications and not improve cosmetic outcomes<sup>4,6</sup>. In addition, the postoperative follow-up may be difficult since the implanted mesh impairs the evaluation of surrounding breast parenchyma at both mammography and ultrasound. MRI can be used as a problem-solving tool if there are equivocal findings at physical exam, mammography, or ultrasound. There are only few reports in literature about the imaging aspects of implanted absorbable mesh in the breast<sup>7-9</sup>. The images presented in this case show the typical presentation of foreign body granulomatous reaction, since the Vicryl mesh induces reactive fluid and granulation tissue formation. Breast radiologists and surgeons should be aware of these imaging aspects to avoid misdiagnosis and unnecessary additional exams.





**Figure 3.** Breast magnetic resonance imaging (MRI) shows a well-encapsulated cystic mass with thin walls and content with low signal at T1-weighted images (A) and heterogenous high signal on T2-weighted images, presenting linear hypointense images inside it (B).

## REFERENCES

1. Churgin S, Isakov R, Yetman R. Reconstruction options following breast conservation therapy. *Cleve Clin J Med*. 2008;75(Suppl. 1):S24-9.
2. Sanuki J, Fukuma E, Wadamori K, Higa K, Sakamoto N, Tsunoda Y. Volume replacement with polyglycolic acid mesh for correcting breast deformity after endoscopic conservative surgery. *Clin Breast Cancer*. 2005;6(2):175.
3. Tessler O, Reish RG, Maman DY, Smith BL, Austen WG Jr. Beyond biologics: absorbable mesh as a low-cost, low-complication sling for implant-based breast reconstruction. *Plast Reconstr Surg*. 2014;133(2):90e-9e. <https://doi.org/10.1097/01.prs.0000437253.55457.63>
4. Tsuji W, Yotsumoto F. Pros and cons of immediate Vicryl mesh insertion after lumpectomy. *Asian J Surg*. 2018;41(6):537-42. <https://doi.org/10.1016/j.asjsur.2017.08.001>
5. Lee A, Won Hwang H, Chang J, Lim W, Moon BI. Outcomes of breast conserving surgery with immediate vicryl-mesh insertion: is it safe and effective? *Breast J*. 2012;18(4):334-8. <https://doi.org/10.1111/j.1524-4741.2012.01247.x>
6. Koo MY, Lee SK, Hur SM, Bae SY, Choi MY, Cho DH, et al. Results from over one year of follow-up for absorbable mesh insertion in partial mastectomy. *Yonsei Med J*. 2011;52(5):803-8. <https://doi.org/10.3349/ymj.2011.52.5.803>
7. Góes JC, Landecker A, Lyra EC, Henriques LJ, Góes RS, Godoy PM. The application of mesh support in periareolar breast surgery: clinical and mammographic evaluation. *Aesthetic Plast Surg*. 2004;28(5):268-74. <https://doi.org/10.1007/s00266-004-3099-1>
8. Choi Y, Hong HP, Kwag HJ. Ultrasonographic findings of an implanted absorbable mesh in patients with breast partial resection: a preliminary study. *J Korean Soc Ultrasound Med*. 2007;26(2):89-94.
9. Kwag HJ. Imaging findings of implanted absorbable mesh in patients with breast partial resection. *Yonsei Med J*. 2008;49(1):111-8. <https://doi.org/10.3349/ymj.2008.49.1.111>

# 18F-FDG PET/CT HELPS TO FIND OCCULT CARCINOMA IN A PATIENT WITH MULTIPLE BREAST MASSES AT MAGNETIC RESONANCE IMAGING

PET/CT com 18F-FDG ajuda a identificar carcinoma oculto em paciente com múltiplos nódulos mamários na ressonância magnética

Almir Galvão Vieira Bitencourt<sup>1\*</sup> , Luciana Graziano<sup>1</sup> , Carla Tajima<sup>1</sup> ,  
Fabiana Baroni Makdissi<sup>1</sup> , Eduardo Nóbrega Pereira Lima<sup>1</sup> 

## ABSTRACT

52-year-old female patient with diagnosis of invasive carcinoma in the left breast and metastatic lymph node in the right axilla. Magnetic resonance imaging showed multiple breast masses, with four previous negative biopsies in the right breast. 18F-FDG positron emission tomography (PET)/computed tomography (CT) was performed in prone position, dedicated to breast evaluation. It showed increased uptake in a mass in the right breast. After PET/magnetic resonance imaging (MRI) fusion and second-look breast ultrasound, this mass was submitted to percutaneous biopsy, which confirmed a second invasive breast carcinoma and changed patients' treatment. This is an example of how PET/MRI dedicated devices can improve the evaluation of selected breast lesions.

**KEYWORDS:** positron-emission tomography; fluorodeoxyglucose F18; magnetic resonance imaging; breast neoplasms.

## RESUMO

Paciente do sexo feminino, de 52 anos, com diagnóstico de carcinoma invasivo na mama esquerda e linfonodo metastático na axila direita. A ressonância magnética mostrou múltiplos nódulos mamários bilaterais, com quatro biópsias anteriores negativas na mama direita. 18F-FDG PET/tomografia computadorizada (CT) foi realizado em decúbito ventral, dedicada à avaliação das mamas, demonstrou aumento da captação em um nódulo na mama direita. Depois de fusão das imagens do PET/CT com a ressonância magnética (RM) e ultrassonografia direcionada, esta lesão foi submetida à biópsia percutânea, que confirmou um segundo carcinoma invasivo na mama direita, alterando o tratamento. Este é um exemplo de como os dispositivos dedicados de PET/RM podem melhorar a avaliação das lesões mamárias selecionadas.

**PALAVRAS-CHAVE:** tomografia por emissão de pósitrons; fluordesoxiglicose F18; imagem por ressonância magnética; neoplasias da mama.

<sup>1</sup>A.C. Camargo Cancer Center – São Paulo (SP), Brazil.

\*Corresponding author: almir.bitencourt@accamargo.org.br

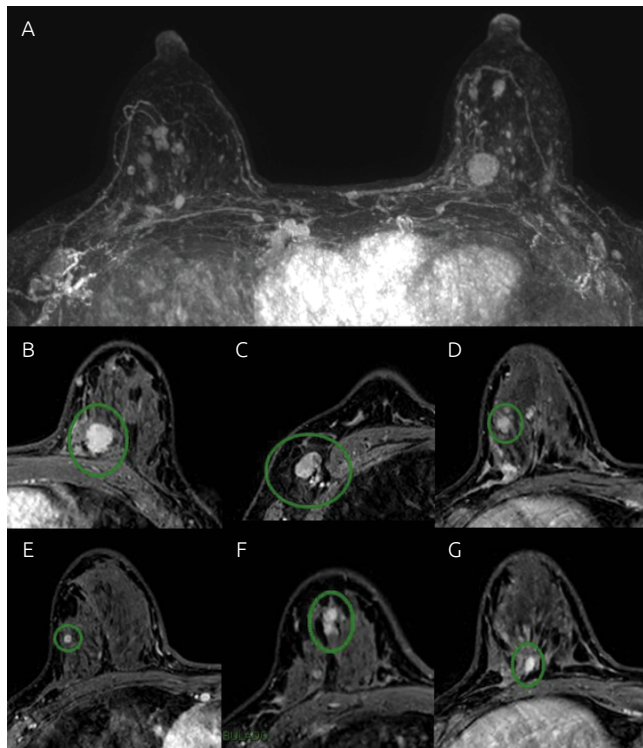
Conflict of interests: none.

Received on: 01/03/2019. Accepted on: 01/24/2019.

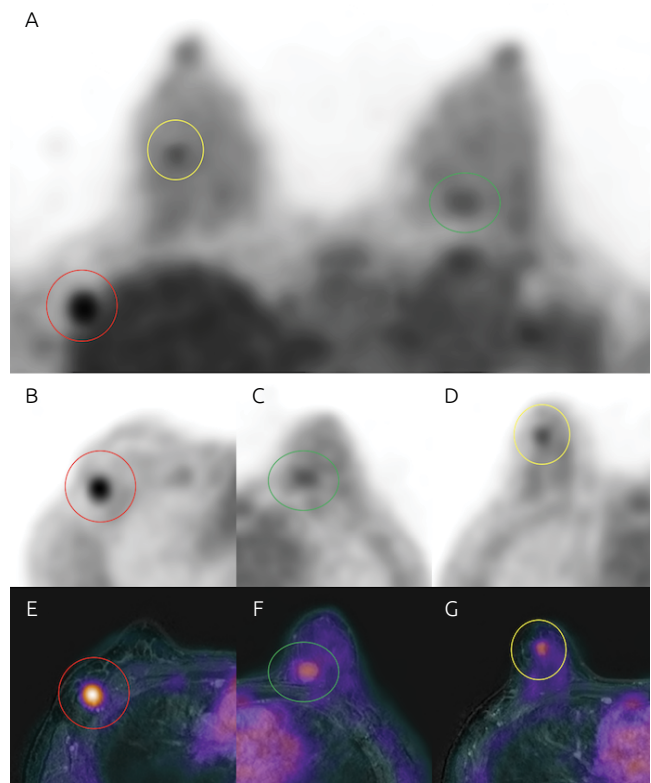


A 52-year-old female patient presented with a diagnosis of invasive carcinoma in the left breast and metastatic lymph node in the right axilla. Breast magnetic resonance imaging (MRI) showed multiple breast masses (Figure 1), with four previous negative biopsies in the right breast. The 18F-FDG positron emission tomography (PET)/computed tomography (CT) was performed in prone position (Figure 2), dedicated to breast evaluation. It showed increased uptake on the lymph node in the right axilla (standard uptake value (SUV): 4.9) in the left breast carcinoma (SUV: 1.9) and in a mass in the right breast upper outer quadrant (SUV:1.8). After PET/MRI fusion (Figure 2) and second-look breast ultrasound (Figure 3), the right breast mass was identified and submitted to percutaneous biopsy, which confirmed a second invasive breast carcinoma.

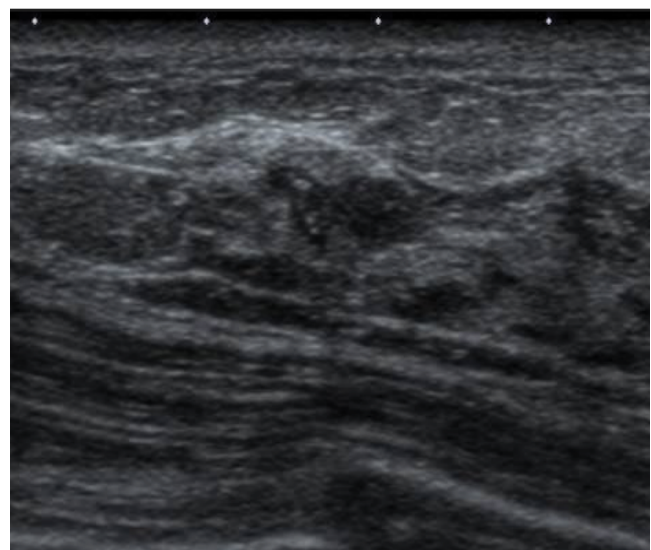
PET-CT has a proven role in the staging and treatment evaluation of patients with metastatic breast cancer<sup>1,2</sup>. However, its role in the assessment of primary breast lesions is still controversial, because both benign and malignant conditions may show glucose hypermetabolism<sup>3</sup>. Prone 18F-FDG PET/CT has a high specificity for the diagnosis of invasive breast carcinomas and allows fusion with breast MR images, which can improve



**Figure 1.** Breast magnetic resonance imaging. (A) 3D maximum intensity projection (MIP) axial reconstruction of a post-contrast subtracted sequence shows multiple breast masses in both breasts. (B) Detail of the known malignant breast carcinoma in the left breast. (C) Detail of the metastatic lymph nodes in the right axilla. (D-G) Detail of the largest masses in the right breast.



**Figure 2.** Prone 18F-FDG positron emission tomography (PET) and PET/magnetic resonance imaging (MRI) fusion. (A) 3D axial reconstruction of PET images shows increased uptake on the lymph node in the right axilla (red circle), in the left breast carcinoma (green circle), and in a mass in the right breast upper outer quadrant (yellow circle). (B-D) Detail of the hypermetabolic areas on PET images. (E-G) PET-MRI fusion images.



**Figure 3.** Second-look ultrasound shows an irregular hypoechoic mass in the right breast upper outer quadrant, which corresponds to the hypermetabolic mass found at the PET/computed tomography.

evaluation of indeterminate breast lesions found on the MRI, especially for mass lesions with a diameter larger than 10 mm<sup>4-8</sup>. This method can be used for helping to choose what lesion to biopsied when there are multiple breast lesions and high suspicion of malignancy. Because low-grade and small breast carcinomas may have only mild increase in glucose metabolism, any area of increased 18F-FDG uptake in relation to the normal breast parenchyma should be considered suspicious<sup>6-8</sup>.





In the presented case, the right axilla lymph node was a left breast carcinoma metastasis, which would be considered as a distant metastasis for purposes of staging and management. However, PET/CT helped to find a second invasive carcinoma in the right breast, which changed patients' staging, prognosis, and treatment. This is an example of how PET/MRI dedicated devices can improve the evaluation of breast lesions in the selected cases.

## REFERENCES

1. Groheux D, Cochet A, Humbert O, Alberini JL, Hindié E, Mankoff D. <sup>18</sup>F-FDG PET/CT for Staging and Restaging of Breast Cancer. *J Nucl Med*. 2016;57(Suppl. 1):17S-26S. <https://doi.org/10.2967/jnumed.115.157859>
2. Garcia JR, Pérez C, Bassa P, Capdevilla L, Ramos F, Valenti V. 18F-FDG PET/CT in the Staging and Management of Breast Cancer: Value in Disease Outcome and Planning Therapy. *Clin Nucl Med*. 2017;42(3):191-2. <https://doi.org/10.1097/RLU.0000000000001512>
3. Dong A, Wang Y, Lu J, Zuo C. Spectrum of the Breast Lesions With Increased 18F-FDG Uptake on PET/CT. *Clin Nucl Med*. 2016;41(7):543-57. <https://doi.org/10.1097/RLU.0000000000001203>
4. Moy L, Ponzo F, Noz ME, Maguire GQ Jr., Murphy-Walcott AD, Deans AE, et al. Improving specificity of breast MRI using prone PET and fused MRI and PET 3D volume datasets. *J Nucl Med*. 2007;48(4):528-37.
5. Garcia-Velloso MJ, Ribelles MJ, Rodriguez M, Fernandez-Montero A, Sancho L, Prieto E, et al. MRI fused with prone FDG PET/CT improves the primary tumour staging of patients with breast cancer. *Eur Radiol*. 2017;27(8):3190-8. <https://doi.org/10.1007/s00330-016-4685-8>
6. Magometschnigg HF, Baltzer PA, Fueger B, Helbich TH, Karanikas G, Dubsy P, et al. Diagnostic accuracy of (18)F-FDG PET/CT compared with that of contrast-enhanced MRI of the breast at 3 T. *Eur J Nucl Med Mol Imaging*. 2015;42(11):1656-65. <https://doi.org/10.1007/s00259-015-3099-1>
7. Bitencourt AG, Lima EN, Chojniak R, Marques EF, Souza JA, Andrade WP, et al. Can 18F-FDG PET improve the evaluation of suspicious breast lesions on MRI? *Eur J Radiol*. 2014;83(8):1381-6. <https://doi.org/10.1016/j.ejrad.2014.05.021>
8. Moy L, Noz ME, Maguire GQ Jr., Melsaether A, Deans AE, Murphy-Walcott AD, et al. Role of fusion of prone FDG-PET and magnetic resonance imaging of the breasts in the evaluation of breast cancer. *Breast J*. 2010;16(4):369-76. <https://doi.org/10.1111/j.1524-4741.2010.00927.x>

# TRANSFORMATION OF FIBROADENOMA TO PHYLLODES TUMOR AND THE USE OF ONCOPLASTIC TECHNIQUE FOR BREAST CONSERVATIVE TREATMENT

A transformação do fibroadenoma em tumor filóides e o uso de técnicas oncoplásticas no tratamento cirúrgico conservador de mama

Julia Dias do Prado<sup>1\*</sup> , Roberto José da Silva Vieira<sup>2</sup> , Waldyr Gomes da Costa Neto<sup>3</sup> ,  
Linda Lorena Gonzalez de Castro<sup>4</sup> , Bruno Bohrer Flores<sup>5</sup> , Lea Pikelhaizen Velloso<sup>4</sup> 

## ABSTRACT

Phyllodes tumors (PT) are rare neoplasms accounting for <1% of breast lesions. A transformation of a fibroadenoma (FA) to a PT is even more rare and unpredictable. Many challenges face PT management, since diagnostic through surgical treatment. We describe a case of a 63-year old woman with PT that was previously diagnosed as a FA who underwent an oncoplastic conservative surgery. A review of the literature on the diagnostic and surgical management of PT was performed. The diagnostic of PT can be hard mostly in needle biopsy, and the close follow up of negative lesions is recommended. Oncoplastic techniques might be an important tool on the conservative treatment of these patients.

**KEYWORDS:** phyllodes tumor; diagnostic; fibroadenoma; oncoplastic technique; breast conservative surgery.

## RESUMO

O tumor filoide (TF) é uma rara neoplasia que corresponde a menos de 1% das lesões mamárias. A transformação do fibroadenoma (FA) em TF é um evento raro e imprevisível. Existem muitos desafios no manejo dos TF, desde o seu diagnóstico ao tratamento. Nós descrevemos o caso de uma paciente de 63 anos com TF com diagnóstico prévio de FA que foi submetida ao tratamento cirúrgico conservador da mama por técnicas oncoplásticas. Uma revisão da literatura sobre o diagnóstico e tratamento do TF foi realizada. O diagnóstico dessa condição pode ser especialmente difícil quando feito a partir de amostra de biópsias por agulha, e em caso de resultados negativos recomenda-se acompanhamento rigoroso. As técnicas oncoplásticas podem ser uma importante ferramenta no tratamento cirúrgico conservador desses pacientes.

**PALAVRAS-CHAVE:** tumor filoide; diagnóstico; fibroadenoma; técnica oncoplástica; cirurgia conservadora da mama.

Study carried out at private practice of Dr. Roberto José da Silva Vieira.

<sup>1</sup>Hospital Universitário Antônio Pedro, Hospital Universitário Gaffrée e Guinle – Rio de Janeiro (RJ), Brazil.

<sup>2</sup>Fundação Oswaldo Cruz, Pontifícia Universidade Católica do Rio de Janeiro – Rio de Janeiro (RJ), Brazil.

<sup>3</sup>Hospital Quinta D'Or – Rio de Janeiro (RJ), Brazil.

<sup>4</sup>Pontifícia Universidade Católica do Rio de Janeiro – Rio de Janeiro (RJ), Brazil.

<sup>5</sup>Universidade Luterana do Brasil – Canoas (RS), Brazil.

\*Corresponding author: juliardias@gmail.com

Conflict of interests: nothing to declare.

Received on: 11/05/2018. Accepted on: 12/27/2018

## INTRODUCTION

Both fibroadenomas (FA) and phyllodes tumors (PT) belong to a heterogeneous group of biphasic fibroepithelial breast lesions with stromal and epithelial components that demonstrate wide ranging biological behavior with differences in clinical management. FA are common tumors, and the increasing use of core biopsy rather than excision to diagnose these lesions has become common place to follow them with imaging. A transformation of a FA to a PT is rare and unpredictable. Sanders and Sara found an incidence of 2.4% of PT on a group of 2,062 growing FA<sup>1</sup>. There are two possibilities that could account for a core biopsy proven FA being rediagnosed as a PT: the possibility of having misdiagnosed a PT, or, more rarely, the progression of a FA into a PT<sup>2</sup>.

The standard procedure for treatment, no matter what the grade of the PT, is surgical wide local excision, preferably with clear margins of at least 1 cm<sup>3</sup>. Effective surgical treatment many times requires a mastectomy because of the volume of the tumor or its location. We report the case of a 63-year-old woman with a mammotome biopsy proven FA that underwent transformation into a benign PT after one year of size stability. The patient was submitted to a conservative breast surgery with the use of oncoplastic technique which allowed an effective treatment associated to a good aesthetic outcome.

## CASE REPORT

A 63-year-old woman presented to us asymptomatic with her screening breast exams. On initial assessment, the patient had no hormonal background though a positive family history of breast carcinoma. Ultrasound and mammography revealed suspected nodule on the left breast. The patient had a normal clinical. Mammotome biopsy revealed FA, and clinical follow was done. After one year asymptomatic, she presented to us with a history of rapidly growing very large left breast swelling. Clinical examination revealed a 4 cm obvious mass of the left breast. The skin of the breast was enlarged, red and warmth. Another mammotome biopsy was done and suggested PT.

The patient underwent to a lumpectomy surgery with skin resection, to achieve adequate margins, and proceeded to immediate breast reconstruction and contralateral symmetry. The tumor was on the intersection outer quadrants, and the tissue removed was replaced by inferior dermotocutaneous pedicle. Definitive histology showed benign PT with clear excision margins (Figures 1 and 2).

## DISCUSSION

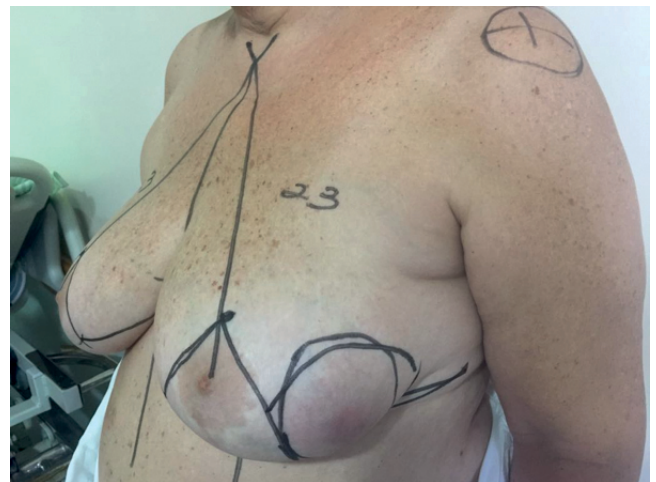PT are rare, comprising only 0.3–1% of all primary breast tumors<sup>4</sup>. This lesion was first described by Joahannes Müller in 1838 as Cystosarcoma Phyllodes, and its malignance behavior was recognized by Lee and Pack in 1931 in their series of 111 cases with one mortality by pulmonary metastasis<sup>5</sup>.

The age of presentation is usually 40–50 years, but these tumors can present at any age. Rare reports in men are often associated with gynecomastia, suggesting a role for hormonal influence on its physiopathology<sup>4</sup>.

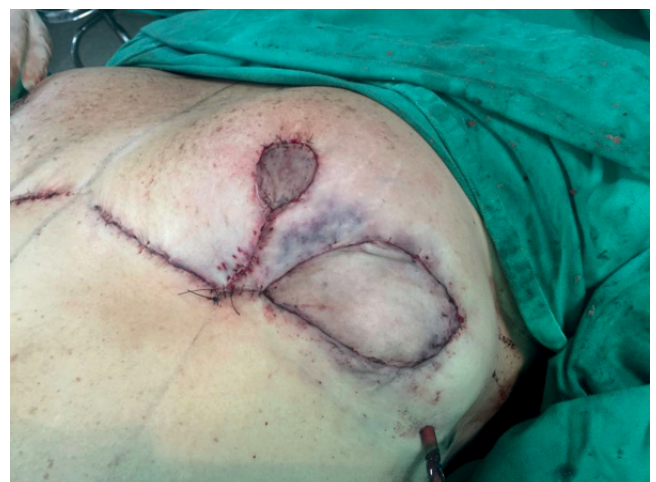PT is hypercellular fibroepithelial lesion that have a wide morphological spectrum. The benign PT shows overlapping features with cellular FA, whereas the malignant tumors may have a morphological resemblance with primary breast sarcoma or spindle cell metaplastic carcinoma<sup>4</sup>.

PT is graded according to recommendations by the World Health Organization (WHO) as benign, borderline, or malignant based on the presence and degree of stromal cellularity, atypia, mitotic activity, border infiltration versus circumscription and stromal overgrowth<sup>4</sup>.

Most tumors (60–75%) are benign, with borderline and malignant tumors constituting 15–20% and 10–20%, respectively.



**Figure 1.** The tumor had 4 cm and was on the intersection outer quadrants of left breast with skin commitment.



**Figure 2.** Immediate post-operative result using inferior dermotocutaneous pedicle technique.



The histological features determinate the biological behavior of the tumor. Recurrence rates may have some variation in the literature, but overall are 10–17, 14–25 and 23–30% for benign, borderline and malign tumors, respectively. Metastatic potential is very low on borderline tumors (0–4%), whereas malignant tumors demonstrating metastatic potential up to 22% of cases<sup>3,4</sup>. There are extremely rare reports of metastasis on benign tumor with the qualification that all tumors should be adequately sampled account for intratumoral heterogeneity<sup>3</sup>.

Despite all the effort establishing criteria for diagnosing PT, Thomas et al. showed the difficulty that exists in distinguishing some cellular FA from PT even for pathologists who specialize in breast pathology. On a 21 study cases, we only have 100% agreement in 2 cases as to whether the tumor represented a FA or PT. If the diagnoses of FA/cellular FA and benign PT were combined and separated from the borderline and malignant PT, there was agreement in 53% of cases<sup>6</sup>.

Diagnoses in core needle biopsy specimen may be even harder. Choi et al. analyzed histopathological features of core needle biopsy and surgical excision specimen comparatively in 129 patients with surgically proven PT. The concordant rate of diagnosis was about 60%, and all discordant diagnoses were underestimated in matched core needle biopsy. The hypotheses that they found to explain their results was that in core needle biopsy it is possible sample only a part of the total lesion and the intrinsic heterogeneity of the tumor. They conclude that fewer mitoses of PT are observed in core needle biopsy than in surgical excision generally<sup>7</sup>.

Many reports tried to define predictors factors for PT transformation from FA. Abe et al., analyzing 36 cases of malignant transformations of FA to PT, concluded that rapid tumor growth or sudden increase in size is the most important clinical characteristic for prediction of progression<sup>8</sup>. However, it is difficult to assess the reliability of this observation because no rate of growth was defined as a risk cut off and most of growing FA does not involve PT<sup>1</sup>.

Besides the diagnoses issue, clinical management is another point that have been discussed. The mainstay of PT management has traditionally consisted of surgical excision with wide tumor-free margins, generally defined as at least 10 mm, for an adequate local control<sup>3</sup>.

Some recent data tried to evaluate the real importance of wide tumor-free margins. Mangi et al. from Massachusetts General

Hospital found that post-excision recurrences were exclusively to cases with positive margins or margins of less than 10 mm<sup>9</sup>. Otherwise, Onkendi et al., from Mayo Clinic, found that the extent of surgical excision had no impact on disease free survive in a study with borderline and malignant tumors. However, because of the small numbers of patients treated with breast conservation with narrow margins, they recommend caution on this analysis and advertise that these finds are not enough to change clinical practice<sup>10</sup>. As convincing evidence for appropriate margin surgical excised PT remains elusive, width surgical margins remain the option of most of specialist. A more conservative approach can be considerable in specific cases of benign tumor<sup>3</sup>.

Breast conservative surgery can be a challenge on PT treatment. On a study of 170 patients with PT, the mean of tumor size was 7 cm, and most of the patients presented with a tumor bigger than 5 cm<sup>11</sup>. High dimensions associated with width margins leads to an important specimen resection. Cochrane et al. demonstrated that 20% of breast volume excised is enough to have an important risk of a poor cosmetic result<sup>12</sup>. To avoid mastectomy, the use of oncoplastic techniques prove to be an important tool to achieve good cosmetic outcome on patients who need big breast volume resections<sup>13</sup>. On our patient, because of the skin commitment, the size and the location of the tumor, we believe that the simple width resection would probably result on a breast deformation. The use of oncoplastic technique allowed us to achieve a breast conservative treatment with a satisfactory cosmetic result.

Because of the infrequency of lymph nodal disease in PT, most investigators do not recommend routine axillary dissection. The role of adjuvant therapy remains imprecise and its uses is considered on a case-by-case basis<sup>3,11</sup>.

## CONCLUSION

In summary, management of PT presents the specialist with unique challenges. Diagnostically, we believe that mammary biopsy represents the best tool for ambulatory approach. However, a negative result does not exclude the chances of a PT, and close follow up with a big eye on rapid growth is recommended. The local treatment remains width surgical excision, and the use of oncoplastic techniques might be useful in extending the indications for conservative therapy.

## REFERENCES






1. Sanders LM, Sara R. The growing fibroadenoma. *Acta Radiologica Open*. 2015;4(4):1-5. <http://doi.org/10.1177/2047981615572273>
2. Sanders LM, Daigle ME, Tortora M, Panasiti R. Transformation of benign fibroadenoma to malignant phyllodes tumor. 2015;4(4):1-3. <http://doi.org/10.1177/2058460115592061>
3. Tan BY, Acs G, Apple SK, Badve S, Bleiweiss IJ, Brogi E, et al. Phyllodes tumors of the breast: a consensus review. *Histopathology*. 2016;68(1):5-21. <http://doi.org/10.1111/his.12876>
4. Krings G, Bean GR, Chen YY. Fibroepithelial lesions; The WHO spectrum. *Semin Diagn Pathol*. 2017;34(5):438-52. <http://doi.org/10.1053/j.semmp.2017.05.006>



5. Boff RA. Compêndio de mastologia: abordagem multidisciplinar. Cap. 28. In: RA Boff, De Carli AC, Brenelli H, Brenelli FP, De Carli LS, Sauer FZ, et al. Editors. Compêndio de mastologia: abordagem multidisciplinar. 1st ed. Caxias do Sul: I C DE SOUZA OLIVEIRA LIVRARIA ME, 2015. p.331-6.
6. Lawton TJ, Acs G, Argani P, Farshid G, Gilcrease M, Goldstein N, et al. Interobserver variability by pathologists in the distinction between cellular fibroadenomas and phyllodes tumors. *Int J Surg Pathol.* 2014;22(8):695-8. <http://doi.org/10.1177/1066896914548763>
7. Choi J, Koo JS. Comparative study of histological features between core needle biopsy and surgical excision in phyllodes tumor. *Pathol Int.* 2012;62(2):120-6. <http://doi.org/10.1111/j.1440-1827.2011.02761.x>
8. Abe M, Miyata S, Nishimura S, Iijima K, Makita M, Akiyama F, et al. Malignant transformation of breast fibroadenoma to malignant phyllodes tumor: long-term outcome of 36 malignant phyllodes tumors. *Breast Cancer.* 2011;18(4):268-72. <http://doi.org/10.1007/s12282-009-0185-x>
9. Mangi AA, Smith BL, Gadd MA, Tanabe KK, Ott MJ, Souba WW, et al. Surgical management of phyllodes tumors. *Arch Surg.* 1999;134(5):487-93. <http://doi.org/10.1001/archsurg.134.5.487>
10. J Onkendi EO, Jimenez RE, Spears GM, Harmsen WS, Ballman KV, Hieken TJ. Surgical treatment of borderline and malignant phyllodes tumors: the effect of the extent of resection and tumor characteristics on patient outcome. *Ann Surg Oncol.* 2014 Oct;21(10):3304-9. <http://doi.org/10.1245/s10434-014-3909-x>
11. Reinfuss M, Mituś J, Duda K, Stelmach A, Rys J, Smolak K. The Treatment and Prognosis of Patients with Phyllodes Tumor of the Breast. *Cancer.* 1996;77(5):910-6.
12. Cochrane RA, Valasiadou P, Wilson AR, Al-Ghazal SK, Macmillan RD. Cosmesis and satisfaction after breast-conserving surgery correlates with the percentage of breast volume excised. *Br J Surg.* 2003;90(12):1505-9.
13. Clough KB, Lewis JS, Couturaud B, Fitoussi A, Nos C, Falcou MC. Oncoplastic techniques allow extensive resections for breast-conserving therapy of breast carcinomas. *Ann Surg.* 2003;237(1):26-34.

# CASE REPORT: INTRADUCTAL PAPILLOMA OF THE MALE BREAST

## Relato de caso: papiloma intraductal em mama masculina

Vivian Milani<sup>1</sup> , José Alano Costa Oliveira Júnior<sup>1\*</sup> , Herbert Franchi Teixeira Andreghetto<sup>1</sup> ,  
Anita Mayara Feitosa Santos<sup>1</sup> , Emília Virginia Lima Curvelo Fontes<sup>1</sup> 

### ABSTRACT

Breast benign tumors, intraductal papilloma and fibroadenomas are common conditions in women; however, they are very rare in males. In this study, we report the case of a male patient, 75 years old, presenting with complaint of bilateral gynecomastia and palpable retroareolar mass in the left breast. The patient was submitted to imaging tests and core biopsy, and the hypothesis of intraductal papilloma was confirmed upon anatomopathological study. The mastology team opted for excision of the lesion and correction of gynecomastia.

**KEYWORDS:** intraductal papilloma; breast; gynecomastia; breast diseases.

### RESUMO

Tumores benignos da mama, papiloma intraductal e fibroadenomas são condições comuns em mulheres, mas muito raras em homens. Neste estudo, relatamos o caso de um paciente do sexo masculino, com 75 anos de idade, cuja queixa era de ginecomastia bilateral e massa retroareolar palpável na mama esquerda. O paciente foi submetido a exames de imagem e *core-biopsy*, e a hipótese de papiloma intraductal foi confirmada após estudo anatomopatológico. A equipe de mastologia optou pela excisão da lesão e correção da ginecomastia.

**PALAVRAS-CHAVE:** papiloma intraductal; mama; ginecomastia; doenças mamárias.

<sup>1</sup>Radiology and Diagnostic Imaging Service, Hospital do Servidor Público Estadual – São Paulo (SP), Brazil.

\*Corresponding author: josealano.jr@gmail.com

Conflict of interests: nothing to declare.

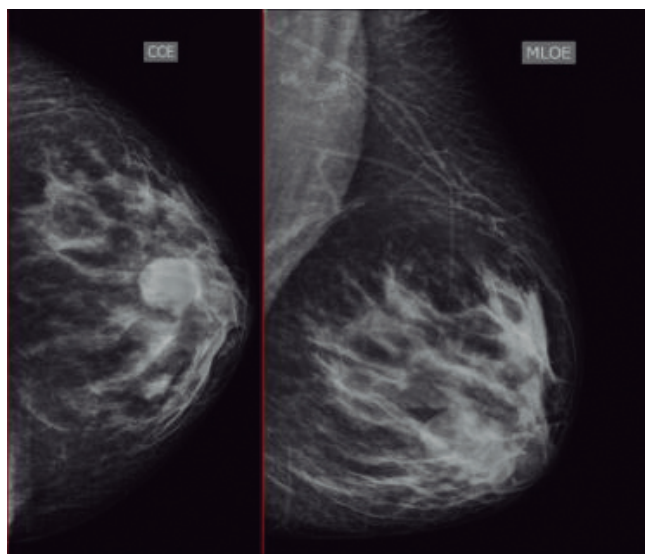
Received on: 12/26/2018. Accepted on: 12/27/2018

## INTRODUCTION

At birth, a male's breast is very similar to a female's breast. However, due to the increase in testosterone levels in the pre-pubertal period in males, there is involution and atrophy of the lactating ducts. There is also no increase in estrogen and progesterone levels<sup>1</sup>. Gynecomastia is the most common disease of the male breast, but just like in the female breast, diseases related to stromal and ductal proliferation can occur, including carcinoma, fibroadenoma, lipoma, fat necrosis, and papilloma. Although extremely rare, the intraductal papilloma is characterized as a benign affection of the male breast<sup>2</sup>.

## CASE REPORT

A 75-year-old patient was assisted at the Service of Radiology with history of bilateral gynecomastia and palpable nodule in the left breast since July 2017. He denied the use of medication and steroids. There was a palpable rounded nodule in the left subareolar region which was not painful to palpation and presented no skin thickening or papillary discharge. Mammography (Figure 1) showed bilateral fibroganular tissue (Grade IV Gynecomastia) and a rounded, dense nodule with circumscribed margins, measuring 3.7 cm in its largest diameter in the left breast's retroareolar region (BIRADS 4). Ultrasonography (Figure 2) showed a circumscribed round hypoechogenic nodule in the left breast's retroareolar region, measuring  $2.9 \times 2.0 \times 2.0$  cm and 1,0 cm distant from the skin. Histological examination by biopsy with a thick needle (Figure 3) showed ductal proliferation compatible with intraductal papilloma. Excision of the lesion was indicated by the mastology team, followed by esthetic correction of gynecomastia at the patient's request.

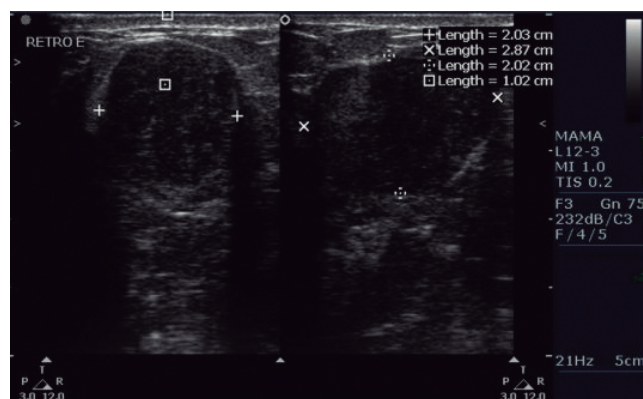


**Figure 1.** (A) Craniocaudal and (B) oblique mediolateral mammography of the left breast showing nodular retroareolar lesion.

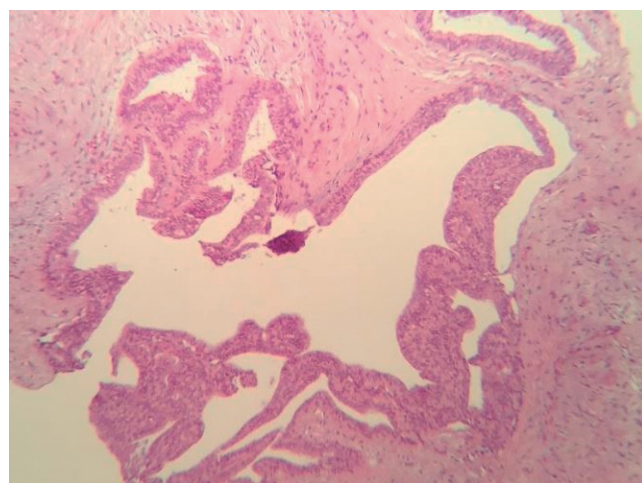
## DISCUSSION

Intraductal papilloma is a rare benign neoplasm that can affect men at any age and manifests clinically as a palpable mass, usually unilateral, painful or not, with or without papillary discharge<sup>3</sup>. Histologically, it is characterized by epithelial proliferation with uniform distribution of myoepithelial cells nurtured by fibrovascular nuclei<sup>4</sup>.

Radiological diagnosis is based on mammography, ultrasonography and, when necessary, complementary magnetic resonance imaging (MRI). Ultrasonography is more sensitive than mammography to detect intraductal papilloma, and the main findings are: intraluminal mass with dilated duct and inner hypervascularization shown in Doppler study<sup>5</sup>. However, a study by Lam et al.<sup>6</sup> reported that imaging findings are neither sensitive nor specific enough to distinguish benign from malignant papillomatous lesions; therefore, surgical excision



**Figure 2.** Ultrasonography of the left breast showing a solid hypoechogenic nodule measuring  $2.9 \times 2.0 \times 2.0$  cm, and 1.0 cm distant from the skin.



**Figure 3.** Microscopy of material from the left breast: fragment from breast with intraductal.

and histopathological analysis are required. Two other studies have shown different conclusions: Sydnor et al.<sup>7</sup> supports only mammographic follow-up for core-biopsy-diagnosed lesions, since the potential for malignancy is low (3%); Swapp et al.<sup>8</sup> also reported being against surgical excision of benign papilloma diagnosed by core-biopsy, as they consider follow-up enough and emphasize the need for surgical excision only for atypical papillomatous lesions found in core-biopsy due to high potential for malignancy (67%).

## CONCLUSION


Follow-up instead of surgical excision has become the best option for papillary lesions without atypia diagnosed by percutaneous biopsies, especially when not presenting with microcalcifications, as a palpable mass, or not showing characteristics that would lead to suspicion in imaging exams. Intraductal papilloma is an extremely rare condition characterized as a benign affection of the male breast. Surgical excision was indicated by the mastology team, followed by esthetic correction of gynecomastia at the patient's request.

## REFERENCES

1. De Vries, Walter AW, Vrouwenraets BC. Intraductal Papilloma of the Male Breast. *J Surg Case Rep*. 2016;2016(2):rjw014. <https://dx.doi.org/10.1093%2Fjscr%2F2Frjw014>
2. Rakha EA, Ho BC, Naik V, Sen S, Hamilton LJ, Hodi Z, et al. Outcome of breast lesions diagnosed as lesion of uncertain malignant potential (B3) e suspicious of malignancy (B4) on needle core biopsy, including detailed review of epithelial atypia. *Histopathology*. 2011;58(4):626-32. <https://doi.org/10.1111/j.1365-2559.2011.03786.x>
3. Cerri GG, Leite CC, Rocha MS. *Tratado de Radiologia. Barueri: Manole; ano. v. 3.*
4. Shim JH, Son JU, Kim EK, Kwak JY, Jeong J, Hong SW. Benign Intracystic Papilloma of the Male Breast. *J Ultrasound Med*. 2008;27(9):1397-400.
5. Nguyen C, Kettler MD, Swirsky ME, Miller VI, Scott C, Krause R, et al. Male Breast Disease: Pictorial Review with Radiologic-Pathologic Correlation. *Radiographics*. 2013;33(3):763-79. <https://doi.org/10.1148/rg.333125137>
6. Lam WW, Chu WC, Tang AP, Tse G, Ma TK. Role of radiologic features in the management of papillary lesions of the breast. *Am J Roentgenol* 2006;186(5):1322-7. <https://doi.org/10.2214/AJR.04.1908>
7. Sydnor MK, Wilson JD, Hijaz TA, Massey HD, Shaw de Paredes ES. Underestimation of the presence of breast carcinoma in papillary lesions initially diagnosed at core-needle biopsy. *Radiology*. 2007;242(1):58-62. <https://doi.org/10.1148/radiol.2421031988>
8. Swapp RE, Glazebrook KN, Jones KN, Brandts HM, Reynolds C, Visscher DW, et al. Management of benign intraductal solitary papilloma diagnosed on core needle biopsy. *Ann Surg Oncol*. 2013;20(6):1900-5. <https://doi.org/10.1245/s10434-012-2846-9>

# ANAPLASTIC LYMPHOMA MIMICKING BREAST CARCINOMA

## Linfoma anaplásico mimetizando carcinoma mamário

Rafael da Silva Sá<sup>1,2</sup> , Tatiana Veri de Arruda Mattos<sup>3</sup> ,  
Andressa Veri de Arruda Mattos<sup>1</sup> , Hugo Máximo Oliveira Diniz<sup>1</sup> , Maycon Luan Eburnio<sup>1</sup> 

### ABSTRACT

This case describes an uncommon presentation of ALK-negative anaplastic large T-cell lymphoma with breast infiltration, mimicking triple-negative carcinoma. The incidence of ALK-negative anaplastic large T-cell lymphoma usually occurs in adults in their fifth and sixth decade of life and can affect lymph nodes and extranodal sites, including skin, soft tissue, and gastrointestinal tract. The non-Hodgkin's lymphoma of the breast is uncommon, accounting for 0.04 to 0.05% of all malignant breast tumors. Diagnosis of ALK-negative anaplastic large T-cell lymphoma is challenging both to physicians and pathologists. Based on the complete medical history, clinical and imaging exams and histopathological evaluation of the lesion site biopsy, it is possible to establish an adequate diagnosis. The case describes a woman aged 37 years with palpable nodules in the left breast as well as erythematous lesions on the right leg. The analysis of the breast nodules biopsy shows that they mimic triple-negative carcinoma. However, only with immunohistochemical examination was it possible to verify the expression of the CD30 antigen, and only after a complete systemic evaluation, the diagnosis of ALK-negative anaplastic large T-cell lymphoma was performed. Misdiagnosis can lead to inadequate therapy and result in disease progression or unnecessary damages to the patient.

**KEYWORDS:** Lymphoma, non-Hodgkin; lymphoma, large-cell, anaplastic ; breast neoplasms; T-cell lymphoma.

### RESUMO

Este caso descreve uma incomum apresentação de linfoma anaplásico de grandes células T ALK negativo com infiltrado mamário, mimetizando carcinoma triplo negativo. A incidência do linfoma anaplásico de grandes células T ALK negativo, ocorre comumente em adultos na quinta e sexta década de vida e pode acometer linfonodos e locais extranodais, incluindo pele, tecido mole e trato gastrointestinal. O linfoma não-Hodgkin da mama é incomum, compondo 0,04 a 0,05% de todos os tumores de mama malignos. O diagnóstico de linfoma anaplásico de grandes células T ALK negativo é desafiador tanto para clínicos como para patologistas. O estabelecimento de um diagnóstico adequado é possível com base em histórico médico completo, exames clínicos e de imagem e avaliação histopatológica da biópsia do local da lesão. O caso relata uma mulher de 37 anos com nódulos palpáveis na mama esquerda em conjunto com lesões eritematosas na perna direita. Ao se analisar a biópsia dos nódulos da mama, esses mimetizavam carcinoma triplo negativo, no entanto, somente com exame imunohistoquímico foi possível verificar a expressão do antígeno CD30, e, apenas após uma avaliação sistêmica completa, foi realizado o diagnóstico de linfoma anaplásico de grandes células T ALK negativo. O diagnóstico equivocado pode acarretar terapia inadequada e resultar em progressão da doença ou em danos desnecessários ao paciente.

**PALAVRAS-CHAVE:** Linfoma não Hodgkin; linfoma anaplásico de células grandes; neoplasia da mama; linfoma de células T.

<sup>1</sup>Universidade Federal de São Paulo – São Paulo (SP), Brazil.

<sup>2</sup>Universidade do Oeste Paulista – Presidente Prudente (SP), Brazil.

<sup>3</sup>Santa Casa de São Paulo Hospital – São Paulo (SP), Brazil.

\*Corresponding author: hugomaximodiniz@gmail.com

Conflict of interests: nothing to declare.

Received on: 02/11/2019. Accepted on: 02/19/2019.



## INTRODUCTION

The ALK-negative anaplastic large T-cell lymphoma (ALCL) represents a non-Hodgkin lymphoma with expression of the CD30 antigen. Stein and his collaborators were the first ones to recognize a subtype of tumors with large cells exhibiting anomalous morphological features with prominent sinusoidal invasion and expressing the CD30 antigen (formerly known as Ki-1).<sup>1</sup>

Due to the lack of strict morphological criteria, some tumors were diagnosed as Ki-1 lymphomas only for constituting antigen CD30-positive large cells, regardless of the presentation of their cell phenotype (B, T or null).<sup>1</sup> Subsequently, the term Ki-1 lymphoma was substituted for anaplastic large cell lymphoma.

Although there has not been a clear consensus among pathologists concerning the definition of anaplastic, and even though some of these tumors consisted of small and medium cells, the term anaplastic large cell lymphoma was incorporated into most classifications. Afterward, it was found that a significant proportion of ALCL is associated with translocation t (2; 5) (p23; q35).<sup>1</sup> The cloning of this translocation and the production of antibodies, detecting the gene product — anaplastic lymphoma kinase (ALK) — meant great advance. Hence, ALCLs were divided into two main categories: those positive to ALK protein and those that lack these markers.<sup>1</sup>

In the third edition of the World Health Organization (WHO) classification of hematopoietic neoplasia, ALK-positive (ALK+) and -negative (ALK-) ALCL were considered a unique entity and defined as lymphomas consisting of lymphoid cells, which usually are large, have abundant and pleomorphic cytoplasm and whose nuclei, very often, are horseshoe-shaped.<sup>1</sup> The cells present CD30 antigen and, in most of the cases, proteins are associated with cytotoxic granules and epithelial membrane antigen (EMA).<sup>1</sup> Even though ALCL expressing ALK are relatively homogeneous, it became evident that cases with similar morphology and phenotypes, but without ALK expression, are much more heterogeneous. ALK- ALCL also differ from peripheral T-cell lymphomas.

In the fourth edition of the WHO classification, ALK+ ALCL was determined as a distinct entity, while ALK- ALCL, as provisory.<sup>1</sup> However, in 2016, the WHO updated the classification of lymphoid neoplasms, and, therefore, ALK- ALCL was determined as a defined rather than provisory entity, since it presents specific cytogenetic subsets that seem to have prognostic implications.<sup>2</sup> In this same update, the breast implant-associated anaplastic large T-cell lymphoma was classified as a new provisional entity distinguished from ALK- ALCL and determined as a noninvasive disease associated with better prognosis.<sup>2</sup>

The incidence of ALK- ALCL usually occurs in adults in their sixth decade of life and presents worse prognosis than ALK+ ALCL, that affects more often children and young adults.<sup>3</sup> Men are more commonly affected than women at a ratio of 1.5:1.<sup>3</sup> Patients usually present adenopathy and, often, B symptoms (fever, night sweats, and weight loss). ALK- ALCL may affect

lymph nodes and extranodal sites, including skin, soft tissues, and gastrointestinal tract.<sup>3</sup>

The neoplasia is featured by large pleomorphic cells, some with prominent nucleoli and multinucleation, that have a variable number of characteristic cells, horseshoe- or kidney-shaped nuclei, and inconsistently express EMA.<sup>4,5</sup>

Due to morphological variations, the ALK- ALCL may lead to greater diagnostic difficulties — since it mimics other types of lymphoma and can also have a cohesive growth pattern, mimicking nonhematologic malignant neoplasias, like sarcomas, carcinomas, tumors of germ cells and melanoma.<sup>6,7</sup> Thus, clinic history and staging data are essential to determine the initial site of presentation, the extent of extracutaneous involvement, and the order of events in the disease course.<sup>8</sup>

Non-Hodgkin's lymphoma of the breast is uncommon, accounting for 0.04 to 0.5% of all malignant breast tumors.<sup>9</sup> Most primary breast lymphomas are B-cell phenotype or have not been immunophenotyped; only rare cases have been reported as large T-cell lymphoma infiltrating breast tissue.<sup>9</sup>

Therefore, this article aims to report a case of ALK- ALCL — infiltrating breast tissue, mimicking primary breast neoplasia — considering how rare this location is and the difficulties in the diagnostic process. This case report highlights the importance of anatomopathological examination of surgical specimens associated with the patient's clinical data to help in the immunohistochemical and morphological differential diagnosis, leading to specific treatment and avoiding unnecessary procedures.

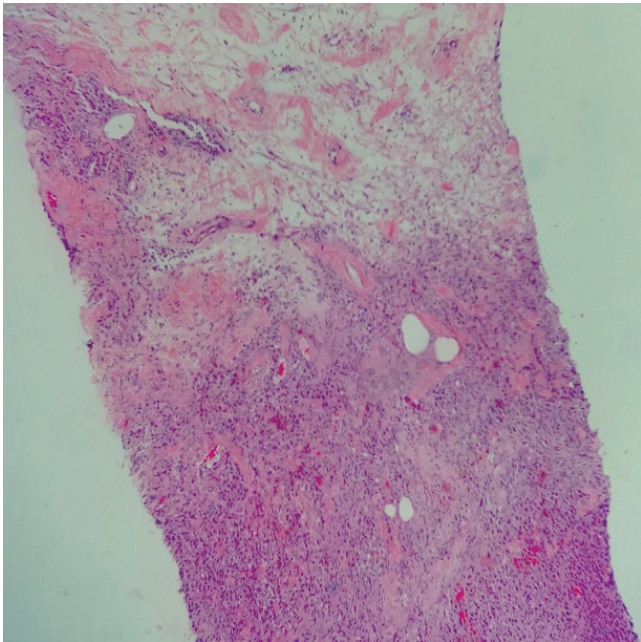
## CASE REPORT

Female patient, 37 years of age, cleaning assistant, obesity level 1, was admitted to the Medical Clinic of *Hospital Regional de Presidente Prudente* in May 2017, presenting for about a month two palpable nodules associated with nipple retraction in the union of the lower quadrants of the left breast and erythematous-violaceous lesions with well-defined contours, varied sizes, hyperchromic and without secretion on the inner side of the right leg. On physical examination, the patient was in a good overall condition, afebrile, anicteric and acyanotic, denied fever or weight loss in recent months, but reported having previously had inguinal ipsilateral lymph node enlargement with spontaneous resolution.

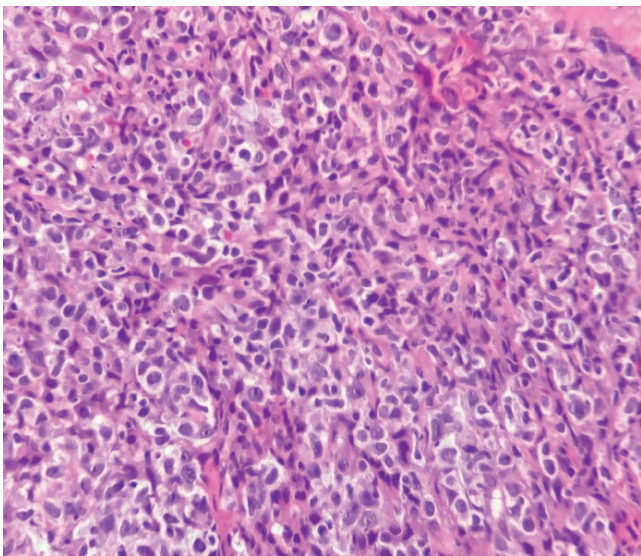
During hospitalization, a complete blood count was performed, as well as imaging examinations and core biopsy (removal of a breast tissue sample with a thick needle). Laboratory tests presented leukogram with no changes, complete blood count with erythrocyte sedimentation rate altered to 33 mm/h (reference range up to 20 mm/h) and increased lactic dehydrogenase, 1,073 U/L (reference range 200 to 480 U/L).

Thorax computed tomography showed enlarged lymph nodes in the axillary chain bilaterally and multiple nodular images were seen in the left breast.

In the anatomopathological examination of the core biopsy, the microscopy, the breast tissue presented areas with infiltration by large cells neoplasia with intense anaplasia and atypical mitotic figures, with cell cohesion, delimited by fibrillar connective tissue proliferation (Figure 1). The neoplastic cells have pleomorphic and hyperchromatic nuclei and prominent nucleoli, with atypical mitotic figures, morphologically favoring the diagnosis of high-grade breast carcinoma (Figures 2 and 3). The initial



**Figure 1.** Hematoxylin-Eosin Staining, increase 10x, core biopsy, malignant neoplasia infiltrating breast parenchyma.



**Figure 2.** Hematoxylin-Eosin Staining, increase 20x, core biopsy, anaplastic large T-cell lymphoma with presence of pleomorphic cells, sometimes multinucleated, with prominent nucleoli and atypical mitotic figures, making up a solid block of cohesive standards, mimicking carcinoma.

immunohistochemical profile was negative for estrogen, progesterone, and androgens receptors, as well as for E-cadherin and lack of overexpression of the HER2 oncogene, mimicking breast carcinoma with a triple-negative molecular classification. However, diagnostic investigation was continued due to the acquisition of clinical and laboratory information about the patient.

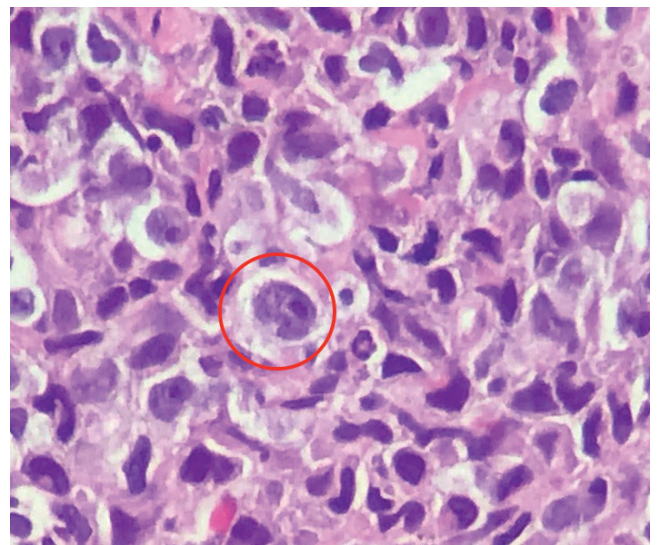
Thus, the immunocytochemical panel was expanded to CD20, CD5, CD45, CD30, and ALK markers, taking into account it is an ALK-negative anaplastic large T-cell lymphoma, due to lack of ALK protein (Figure 4), with expression of antigens CD30 (Figure 5), CD5, CD45 and high rate of cellular proliferation (KI-67). Chart 1 shows the results of the markers used in the immunohistochemical evaluation.

The therapy instituted consisted of 8 cycles of chemotherapy every 28 days, using the therapeutic scheme called CHOEP (cyclophosphamide, doxorubicin, vincristine, etoposide, and prednisone). One month after the first cycle, there was good chemotherapy response with significant regression of the breast tumor and the skin lesions.

## DISCUSSION

The non-Hodgkin's lymphoma of the breast is uncommon, accounting for 0.04 to 0.05% of all malignant breast tumors.<sup>9</sup> It comprises 2.2% of extranodal non-Hodgkin's lymphomas and 0.38% of all non-Hodgkin's lymphomas.<sup>10,11</sup> Most primary breast lymphomas are B-cell phenotype or have not been immunophenotyped; only a few cases have been reported as large T-cell lymphoma infiltrating breast tissue.<sup>9</sup>

The vast majority of cases show clonal rearrangement of T-cell gene receptors, whether or not they express T-cell antigens.<sup>1</sup>

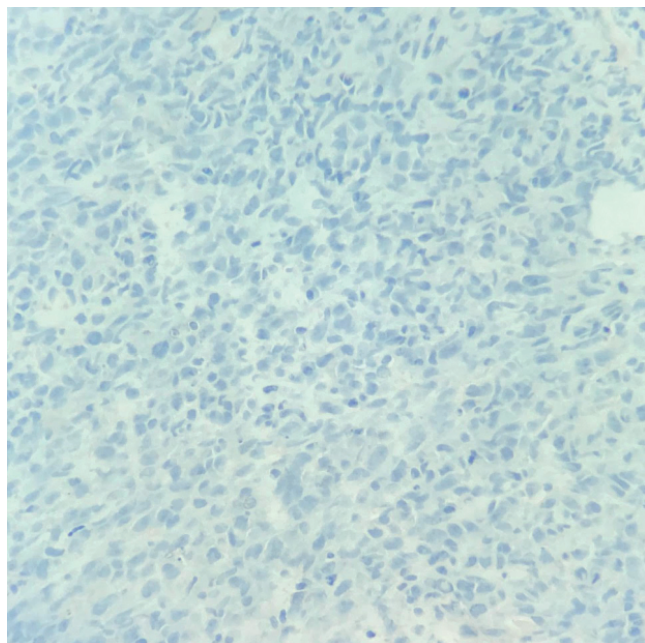


**Figure 3.** Hematoxylin-Eosin Staining, increase 100x, breast core biopsy, "horseshoe-shaped cell" with bleaching of the Golgi apparatus, characteristic of anaplastic large T-cell lymphoma.

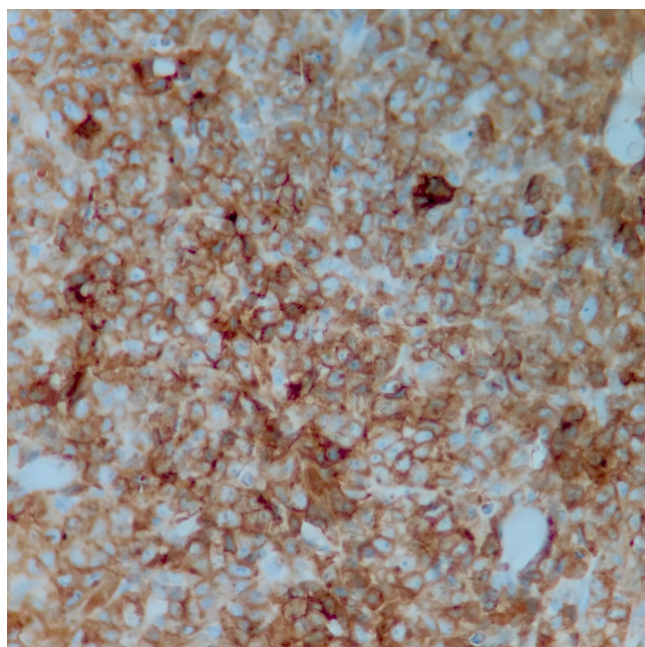


Primary cytogenetic abnormalities do not recur frequently. Studies indicate a tendency of ALK- ALCL to differ (concerning chromosome gain or loss) from peripheral T-cell lymphoma and ALK+ ALCL.<sup>1</sup>

Recently, specific chromosomal rearrangements to ALK- ALCL, Dual Specificity Phosphatase 22 (DUSP22) and Tumor Protein



**Figure 4.** Immunohistochemical marker to ALK/p80, lack of immunoreactivity in tumor cells.



**Figure 5.** Immunohistochemical marker to CD30, showing diffuse positivity and homogeneous expression of this marker in tumor cells.

P63 (TP63), unique and mutually exclusive, have been identified, which is important to further prognosis stratification.<sup>12</sup> Studies have shown that the chromosomal rearrangement of the DUSP22 has a five-year overall survival rate of 90%.<sup>12</sup> On the other hand, TP63 rearrangements show worse prognosis with a five-year overall survival of 15% and poor response to the initial treatment.<sup>12</sup> At the moment, the pathogenesis of these rearrangements is unknown and remains under investigation.<sup>8</sup>

This article reported a case of a 37-year-old woman with ALK- ALCL. According to literature, this type of lymphoma affects more men than women, at a ratio of 1.5-:1.<sup>3</sup> Regarding age range, it mainly affects adults from 40 to 65 years of age.<sup>1</sup>

Clinical manifestations of this type of cancer are heterogeneous. Many patients have systemic B symptoms (fever, night sweats, and weight loss), present high score on the International Prognostic Index, and aggressive clinical course.<sup>13,14</sup> However, a subset of patients has a less aggressive course because of the type of chromosomal rearrangement presented.<sup>12</sup>

Patients may have peripheral or abdominal lymphadenopathy, or extranodal tumor.<sup>1</sup> The most frequent ALK- ALCL extranodal involvement is seen in the cutaneous, hepatic, and gastrointestinal tract areas. In the study by Savage et al.,<sup>3</sup> from 55 patients with ALK- ALCL diagnosis, only one presented extranodal involvement in the breast. In the case reported here, there were palpable nodules in the left breast, leading to local skin retraction. The description of this type of presentation in this neoplasia is uncommon. However, the patient also presented multiple erythematous-violaceous lesions of well-defined contours, different sizes, hyperchromic and without secretion, located on the inner side of the right leg. These lesions, presented by the reported patient, match the literary description of the lymphoma under discussion. In this case, that helped in the performance of the immunohistochemical examinations of the percutaneous breast biopsy.

#### Chart 1. Immunohistochemical evaluation.

CerbB-2 Oncoprotein (Her-2 Sp3)	Negative (score 0)
EstrogenReceptor (SP1)	Negative
ProgesteroneReceptor (SP2)	Negative
E-cadherin (36)	Negative
Androgen Receptor (SP107)	Negative
ALK/p80	Negative
CD20 (L26)	Negative
Ki-67 (MAB SP6)	High rate of cellular proliferation
CD5 (LEU-1)	Positive
CD30 (Ber-H2)	Positive
CD45 (T29/33)	Positive
GATA3 (L50-823)	Positive

Otherwise, the diagnosis could easily be misleading, since, histologically, the breast specimen analyzed alone is similar to the triple-negative carcinoma. As well as in the immunohistochemical assessment, the absence of expression of estrogen (ER) and progesterone receptors (PR), and HER2 usually characterizes a triple-negative breast cancer, responsible for 10 to 15% of invasive breast cancers, more often affecting patients under 50 years of age, presenting an aggressive type of tumor and decrease survival when compared to other subtypes.<sup>15</sup> Only other chemical markers like CD30 were assessed, depending on the case association — since the biopsies of both the left breast core and the right leg skin lesions were sent separately and without clinical correlation to the pathology department.

An review article reported that most patients with ALK-ALCL received CHOP treatment or similar, like the patient reported in this case. Specific therapies for this subtype have not yet been introduced, but the CD30-targeted therapies have proven to be effective.<sup>8</sup>

The International T-Cell Lymphoma Project revealed that patients with ALK-ALCL have an overall five-year survival

of 49%.<sup>16</sup> Other chemotherapy combinations did not produce better outcomes when compared to CHOP. The ALK-ALCL neoplasia usually present lower response rates to the initial treatment, with a chance of 45% to 65% of recurrence with the first-line treatment.<sup>3</sup> In a prospective study, the initial treatment with CHOP produced a complete response in 39% of patients with ALK-ALCL.<sup>17</sup>

## CONCLUSION

The diagnosis of ALK-ALCL is challenging for both physicians and pathologists, given the histopathological spectrum of findings. This case reported an unusual presentation of this pathology with appearance in breast tumor. Although rare, the breast may be a incidence area of this neoplasia. The adequate diagnosis, in this case, was possible because of the association of clinical data with immunological complementary exams, from the breast nodule sample as well as the biopsy of the skin lesion. Accurate diagnosis avoids inadequate therapies and unnecessary procedures to an ALK-ALCL.

## REFERENCES

- Delsol G, Lamant-Rochaix L, Brousset P. Anaplastic Large Cell Lymphoma, ALK Positive and ALK Negative. In: Jaffe ES, Harris NL, Vardiman JW, Campo E, Arber DA, eds. Hematopathology. Philadelphia: Saunders/Elsevier; 2011. p. 564-579.
- Swerdlow SH, Campo E, Pileri SA, Harris NL, Stein H, Siebert R, et al. The 2016 revision of the World Health Organization (WHO) classification of lymphoid neoplasms. *Blood*. 2016;127(20):2375-90. <https://doi.org/10.1182/blood-2016-01-643569>
- Savage KJ, Harris NL, Vose JM, Ullrich F, Jaffe ES, Connors JM, et al. ALK- anaplastic large-cell lymphoma is clinically and immunophenotypically different from both ALK+ALCL and peripheral T-cell lymphoma, not otherwise specified: report from the International Peripheral T-Cell Lymphoma Project. *Blood*. 2008;111(12):5496-504. <https://doi.org/10.1182/blood-2008-01-134270>
- Mason DY, Harris NL, Delsos G, Stein H, Campo E, Kinney MC, et al. Anaplastic large cell lymphoma, ALK-negative. In: Swerdlow SH, Campo E, Harris NL, Jaffe ES, Pileri SA, Stein H, et al., eds. WHO Classification of Tumours of Haematopoietic and Lymphoid Tissues. 4<sup>th</sup> ed. Lyon: International Agency for Research on Cancer; 2008. p. 317-9.
- Stein H, Foss HD, Dürkop H, Marafioti T, Delsol G, Pulford K, et al. CD30(+) anaplastic large cell lymphoma: a review of its histopathologic, genetic, and clinical features. *Blood*. 2000;96(12):3681-95.
- Chan JK, Buchanan R, Fletcher DC. Sarcomatoid variant of anaplastic large-cell Ki-1 lymphoma. *Am J Surg Pathol*. 1990;14(10):983-8.
- Kashiwabara K, Nakamura H, Kusama H, Kishi K, Yagyu H, Takagi S, et al. Ki-1 (CD30)-positive anaplastic large cell lymphoma, sarcomatoid variant accompanied by spontaneously regressing lymphadenopathy. *Intern Med*. 1999;38(1):49-53. <https://doi.org/10.2169/internalmedicine.38.49>
- Xing X, Feldman AL. Anaplastic Large Cell Lymphomas: ALK Positive, ALK Negative, and Primary Cutaneous. *Adv Anat Pathol*. 2015;22(1):29-49. <https://doi.org/10.1097/PAP.0000000000000047>
- Aguilera NS, Tavassoli FA, Chu WS, Abbondanzo. T-cell lymphoma presenting in the breast: a histologic, immunophenotypic and molecular genetic study of four cases. *Mod Pathol*. 2000;13(6):599-605. <https://doi.org/10.1038/modpathol.3880103>
- Eskelinen M, Collan Y, Puittinen J, Pajarinen P, Alhava E. Lymphoma of the breast. *Ann Chir Gynaecol*. 1989;78(2):149-52.
- Jeon HJ, Akagi T, Hoshida Y, Hayashi K, Yoshino T, Tanaka T, et al. Primary non-Hodgkin malignant lymphoma of the breast. An immunohistochemical study of seven patients and literature review of 152 patients with breast lymphoma in Japan. *Cancer*. 1992;70(10):2451-9. [https://doi.org/10.1002/1097-0142\(19921115\)70:10%3C2451::aid-cnrcr2820701011%3E3.0.co;2-b](https://doi.org/10.1002/1097-0142(19921115)70:10%3C2451::aid-cnrcr2820701011%3E3.0.co;2-b)
- Castellar R, Jaffe ES, Said JW, Swerdlow SH, Ketterling RP, Knudson RA, et al. ALK-negative anaplastic large cell lymphoma is a genetically heterogeneous disease with widely disparate clinical outcomes. *Blood*. 2014;124(9):1473-80. <https://doi.org/10.1182/blood-2014-04-571091>

13. Medeiros LJ, Elenitoba-Johnson KS. Anaplastic large cell lymphoma. *Am J Clin Pathol.* 2007;127(5):707-22. <https://doi.org/10.1309/R2Q9CCUVTLRYCF3H>
14. Ten Berge RL, Oudejans JJ, Ossenkoppele GJ, Meijer CJ. ALK-negative systemic anaplastic large cell lymphoma: differential diagnostic and prognostic aspects: a review. *J Pathol.* 2003;200(1):4-15. <https://doi.org/10.1002/path.1331>
15. Phipps AI, Chlebowski RT, Prentice R, McTiernan A, Wactawski-Wende J, Kuller LH, et al. Reproductive history and oral contraceptive use in relation to risk of triple-negative breast cancer. *J Nat Cancer Inst.* 2011;103(6):470-7. <https://doi.org/10.1093/jnci/djr030>
16. Vose J, Armitage J, Weisenburger D, International T-Cell Lymphoma Project. International Peripheral T-Cell and Natural Killer/T-Cell Lymphoma Study: Pathology Findings and Clinical Outcomes. *J Clin Oncol.* 2008;26(25):4124-30. <https://doi.org/10.1200/JCO.2008.16.4558>
17. Savage KJ. Characterization of peripheral T-cell lymphomas in a single North American institution by the WHO classification. *Ann Oncol.* 2004;15(10):1467-75. <https://doi.org/10.1093/annonc/mdh392>



# INSTRUCTIONS TO AUTHORS

## Introduction

*Mastology* is an international, multidisciplinary Journal, and official publication of the Brazilian Society of Mastology. It focuses on translational and clinical research of breast diseases. All manuscripts will be initially accessed by the Editor for suitability for the Journal. Papers deemed suitable are then evaluated by at least two independent expert reviewers, in a blind-review process to assess the scientific quality of the paper. The Editor is responsible by the final decision regarding acceptance or rejection of articles. Those that do not have merit, which contain significant methodological errors, or that do not fit into the editorial policy of the Journal will be rejected and can not be appealed. The reviewers' comments will be returned to the Authors for modifications in the text or justification of their conservation. Only after final approval of the reviewers and Editors, will the manuscripts be forwarded for publication. All manuscripts accepted for publication shall become the property of the Journal and may not be edited, in whole or in part, by any other means of dissemination, without the prior written authorization issued by the Editor-in-Chief.

## Ethics

If the paper involves the use of human subjects, the Authors should ensure that it has been carried out in accordance with The Code of Ethics of the World Medical Association (Declaration of Helsinki) for experiments involving humans; Uniform Requirements for manuscripts submitted to Biomedical journals. Authors should include a statement in the manuscript that informed consent was obtained for experimentation with human subjects. The privacy rights of human subjects must always be observed. All animal experiments should comply with the ARRIVE guidelines and should be carried out in accordance with the UK Animals (Scientific Procedures) Act, 1986 and associated guidelines, EU Directive 2010/63/EU for animal experiments, or the National Institutes of Health guide for the care and use of Laboratory animals (NIH Publications No. 8023, revised 1978) and the authors should clearly indicate in the manuscript that such guidelines have been followed. The Journal will not accept editorial material for commercial purposes.

## Submission of manuscripts

Articles can be sent in Portuguese, Spanish or English. After approved, all papers will be translated to English. *Mastology* publishes the following categories: Editorials, Original Articles, Short Communications, Review Articles, Images in Mastology, Case Reports, Technical Innovations, and Letters to the Editor.

**Original Articles:** Describes experimental research or clinical research – prospective or retrospective, randomized or double blind. They must have 3,000 to 5,000 words, excluding illustrations (tables, figures [maximum of 5]) and references [maximum of 30]. Manuscripts containing original clinical or experimental research results will be prioritized for publication. All manuscripts must present: Title in English, Structured Abstract, Keywords, Abstract, Keywords, Introduction, Methods, Results, Discussion, Conclusions and References.

**Short Communications:** Reports on important new results that fall within the scope of the journal may be submitted as short communications. These papers should not exceed 2,000 words in length and 20 references, and should follow the structure of an original research paper.

**Review Articles:** Systematic critical evaluation of the literature on a given subject, so as to contain a comparative analysis of the works in the area, which discusses the limits and methodological scope, allowing to indicate perspectives of continuity of studies in that line of research and should contain conclusions. The procedures adopted for the review, as well as the search, selection and evaluation strategies of the articles should be described, clarifying the delimitation and limits of the theme. Its maximum length should be 5,000 words and the maximum number of bibliographical references of 60.

The selection of themes is based on planning established by the Editor-in-Chief and Co-Editors. Articles in this category are usually ordered by publishers from authors with proven experience in the field. Spontaneous contributions may be accepted. It must present: Title, Abstract (without need of structuring), Keywords, Text (with or without subtitles), and References. The general instructions for figures, tables and references are the same as for the original articles.

**Images in Mastology:** Unusual images in clinical practice or associated with topics which are considered as rare. The text will be continuous, expressing the rarity or singularity of the case, at maximum of 400 words, and no more than 10 references and 3 figures. They must present: Title, Abstract (non-structured up to 150 words), Keywords, and References.

**Case reports:** They are manuscripts reporting unpublished, highly interesting and well-documented clinical cases from a clinical and laboratorial point of view. The text should express the rarity or singularity of the case, at maximum of 2,000 words, and no more than 20 references and 3 figures. They should observe the structure: Introduction, Case report (with patient description, results of clinical exams, follow-up, diagnosis), Discussion (with similarity data in the literature), and Conclusion. They must present: Abstract (unstructured), Keywords, and up to 20 References.

**Letters to the Editor:** They aim to comment or discuss papers published in the journal or report original research in progress. They will be published at the discretion of the Editors, with the corresponding reply where applicable. They must not exceed 600 words and 5 references.

**Editorials:** Editorials are commissioned by the Editors, commenting on relevant works of the Journal itself, relevant researches or communications from Editors. Authors who wish to contribute an Editorial to the Journal should contact the Editorial Office ([biblioteca@sbmastologia.com.br](mailto:biblioteca@sbmastologia.com.br)) prior to writing and submitting the Editorial.

## Preparation of the Manuscript

### A) Cover sheet

- Title of the article, in Portuguese and English, containing between 10 and 12 words, without articles and prepositions. The Title should be motivating and should give an idea of the objectives and content of work;
- full name of each author, without abbreviations;
- indication of the academic degree and institutional affiliation of each author, separately. If there is more than one institutional affiliation, indicate only the most relevant;
- indication of the Institution where the work was done;
- name, address, fax and e-mail of the corresponding author;
- sources of research assistance, if any;
- declaration of non-existence of conflicts of interest.

### B) Second sheet

**Abstract and Descriptors:** Abstract, in Portuguese and English, with a maximum of 250 words. For The original articles, should be structured (Objective, Methods, Results, Conclusions), highlighting the most significant data of the work. For case reports, revisions or updates and a previous note, the summary should not be structured. Below the abstract, specify at least five and at most ten descriptors (Keywords) that define the subject of the work. The descriptors should be based on the DECS – Descriptors in Health Sciences – available at <http://www.decs.bvs.br>

### C) Text

You should strictly obey the structure for each category of manuscript.

In all manuscript categories, the citation of the authors in the text should be numeric and sequential. Using Arabic numerals in parentheses and envelopes.

The standards to be followed were based on the format proposed by the International Committee of Medical Journal Editors and published in the article Uniform requirements for manuscripts submitted to biomedical journals also available for consultation at <http://www.icmje.org/>.

## Presentation of the text

Preferably use the Microsoft Word® word processor.

Do not emphasize excerpts from the text: do not underline and do not use bold. Do not use capital letters in proper nouns (other than the first letter) in the text or Bibliographical References. When using acronyms or abbreviations, describe them in full the first time they are mentioned in the text.

## Summary

The Summary should contain the relevant information, allowing the reader to get a general idea of the work. All articles submitted must have a summary in Portuguese or Spanish and in English (abstract), between 150 and 250 words. For Original Articles, abstracts should be structured including objectives, methods, results and conclusions. For the other categories, the format of the abstracts may be the narrative, but preferably with the same information. They should not contain quotations and abbreviations. Highlighting at least three and at most six indexing terms, extracted from the vocabulary "Descriptors in Health Sciences" (DeCS – [www.bireme.br](http://www.bireme.br)), when accompanying the abstracts in Portuguese or Spanish, and Medical Subject Heading – MeSH (<http://www.nlm.nih.gov/mesh/>), when they follow the "Abstract". If no descriptors are available to cover the subject of the manuscript, terms or expressions of known use may be indicated.

## Introduction

In this section, show the current state of knowledge about the topic under study, divergences and gaps that may possibly justify the development of the work, but without extensive review of the literature. For Case Reports, present a summary of the cases already published, epidemiology of the reported condition and a justification for the presentation as an isolated case. Clearly state the objectives of the work.

## Methods

Start this section indicating the work planning: whether prospective or retrospective; Clinical or experimental trial; Whether the distribution of cases was random or not, and

so on. Describe the criteria for selection of patients or experimental group, including controls. Identify the equipment and reagents used. If the applied methodology has already been used, give the references in addition to the brief description of the method. Also describe the statistical methods employed and the comparisons for which each test was used. In the Case Reports, the sections Material and Methods and Results are replaced by the description of the case, remaining the remaining cases.

## Results

It should be limited to describing the results found without including interpretations and comparisons. Present the results in logical sequence, with text, tables and figures.

## Discussion

It should properly and objectively explore the results, discussed in light of other observations already recorded in the literature, highlighting the new and original information obtained in the research. Emphasize the appropriateness of the research methods used. Compare and relate the observations with those of other authors, commenting and explaining the differences that occur. Explain the implications of the findings, their limitations, and make recommendations. The discussion should culminate with the conclusions, indicating ways for new research or implications for professional practice. For Case Reports, base the Discussion on a broad and updated literature review.

## Thanks

Collaborations of individuals, institutions or acknowledgments for financial support, technical aids, deserving recognition, but not justifying inclusion as the author, should be included.

## References

References should be listed at the end of the article, numbered consecutively, following the order in which they were first mentioned in the text, based on the Vancouver style (see: "Uniform Requirements for Manuscripts Submitted to Biomedical Journals: Writing and Editing for Medical Publication" [[http://www.nlm.nih.gov/bsd/uni-form\\_requirements.html](http://www.nlm.nih.gov/bsd/uni-form_requirements.html)]). All authors and works cited in the text should be included in this section and vice versa. Articles accepted for publication may be cited accompanied by the expression: accepted and awaiting publication, or "in press" indicating the periodical, volume and year.

For all references, cite all authors up to six. When in greater numbers, cite the first six authors followed by the expression et al. Examples:

### Articles of Journals or Magazines

Del Giglio A, Pinhal MA. Genetic profile in breast cancer: a brief review for the mastologist. *Rev Bras Mastologia*. 2005; 15 (1): 45-50.

### My Account

Montoro AF. *Mastology*. São Paulo: Sarvier, 1984.

### Book Chapters

Cunningham FG, Leveno KJ, Bloom SL, Hauth JC, Gilstrap III LC, Wenstrom KD. *Williams Obstetrics*. 22nd ed. New York: McGraw-Hill; 2005. Chapter 39, Multifetal gestation. P 911-43.

### With authorship

Von Hoff DD, Hanauske AR. Preclinical and early clinical development of new anti-cancer agents. In: Kufe DW, Bast RC Jr, Hait WN, Hong WK, Pollock RE, Weichselbaum RR, et al. Editors. *Holland-Frei cancer medicine*. 7th ed. Hamilton (ON): BC Decker Inc.; 2006. p. 600-16.

### Theses and Dissertations

Steinmacher DI. Evaluation of percutaneous needle biopsy with automatic propellant in the proapeutics of palpable and nonpalpable lesions of the breast [dissertation]. São Paulo: Federal University of São Paulo. Paulista School of Medicine; 2005.

## Electronic publications

Henrique MA, Cosiski MHR. Mammographic density as a risk factor for breast cancer. *Rev Bras Ginecol Obstet* [Internet]. 2007 [cited 2008 Feb 27]; 29 (10): 493-6.

## Tables and Figures

The presentation of this material should be in black and white, on separate sheets, with captions and respective numbers printed next to each illustration. The name of the manuscript and authors must be noted on the back of each figure and table. All tables and figures should also be sent in digital files, preferably in Microsoft Word® files and the rest in Microsoft Excel®, Tiff or JPG files. The quantities, units and symbols used in the tables must comply with the national nomenclature. Surgery and biopsy photographs where colorations and special techniques were used will be considered for color printing and the authors will be responsible for the additional cost.

**Captions:** Print the captions using double space, accompanying the respective figures (graphics, photographs and illustrations) and tables. Each caption should be numbered in Arabic numerals, corresponding to its citations in the text.

**Abbreviations and Acronyms:** They must be preceded by the full name when first mentioned in the text. In tables, figures should be to contain their meaning below the table.

If the illustrations have already been published, they must be accompanied by written authorization from the author or publisher, with the reference source where it was published.

The text entered in the program "Word for Windows, with double space, with letters of size that makes reading easier (we recommend those of No. 14). It must be submitted electronically through the address: [revistabrasileirademastologia@gmail.com](mailto:revistabrasileirademastologia@gmail.com)

The Brazilian Journal of Mastology reserves the right not to accept for evaluation the articles that do not fulfill the criteria formulated above.

## Submission of the manuscript

The manuscript must be accompanied by a letter signed by all the authors, authorizing its publication, stating that it is unpublished and that it was not, or is being submitted for publication in another periodical.

All persons designated as authors must respond for the authorship of the manuscript and have participated sufficiently in the work to assume public responsibility for its content. Authorship credit should be based only on substantial contributions during: (1) designing, planning, executing, analyzing and interpreting the results, (2) writing or reviewing the manuscript in an intellectually important way, and (3) Be published. Editors may request justification for inclusion of authors during the review process, especially if the total number of authors exceeds six.

### They should be sent

- Declaration of Conflict of Interests, as relevant, The Declaration of Conflict of Interests, according to Resolution of the Federal Council of Medicine in 1595/2000, prohibits that in a scientific article is made promotion or advertisement of any commercial products or equipment.
- Certificate of Work Approval by the Research Ethics Committee Institution in which it was performed.
- Information on possible sources of research funding.
- Article dealing with clinical research with humans should include a statement that the Participants signed an Informed Consent Form.

The works must be submitted through the electronic address:

<http://www.rbmastologia.com.br/>

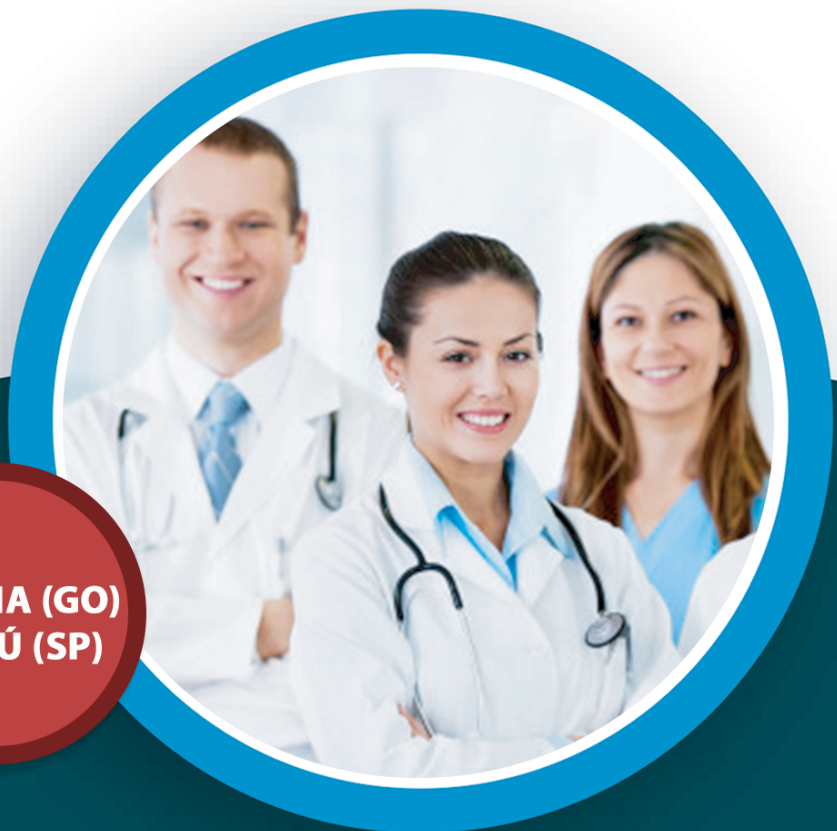# CURSO DE ONCOPLASTIA E RECONSTRUÇÃO MAMÁRIA 2020

EDUCAÇÃO CONTINUADA TEÓRICO-PRÁTICA DA SBM



60  
anos

- ✓ Curso teórico e prático com realização de cirurgias
- ✓ Técnicas cirúrgicas inovadoras
- ✓ Professores renomados nacionais e internacionais



**GOIÂNIA (GO)  
OU JAÚ (SP)**

**12 VAGAS PARA CADA CURSO**

## COORDENAÇÃO:

### GOIÂNIA (GO):

Dr. Régis Resende Paulinelli  
Dr. Luiz Fernando Jube Ribeiro

### JAÚ (SP):

Dr. Maurício de Aquino Resende  
Dr. João Ricardo Auler Paloschi  
Dr. Ailton Joioso

Duração: 11 módulos

De Janeiro a Dezembro/2020

Investimento: 11x de R\$5.000,00

## INSCRIÇÕES:

01/10 a 29/11/2019

## MAIS INFORMAÇÕES:

(21)2220-7711

[oncoplastia2020@sbmastologia.com.br](mailto:oncoplastia2020@sbmastologia.com.br)

Interessados devem enviar currículo lattes até o dia 29/11/2019 para o e-mail acima informando a unidade que deseja fazer o curso: Goiânia/GO ou Jaú/SP

